65. Saleh M, Gauthier AS, Delbosc B, Castelbou M. Impact of metamorphopsia on quality of life after successful retinal detachment surgery. *Ophthalmologica*. 2018;240:121−128.
66. Gupta RR, Iaboni DSM, Seamone ME, Sarraf D. Inner, outer, and full-thickness retinal folds after rhegmatogenous retinal detachment repair: a review. *Surv Ophthalmol*. 2019;64:135−161.
67. Abouzeid H, Wolfensberger TJ. Macular recovery after retinal detachment. *Acta Ophthalmol Scand*. 2006;84:597−605.
68. Peiretti E, Nasini F, Buschini E, et al. Optical coherence tomography evaluation of patients with macula-off retinal detachment after different postoperative posturing: a randomized pilot study. *Acta Ophthalmol*. 2017;95:e379−e384.
69. Pournaras C, Tsika C, Brozou C, Tsilimbaris MK. Surgical and visual outcome for recurrent retinal detachment surgery. *J Ophthalmol*. 2014;2014:810609.
70. Echegaray JJ, Vanner EA, Zhang L, et al. Outcomes of pars plana vitrectomy alone versus combined scleral buckling plus pars plana vitrectomy for primary retinal detachment. *Ophthalmol Retina*. 2021;5:169−175.
71. Yaqoob Z, Wu J, Yang C. Spectral domain optical coherence tomography: a better OCT imaging strategy. *Biotechniques*. 2005;39(6 suppl):S6−S13.
72. Geissbühler M, Hincapié CA, Aghlmandi S, et al. Most published meta-regression analyses based on aggregate data suffer from methodological pitfalls: a meta-epidemiological study. *BMC Med Res Methodol*. 2021;21:123.

Pictures & Perspectives

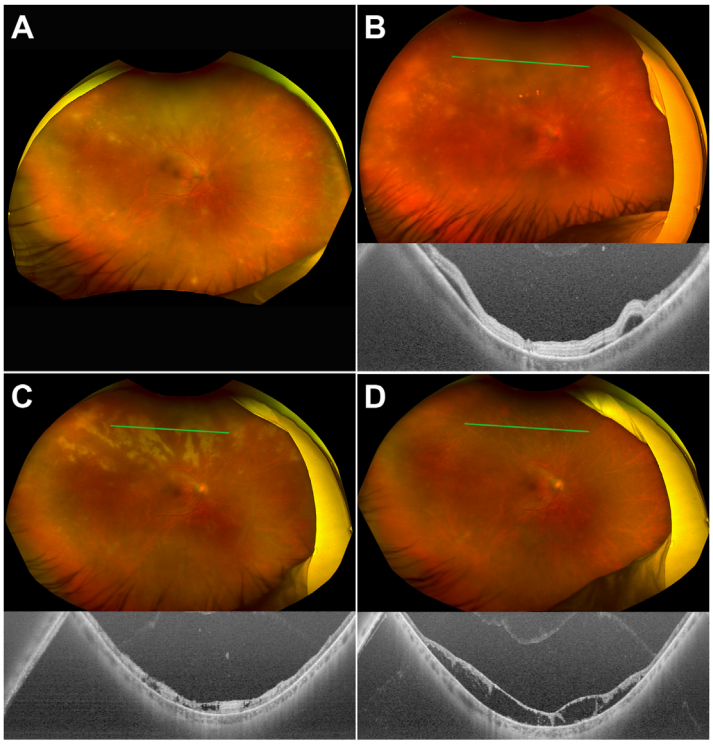

Ultrawide-field OCT for Acute Retinal Necrosis

A 58-year-old woman complained of blurred vision. Ultrawide-field image with Silverstone (Optos Inc) of the right eye at the first visit revealed multiple whitish-yellow patchy lesions, exhibiting moderate vitritis and vasculitis (**A**). Acute retinal necrosis was clinically diagnosed. Subsequently, real-time polymerase chain reaction detected varicella zoster virus (9.3×10^6 copies/ml). Ultrawide-field OCT around far periphery of the retina (green line) detected subretinal fluid even in early foci of retinitis (**B**). Retinal necrosis gradually progressed despite intensive antiviral therapy and systemic steroids (**C**), resulting in focal retinal detachment (**D**). (Magnified version of Figure **A-D** is available online at www.ophthalmologyretina.org).

Shunichi Fukuyama, MD[1]
Noriyasu Hashida, MD, PhD[1,2]
Kohji Nishida, MD, PhD[1,2]

[1]*Department of Ophthalmology, Osaka University Graduate School of Medicine, Osaka, Japan;* [2]*Integrated Frontier Research for Medical Science Division, Institute for Open and Transdisciplinary Research Initiatives, Osaka University Graduate School of Medicine, Osaka, Japan*