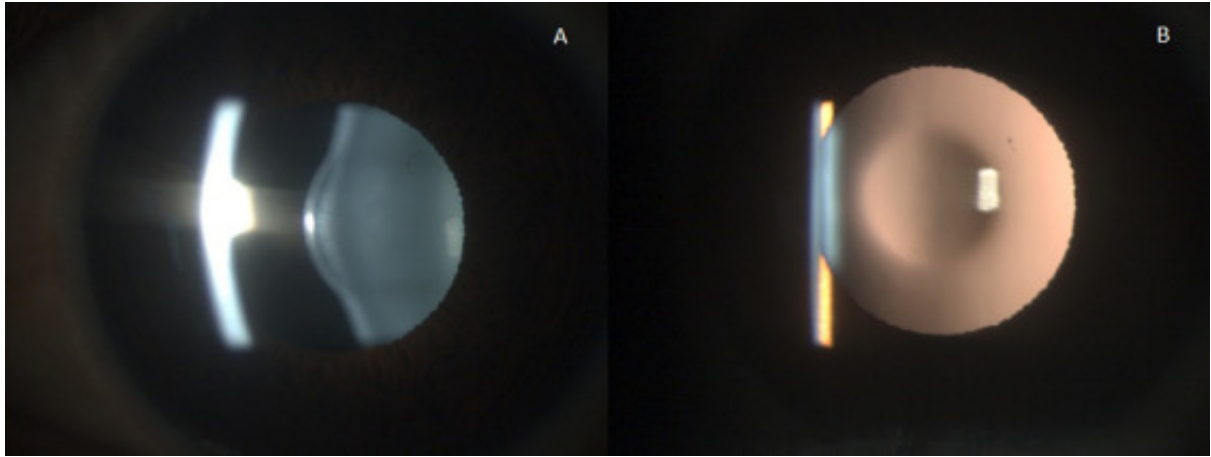


Rare case of anterior lenticonus



A 17-year-old girl presented with defective vision in both eyes. On ocular examination, she showed anterior lenticonus in both eyes with normal fundus and an “oil droplet reflex” on retroillumination (Fig. A, B).

Lenticonus is characterized by conical protrusion of the anterior or posterior lens surface. Posterior lenticonus is more common than anterior and is usually unilateral. Anterior lenticonus is often bilateral and is usually associated with Alport syndrome. Alport syndrome results in renal failure, which can be avoided by early diagnosis and prompt referral.

The authors have no proprietary or commercial interest in any materials discussed in this article.