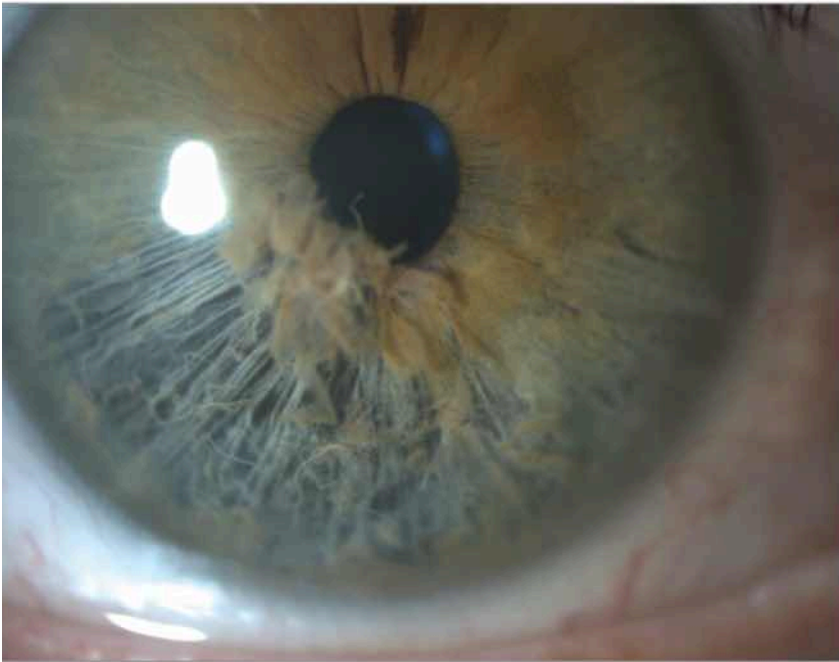


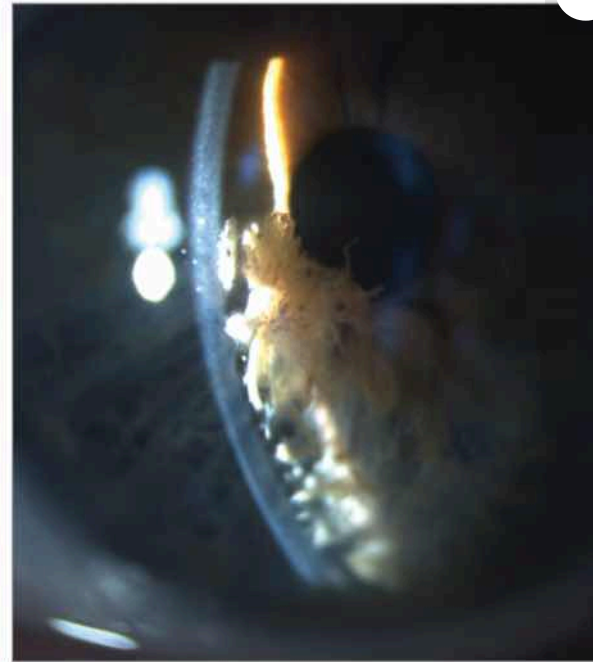Follow-Up of Bilateral Iridoschisis in a Patient With Alport Syndrome

Benjamin Matagrín, PhD¹; Emilie Agard, MD¹; Corinne Dot, MD, PhD¹

Slitlamp photograph, 2016



B Slitlamp photograph, 2022



February 15, 2024

JAMA Ophthalmol. 2024;142(2):e234735.

doi:10.1001/jamaophthalmol.2023.4735

[Full Text](#)

Since 2009, we have been following up a patient with bilateral and symmetric iridoschisis. This patient has Alport syndrome, with sensorineural hearing loss and kidney insufficiency but no other significant ophthalmologic history. Iridoschisis is a rare condition in which the anterior layer of the iris stroma progressively detaches from the posterior stroma leaving the pigmented epithelium and the iris muscles intact (Figure, A).

[Full Text](#)

