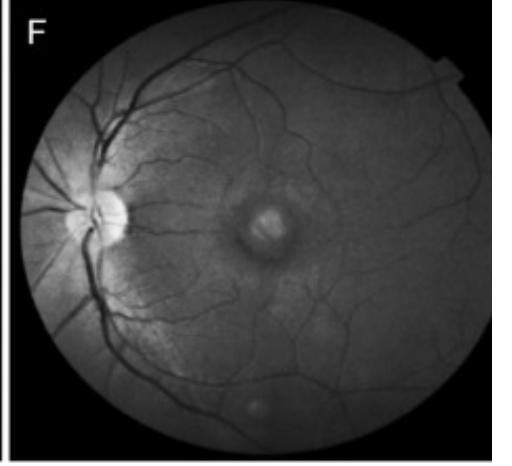
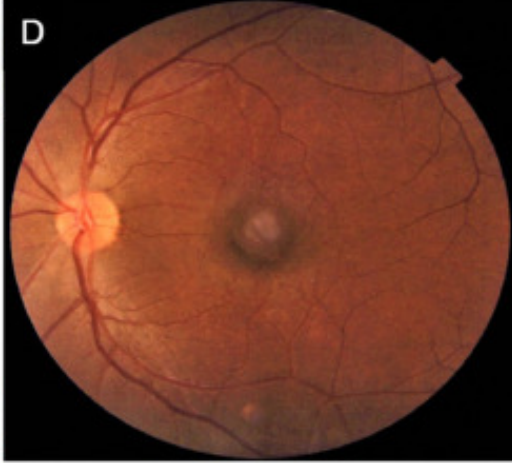
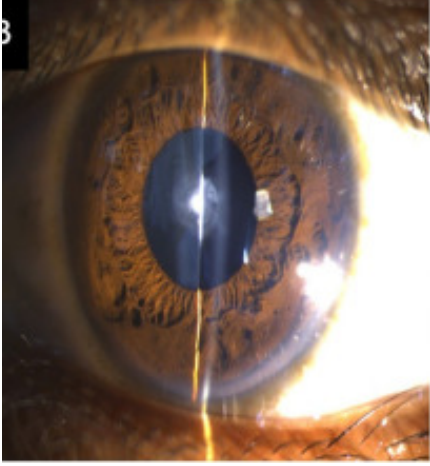
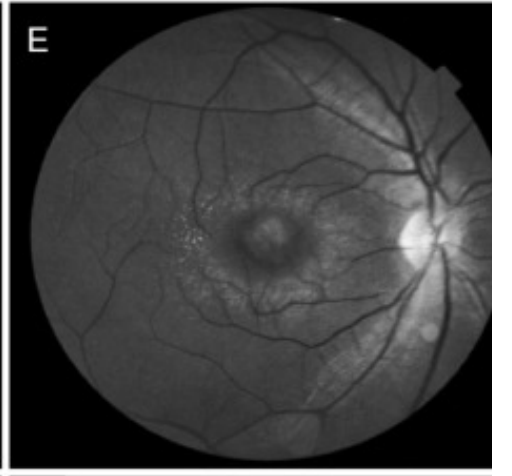
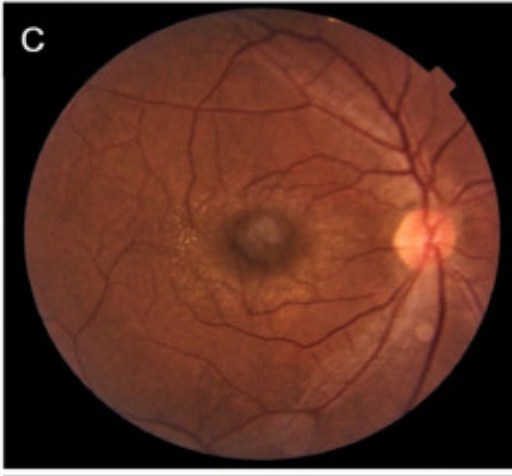
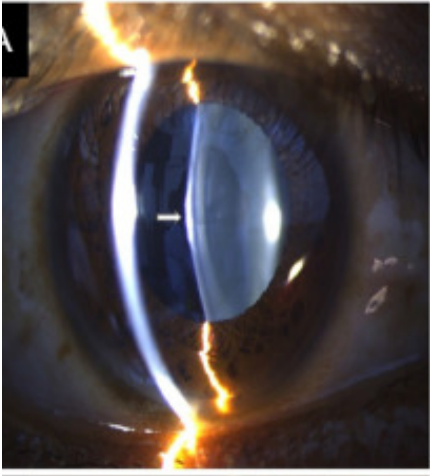
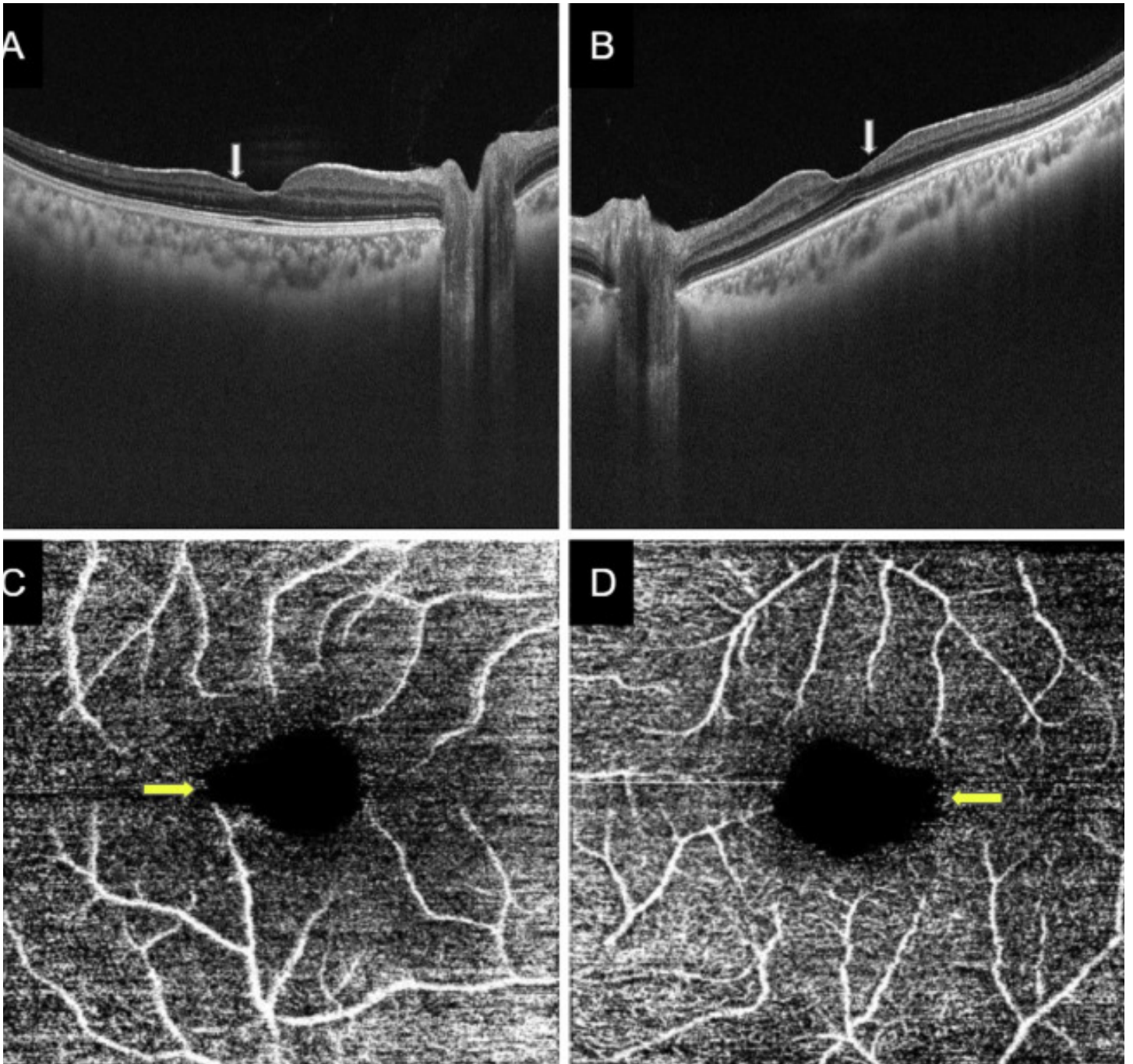


# Role of multimodal ocular imaging in Alport syndrome

Search for articles by this author

A 19-year-old man with Alport syndrome presented with diminution of vision in his left eye. Slit-lamp biomicroscopy showed an early anterior lenticonus with an anterior subcapsular cataract in his right eye (Fig. 1A) and a dense anterior polar and anterior subcapsular cataract in his left eye (Fig. 1B). Fundus photography revealed central perimacular dot-and-fleck retinopathy with a dull macular reflex or lozenge in both eyes (Fig. 1C, 1D). The flecks were better visualized on red-free imaging as a ring of fine white stippling around the macula (Fig. 1E, 1F). Bilateral temporal retinal thinning was present on optical coherence tomography (Fig. 2A, 2B) with distortion and temporal enlargement of the foveal avascular zone of the superficial retinal plexus on optical coherence tomography angiography (Fig. 2C, 2D). Ophthalmic imaging can provide a rapid, noninvasive, and relatively inexpensive tool for diagnosis of Alport syndrome and also can help predict progression of renal disease and mode of inheritance in certain situations.





To read this article in full you will need to make a payment

## Article info

### Publication history

Published online: July 26, 2021

### Identification

DOI: <https://doi.org/10.1016/j.jcjo.2021.06.018>

### Copyright

© 2021 Canadian Ophthalmological Society. Published by Elsevier Inc. All rights reserved.

## **ScienceDirect**

[Access this article on ScienceDirect](#)

## **Related Articles**