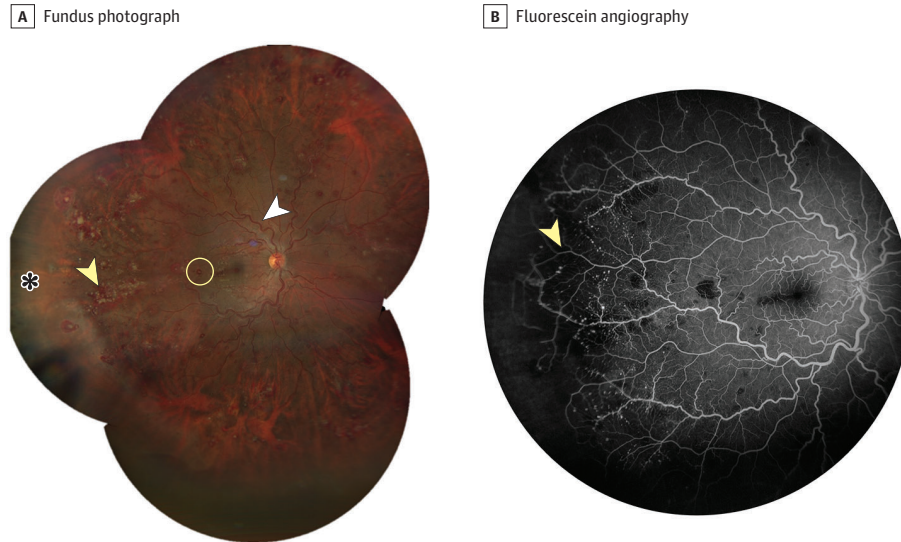


## JAMA Ophthalmology Clinical Challenge

## Bilateral Retinal Vascular Tortuosity and Hemorrhages

Enrico Borrelli, MD, PhD; Sonia Serafino, MD; Michele Reibaldi, MD, PhD



**Figure.** A, In the right eye, fundus photography revealed dilated and tortuous veins (white arrowhead) along with white-centered retinal hemorrhages, specifically Roth spots (circle). Additionally, white agglomerates (yellow arrowhead) and ischemic areas (asterisk) were observed in the peripheral retina. B, Fluorescein angiography revealed peripheral retinal vasculopathy characterized by microaneurysms and retinal capillary nonperfusion (arrowhead).

**A 28-year-old man** was referred to the medical retina service for evaluation of bilateral retinal vasculopathy noted by his general ophthalmologist. Medical and family histories were unremarkable, and there was no record of prolonged medication use. The patient reported a decrease in visual acuity in his right eye for the past 2 weeks but did not express any systemic symptoms, such as fever, increased heart rate, or fatigue. His best-corrected visual acuity was 20/25 OD and 20/20 OS. The pupils were round and responsive, and there were no notable abnormalities in the anterior segment. Fundus examination confirmed the presence of dilated and tortuous veins, along with white-centered retinal hemorrhages (ie, Roth spots) (Figure, A). Furthermore, the retinal periphery exhibited white intraretinal agglomerates and nonperfused areas. Fluorescein angiography demonstrated peripheral retinal vasculopathy with microaneurysms and retinal capillary nonperfusion (Figure, B).

## WHAT WOULD YOU DO NEXT?

- A. Indocyanine green angiography to rule out choroiditis
- B. Echocardiography to rule out infective endocarditis
- C. Blood testing to rule out hemato-oncologic disorders
- D. Ocular ultrasonography to rule out the presence of an intraocular tumor

[+ CME Quiz at jamacmelookup.com](https://jamacmelookup.com)

## Diagnosis

### Chronic myeloid leukemia

## What to Do Next

### C. Blood testing to rule out hemato-oncologic disorders

## Discussion

Chronic myeloid leukemia (CML), a myeloproliferative neoplasm occurring in 1 to 2 cases per 100 000 adults, constitutes 15% of newly diagnosed adult leukemia cases.<sup>1</sup> A key factor in developing CML is fusion of the Abelson murine leukemia (*ABL1*) gene on chromosome 9 with the breakpoint cluster region (*BCR*) gene on chromosome 22.<sup>1</sup> This fusion results in production of an oncoprotein—BCR-ABL1, a continuously active tyrosine kinase.<sup>2</sup> This active kinase promotes the growth and survival of CML cells.

Approximately 50% of individuals diagnosed with CML are asymptomatic.<sup>3</sup> Ophthalmic manifestations have been documented in 7.7% of individuals diagnosed with CML, with visual impairment present in 4% of individuals when initially diagnosed.<sup>3</sup> Ophthalmic manifestations associated with CML may result from direct infiltration of CML cells or from blood hyperviscosity.

Roth spots, ie, white-centered retinal hemorrhages, may manifest in various medical conditions, including leukemia, anemia, hypertensive retinopathy, preeclampsia, diabetic retinopathy, and anoxia, and are noted in 2% of patients with endocarditis.<sup>4,5</sup> These spots can be attributed to various pathological factors, including inflammatory infiltrate, infectious organisms, presence of fibrin or platelets, or accumulation of neoplastic cells.<sup>6</sup> Roth spots in CML may arise from direct infiltration of CML cells or blood hyperviscosity, with the latter leading to retinal capillary rupture and extravasation of blood into the retina.

Blood hyperviscosity secondary to hyperleukocytosis may cause microvascular obstruction. When this occurs in the retina, various signs can be observed, such as different types of retinal hemorrhages, including Roth spots, retinal venous tortuosity, peripheral microaneurysms, or retinal capillary nonperfusion. Furthermore, as observed in this case, disruption of retinal capillaries may lead to extravasation of blood cells and molecules, which contribute to accumulation of agglomerates.

For these reasons, when a patient presents with Roth spots associated with other retinal vascular changes secondary to blood hyperviscosity, hemato-oncologic diseases should be considered. A physical examination should be performed to detect other pathologic signs associated with leukocytosis. However, findings of this examination may be unrevealing, as CML can be asymptomatic. A blood test should be conducted to evaluate white blood cell count. The presence of ophthalmic manifestations in patients with CML may be associated with a worse prognosis, as evidenced by a lower survival rate among patients with CML exhibiting such manifestations.<sup>7</sup> Therefore, prompt recognition of the underlying disease is vital to initiate prompt treatment, which is typically associated with an improvement in systemic signs and symptoms, including ocular manifestations.<sup>8</sup> Typical recommendations for ophthalmic follow-up in patients with CML may be as often as monthly for the initial 6 to 12 months following diagnosis.

Performing indocyanine green angiography to rule out choroiditis (choice A) is not the preferred answer, because bilateral hemorrhages with vessel tortuosity are an uncommon presentation for choroiditis, especially in a patient without fluorescein angiography signs of choroidal inflammation. Echocardiography to rule out the presence of infective endocarditis (choice B) is not recommended as the next step, because this disease is not typically associated with retinal signs of hyperviscosity, such as vessel tortuosity, microaneurysms, peripheral retinal capillary nonperfusion, and intraretinal agglomerates. Performing an ocular ultrasound to rule out the presence of an intraocular tumor (choice D) is not the next step, as fundus presentation is uncommon in these cases, and there was no evidence of an intraocular tumor apparent upon fundus examination.

## Patient Outcome

The patient received comprehensive information about their condition and prognosis. Hematologic counseling was advised for the patient's care. The patient initiated systemic treatment with asciminib, and subsequent regular follow-up revealed improvement in visual acuity and ophthalmic signs.

## ARTICLE INFORMATION

**Author Affiliations:** Department of Surgical Sciences, University of Turin, Turin, Italy (Borrelli, Serafino, Reibaldi); Department of Ophthalmology, City of Health and Science Hospital, Turin, Italy (Borrelli, Serafino, Reibaldi).

**Corresponding Author:** Enrico Borrelli, MD, PhD, Division of Ophthalmology, Department of Surgical Sciences, University of Turin, Via Cherasco 23, Turin 10126, Italy ([borrelli.enrico@yahoo.com](mailto:borrelli.enrico@yahoo.com)).

**Published Online:** June 6, 2024.  
doi:10.1001/jamaophthalmol.2024.1696

**Conflict of Interest Disclosures:** Dr Borrelli reported personal fees from Bayer, Hoffmann La Roche, AbbVie, and Zeiss. No other disclosures were reported.

**Additional Contributions:** We thank the patient for granting permission to publish this information.

## REFERENCES

- Jabbour E, Kantarjian H. Chronic myeloid leukemia: 2022 update on diagnosis, therapy, and monitoring. *Am J Hematol*. 2022;97(9):1236-1256. doi:10.1002/ajh.26642
- Rowley JD. Letter: a new consistent chromosomal abnormality in chronic myelogenous leukaemia identified by quinacrine fluorescence and Giemsa staining. *Nature*. 1973;243(5405):290-293. doi:10.1038/243290a0
- Reddy SC, Jackson N, Menon BS. Ocular involvement in leukemia—a study of 288 cases. *Ophthalmologica*. 2003;217(6):441-445. doi:10.1159/000073077
- Loughrey PB, Armstrong D, Lockhart CJ. Classical eye signs in bacterial endocarditis. *QJM*. 2015;108(11):909-910. doi:10.1093/qjmed/hcv055
- Cogan DG. Ophthalmic manifestations of systemic vascular disease. *Major Probl Intern Med*. 1974;3(0):1-187.
- Kaur B, Taylor D. Fundus hemorrhages in infancy. *Surv Ophthalmol*. 1992;37(1):1-17. doi:10.1016/0039-6257(92)90002-B
- Ohkoshi K, Tsiaras WG. Prognostic importance of ophthalmic manifestations in childhood leukaemia. *Br J Ophthalmol*. 1992;76(11):651-655. doi:10.1136/bjo.76.11.651
- Réa D, Boquimpani C, Mauro MJ, et al. Health-related quality of life of patients with resistant/intolerant chronic phase chronic myeloid leukemia treated with asciminib or bosutinib in the phase 3 ASCEMBL trial. *Leukemia*. 2023;37(5):1060-1067. doi:10.1038/s41375-023-01888-y