Bilateral Idiopathic Multifocal Retinal Pigment Epithelial Detachments

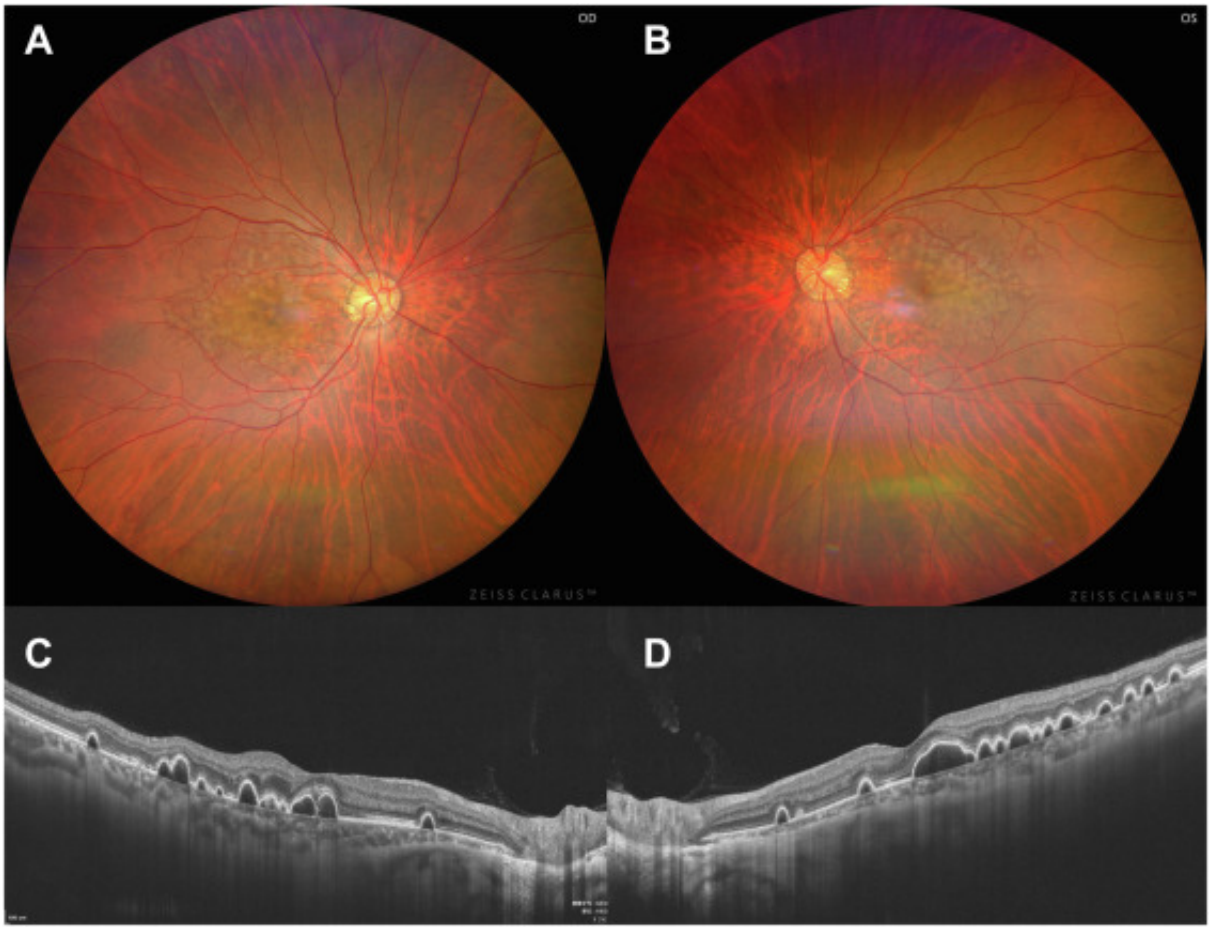

A 43-year-old man who experienced metamorphopsia in both eyes was initially diagnosed with central serous chorioretinopathy. No response was noticed after oral Aescuven Forte for 1 month. Best-corrected visual acuity was 20/20 in both eyes. Clusters of translucent blister-like round lesions were seen in the macular area (**A**, **B**). Swept-source OCT showed the lesions were serous pigment epithelial detachment (**C**, **D**). No abnormality was found in systemic or laboratory examinations. The diagnosis was corrected to bilateral idiopathic multifocal retinal pigment epithelial detachments, a rare condition in which no intervention is required. The lesions remained unchanged over a 2-year follow-up. (Magnified version of Figure **A**-**D** is available online at www.ophthalmologyretina.org).