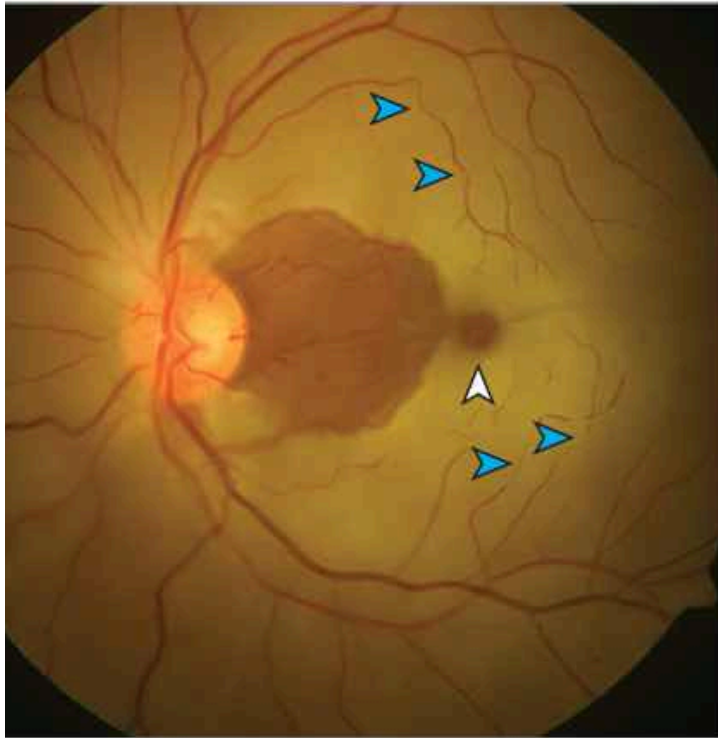


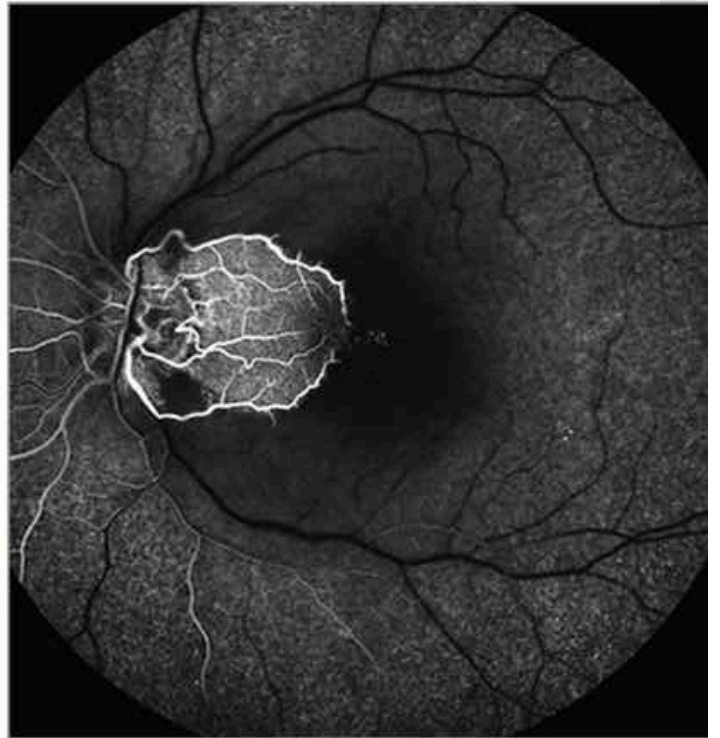Central Retinal Artery Occlusion With Cilioretinal Artery Sparing

Nitin Menia, MD1; Arun Kapil, BSc1; Reema Bansal, MD, PhD1

Fundus photograph, left eye



Fundus fluorescein angiography, left eye



[JAMA Ophthalmology](#)

2024 American Medical Association. All Rights Reserved

Search All

- Search All
- JAMA
- JAMA Network Open
- JAMA Cardiology
- JAMA Dermatology
- JAMA Forum Archive

- JAMA Health Forum
- JAMA Internal Medicine
- JAMA Neurology
- JAMA Oncology
- JAMA Ophthalmology
- JAMA Otolaryngology–Head & Neck Surgery
- JAMA Pediatrics
- JAMA Psychiatry
- JAMA Surgery
- Archives of Neurology & Psychiatry

elias kp

Access through your institution

[Sign In](#)

February 15, 2024

JAMA Ophthalmol. 2024;142(2):e234731.

doi:10.1001/jamaophthalmol.2023.4731

[Full Text](#)

A patient in their early 30s presented with decreased vision in the left eye (6/60) for 1 week and a relative afferent pupillary defect. Fundus examination revealed “box carrying” of the retinal vessels, a cherry-red spot, retinal opacification, and a small island of normal retina temporal to the optic disc ([Figure, A](#)). An embolus was not visualized within the central retinal artery.

[Full Text](#)

