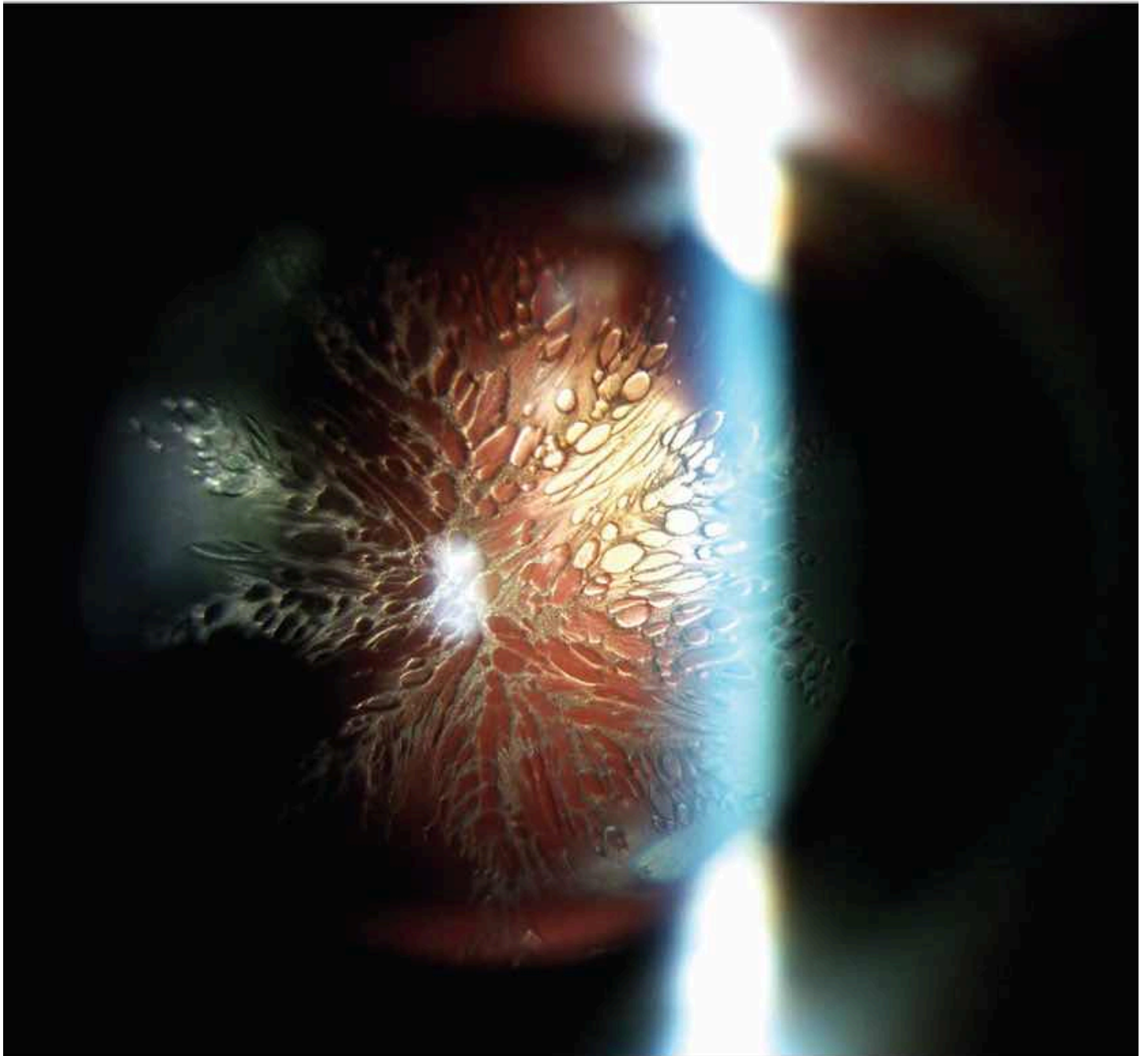


Evanescent Snowflake Cataract After Pars Plana Vitrectomy

Júlio Almeida, MD1; Mário Ramalho, MD1; Isabel Prieto, MD1



A 51-year-old male patient presented with a blurred shadow in his left nasal visual field for 4 days. Fundus examination revealed a temporal retinal detachment without macular involvement. The patient underwent an

uncomplicated 23-gauge pars plana vitrectomy, air-fluid exchange, endolaser, and sulfur hexafluoride gas tamponade. Immediate postoperative positioning in the prone position was advised, and the patient denied any supine positioning after surgery. On postoperative day 1, uncorrected visual acuity was hand motions OS, and the examination revealed a new-onset posterior subcapsular cataract, with a feathery pattern (Figure). On postoperative day 7, his corrected visual acuity improved to 20/50 OS, the cataract had resolved, the retina was flat, and the gas bubble had decreased to less than half size. One year after surgery, his lens remains clear, and his best-corrected visual acuity is 20/25 OS.