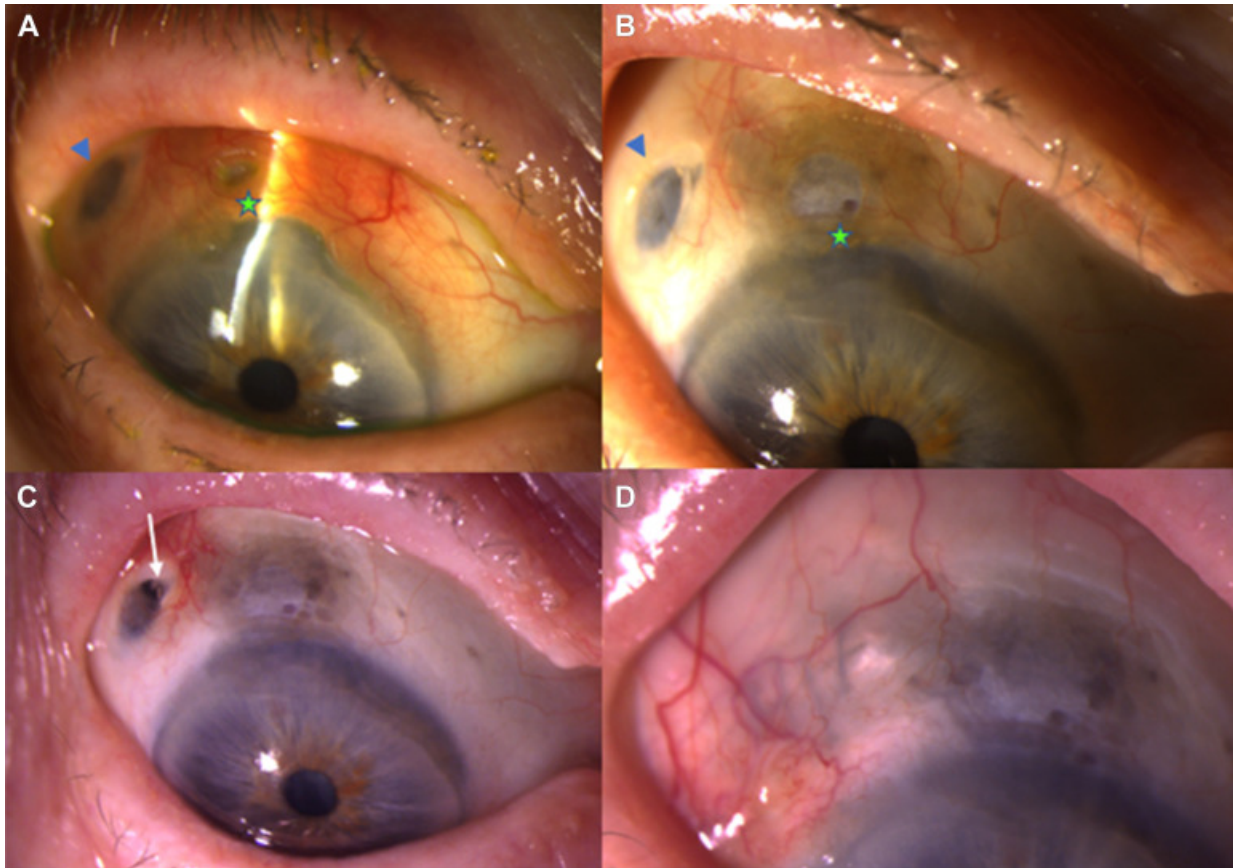


Corneoscleral Melt After Implantation of a Ranibizumab Port Delivery System



A 91-year-old woman with neovascular age-related macular degeneration presented with worsening right eye redness and irritation 4 months after implantation of a ranibizumab port delivery system. Corneoscleral thinning and conjunctival injection (**A**, green star) was noted adjacent to the implant (**A**, blue arrowhead). Laboratory workup showed positive perinuclear antineutrophil cytoplasmic antibodies with negative workup for other causes of vasculitis. The patient was administered oral and topical steroids with improvement in conjunctival injection, but (**B**) the corneoscleral and conjunctival

thinning progressed, resulting in erosion of the implant (**C**, white arrow) and subsequent removal. (**D**) At 3 months postoperatively, the corneoscleral thinning remained stable after discontinuation of oral steroids. (Magnified version of Figure **A-D** is available online at www.aajournal.org).