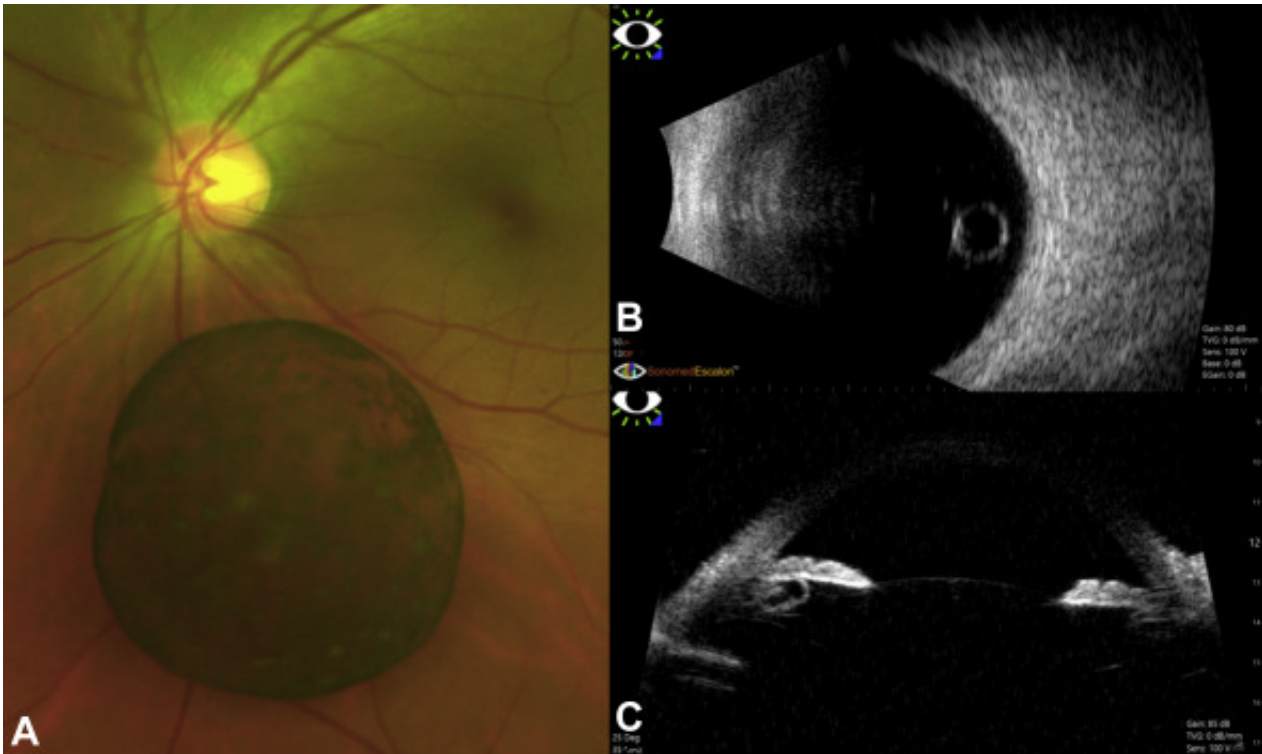


# Free-Floating Pigmented Intravitreal Cyst—Where Did It Come From?



A 43-year-old man reported floaters in his left eye for the 1 year's duration. On examination, visual acuity was 20/20 in both eyes. Anterior segment examination revealed no abnormality. Fundus examination of the left eye revealed a single, spherical, translucent, free-floating pigmented cyst in the vitreous cavity measuring nearly 4 disc diameters (**A**). Ultrasonography revealed a free-floating cyst with no internal hyperechogenicity (**B**). Ultrasound biomicroscopy of the left eye showed a temporal, well-defined, clear ciliary body cyst measuring 0.9 × 0.7 mm (**C**). A ciliary body cyst may be the origin of the pigmented vitreous cyst in this patient.

## Article info

## Copyright

© 2020 by the American Academy of Ophthalmology