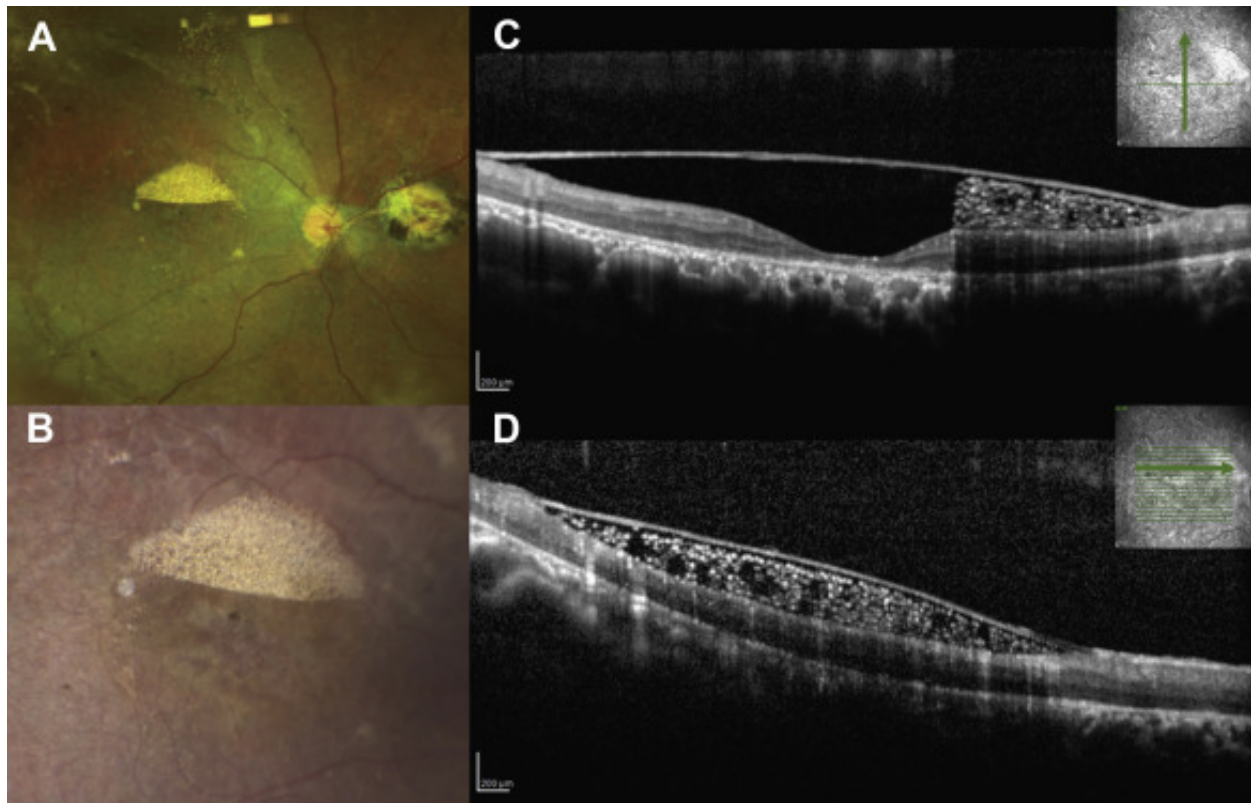


# Inverse Pseudohypopyon from Emulsified Silicone Oil in the Macula



A 16-year-old boy with a history of Stickler syndrome sought treatment to establish care. He had a remote history of bilateral rhegmatogenous retinal detachments that had been repaired surgically elsewhere. Examination of both eyes was significant for silicone oil droplets in the macula in an inverse pseudohypopyon pattern, which was more severe in the right eye (**A, B**). Spectral-domain OCT of the superior macula in the right eye demonstrated an epiretinal membrane with underlying hyperreflective material associated with optical shadowing (**C, D**). Manifestations of silicone oil emulsification can include preretinal accumulation in the posterior pole.