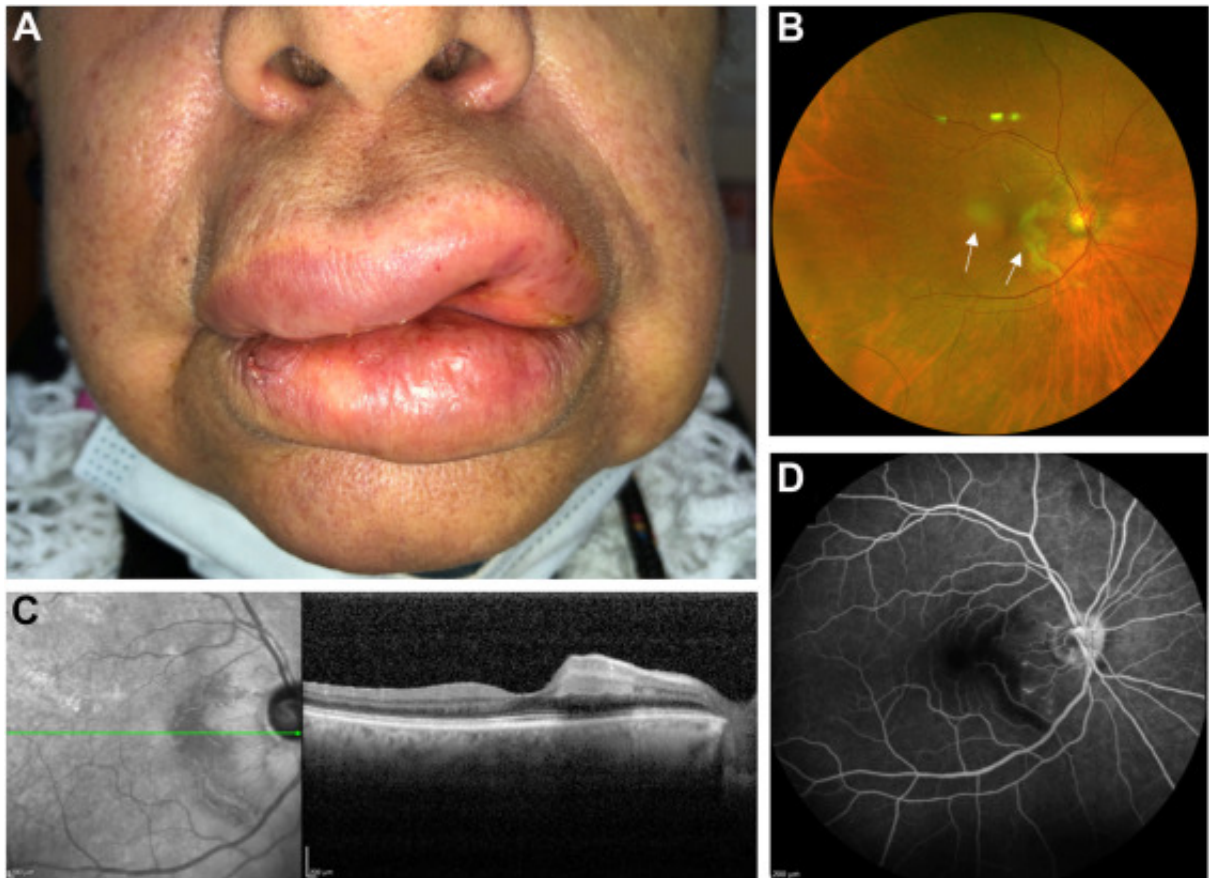


# Retinal Artery Occlusion After Self-Injected Petroleum Jelly Lip Filler



A 67-year-old woman presented with unilateral vision loss after using a 25-gauge hypodermic needle to self-inject 5 cc of microwaved petroleum jelly into her upper lip (**A**) for cosmetic augmentation. She had similarly injected her lower lip years prior without ophthalmic sequelae. The patient experienced ocular pain immediately postinjection and awoke with right eye blurriness (20/40) the next day. Examination revealed macular whitening consistent with retinal artery occlusion (**B**, arrows). OCT showed inner retinal hyperreflectivity and thickening of the nasal macula (**C**). Fluorescein angiography confirmed retinal and choroidal nonperfusion (**D**) from embolic infarction. Occlusion of the ophthalmic artery and its distal branches is a rare complication of facial dermal fillers resulting from retrograde flow. (Magnified version of Figure **A-D** is available online at [www.opthalmologyretina.org](http://www.opthalmologyretina.org)).