



Search for...

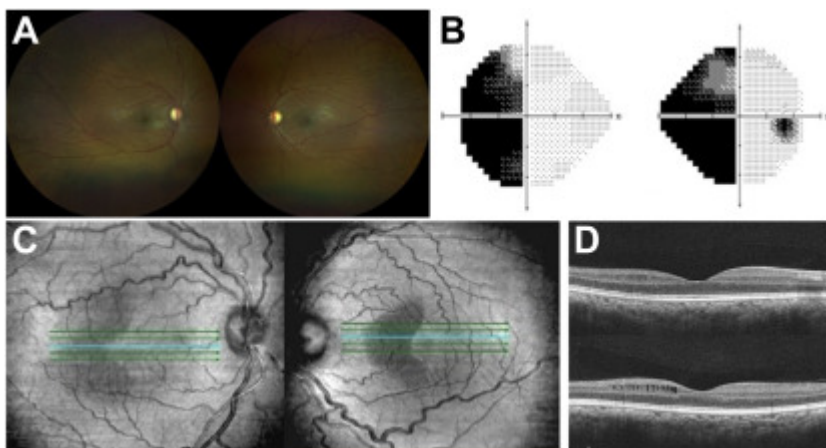
PICTURES & PERSPECTIVES | [ARTICLES IN PRESS](#)

# Retinal Pseudocysts in a Patient with Homonymous Hemianopia

Jonathan Thomas Caranfa, MD, PharmD • Laurel N. Vuong, MD • Michelle C. Liang, MD

Published: June 16, 2023 • DOI: <https://doi.org/10.1016/j.ophtha.2023.05.029> PlumX Metrics

A 33-year-old woman presented for evaluation with a history of craniopharyngioma, status postresection in childhood. Fundoscopic examination showed bilateral optic nerve pallor (**A**) and Humphrey Visual Field 24-2 revealed a left homonymous hemianopia (**B**). Spectral domain en-face OCT imaging demonstrated hemi-macular hyporefectivity respecting the vertical mid-line (**C**). Structural B-scan showed retinal pseudocysts temporally in the right eye (**D**, top) and nasally in the left eye (**D**, bottom), corresponding with the left homonymous defect. Retinal pseudocysts have been described in cases of advanced optic atrophy. This is a rare case of retinal pseudocysts in the setting of homonymous visual field loss secondary to a compressive lesion. (Magnified version of Figure **A-D** is available online at [www.aajournal.org](http://www.aajournal.org)).



## Article info

### Publication history

Published online: June 16, 2023

Accepted: May 26, 2023

Received in revised form: May 24, 2023

Received: May 5, 2023

### Publication stage

In Press Journal Pre-Proof

### Identification

DOI: <https://doi.org/10.1016/j.ophtha.2023.05.029>

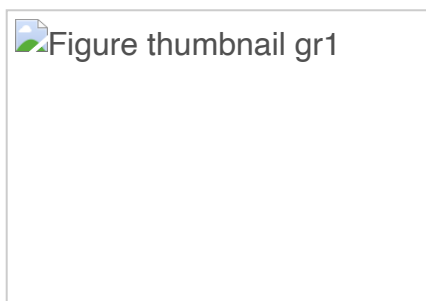
### Copyright

© 2023 by the American Academy of Ophthalmology

### ScienceDirect

[Access this article on ScienceDirect](#)

## Figures



## Related Articles



<a href="#">Home</a>	<a href="#">Editorials</a>	<a href="#">Ophthalmology Journal Podcast</a>	<a href="#">Submit a Manuscript</a>	<a href="#">Academy Member Access</a>
<b>ARTICLES &amp; ISSUES</b>	<a href="#">Editorship Series</a>	<a href="#">Pictures &amp; Perspectives</a>	<b>JOURNAL INFO</b>	<a href="#">About the Academy</a>
<a href="#">Articles In Press</a>	<a href="#">IOL Article Collection</a>	<a href="#">Video Collection by Topic</a>	<a href="#">About the Journal</a>	<a href="#">Contact the Academy</a>
<a href="#">Current Issue</a>	<a href="#">IRIS Registry Articles</a>	<a href="#">Virtual Journal Club Videos</a>	<a href="#">ABO Quarterly Questions</a>	<a href="#">Forget your membership login?</a>
<a href="#">List of Issues &amp; Supplements</a>	<a href="#">Myopia</a>	<b>AUTHORS &amp; REVIEWERS</b>	<a href="#">About Open Access</a>	<a href="#">Membership Information</a>
<b>COLLECTIONS</b>	<a href="#">Ophthalmic Technology Assessments</a>	<a href="#">2020 Scientific Referees</a>	<a href="#">Contact Information</a>	<a href="#">News</a>
<a href="#">The Collaborative Community on Ophthalmic Imaging</a>	<a href="#">Preferred Practice Pattern Guidelines</a>	<a href="#">Guide for Authors</a>	<a href="#">Editorial Board</a>	<a href="#">Ophthalmology Retina</a>
<a href="#">Commentaries</a>	<a href="#">Top 10 Trending Articles</a>	<a href="#">Guide for Reviewers</a>	<a href="#">Info for Advertisers</a>	<a href="#">Ophthalmology Glaucoma</a>
<a href="#">COVID-19 Article Collection</a>	<a href="#">Translational Science Reviews</a>	<a href="#">Miscellaneous Links</a>	<a href="#">New Content Alerts</a>	<a href="#">Ophthalmology Science</a>
<a href="#">Correspondence Archive</a>	<b>MULTIMEDIA</b>	<a href="#">Register to Review</a>	<a href="#">Reprints</a>	<b>FOLLOW US</b>
<a href="#">Diversity, Equity and Inclusion (DEI)</a>	<a href="#">Cover Art Gallery</a>	<a href="#">Researcher Academy</a>	<a href="#">Subscribe</a>	<a href="#">Twitter</a>
			<b>AMERICAN ACADEMY OF OPHTHALMOLOGY</b>	

---

**The content on this site is intended for healthcare professionals.**

---

We use cookies to help provide and enhance our service and tailor content. To update your cookie settings, please visit the [Cookie Settings](#) for this site.

Copyright © 2023 Elsevier Inc. except certain content provided by third parties.

[Privacy Policy](#) [Terms and Conditions](#) [Accessibility](#) [Help & Contact](#)

