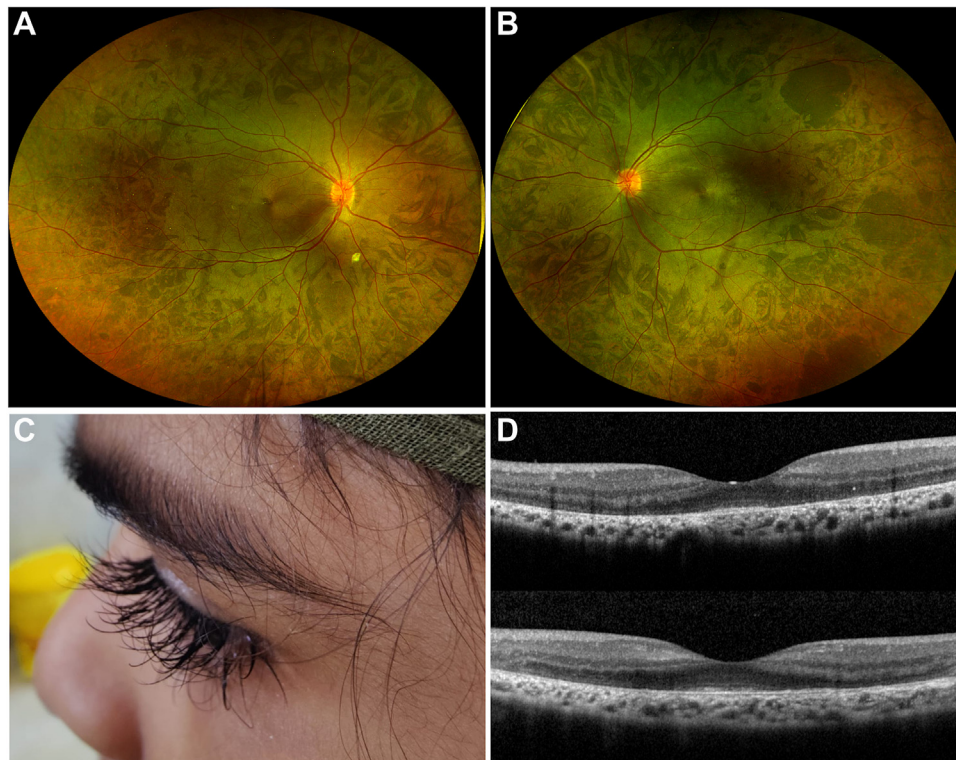


24. Hirabayashi K, Yu HJ, Wakatsuki Y, et al. OCT risk factors for development of atrophy in eyes with intermediate age-related macular degeneration. *Ophthalmol Retin.* 2023;7: 253–260.
25. Schmitz-Valckenberg S, Fleckenstein M, Göbel AP, et al. Optical coherence tomography and autofluorescence findings in areas with geographic atrophy due to age-related macular degeneration. *Invest Ophthalmol Vis Sci.* 2011;52:1–6.
26. Sayegh RG, Simader C, Scheschy U, et al. A systematic comparison of spectral-domain optical coherence tomography and fundus autofluorescence in patients with geographic atrophy. *Ophthalmology.* 2011;118:1844–1851.
27. Hu Z, Medioni GG, Hernandez M, et al. Segmentation of the geographic atrophy in spectral-domain optical coherence tomography and fundus autofluorescence images. *Invest Ophthalmol Vis Sci.* 2013;54:8375–8383.

Pictures & Perspectives



Retinitis Pigmentosa in Oliver McFarlane Syndrome

A 7-year-old boy presented with complaints of progressive night blindness. The child had growth retardation along with bone age less than actual age and was on growth hormone replacement therapy. Corrected visual acuity was 20/200 in both eyes. Examination revealed midperipheral coarse retinal pigmentation (A, B) and trichomegaly (C). OCT showed only a small segment of preserved ellipsoid zone near foveola (D, upper right eye and lower left eye). Genetic evaluation revealed heterozygous missense variant c.3241G>A in exon 30 of *PNPLA6* gene. A diagnosis of retinitis pigmentosa in the setting of Oliver McFarlane syndrome was made and parents were apprised of the condition. (Magnified version of Figure A-D is available online at www.ophtalmologyretina.org).

SOMYA KUMARI, MD

VIRENDRA BAGRANIYA, MBBS

VINOD KUMAR, MS, FRCS

Dr Rajendra Prasad Centre for Ophthalmic Sciences, All India Institute of Ophthalmic Sciences, New Delhi, India