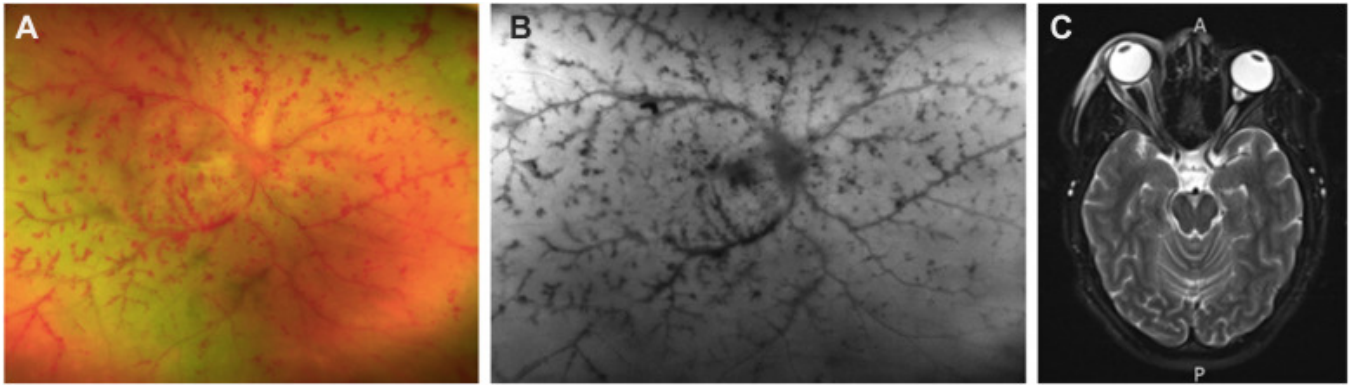


# Saturday Night Retinopathy



A 27-year-old woman presented with sudden no-light perception vision, proptosis, and ophthalmoplegia in her right eye after laying on the right side of her face for hours after intravenous heroin use. A fundus examination revealed a diffusely pale retina with perivascular intraretinal hemorrhages, attenuated arteries, and an edematous hyperemic optic disc (**A**, **B**). Imaging showed right-sided enlargement of the superior and lateral rectus muscle, along with retrobulbar and periorbital edema (**C**). This is a case of Saturday night retinopathy, in which external compression of the globe in the setting of prolonged drug-induced unconsciousness causes ischemic retinopathy (Magnified version of Figure **A–C** is available online at [www.ophthalmologyretina.org](http://www.ophthalmologyretina.org)).