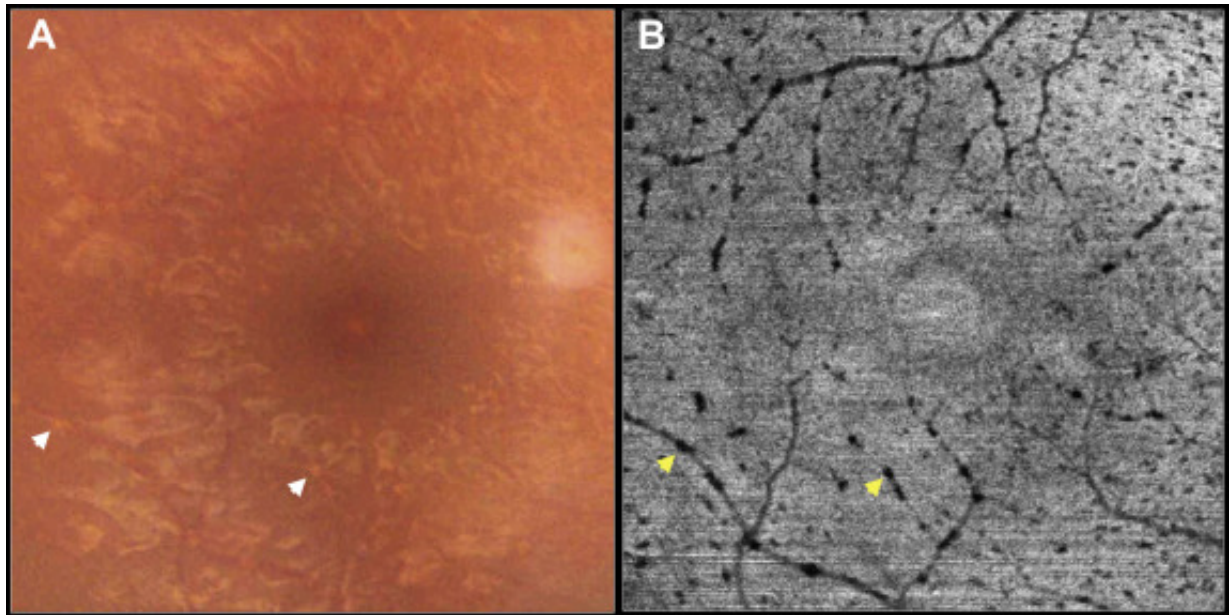


Swept-Source OCT Findings in Ocular Siderosis



A 22-year-old man had ocular siderosis resulting from an intravitreal iron foreign body retained for 10 months. A color photograph (**Fig 1A**) obtained 1 month after foreign body removal shows faint perivascular deposits (white arrows), which can be seen best as hyporeflective dots along the vessels (yellow arrows) on an outer retinal slab (inner limit, 70.2 μm deep to the junction of the inner plexiform layer and inner nuclear layer; outer limit, Bruch's membrane) of en face OCT (**Fig 1B**) resulting from shadowing from inner retinal deposits. Cross-sectional OCT (**Fig 2A**) shows hyperreflective dots in inner retina (white arrows) with shadowing in deeper layers correlating with the hyporeflective dots (yellow arrows) on a projection image (**Fig 2B**) that may suggest inner retinal iron deposits.