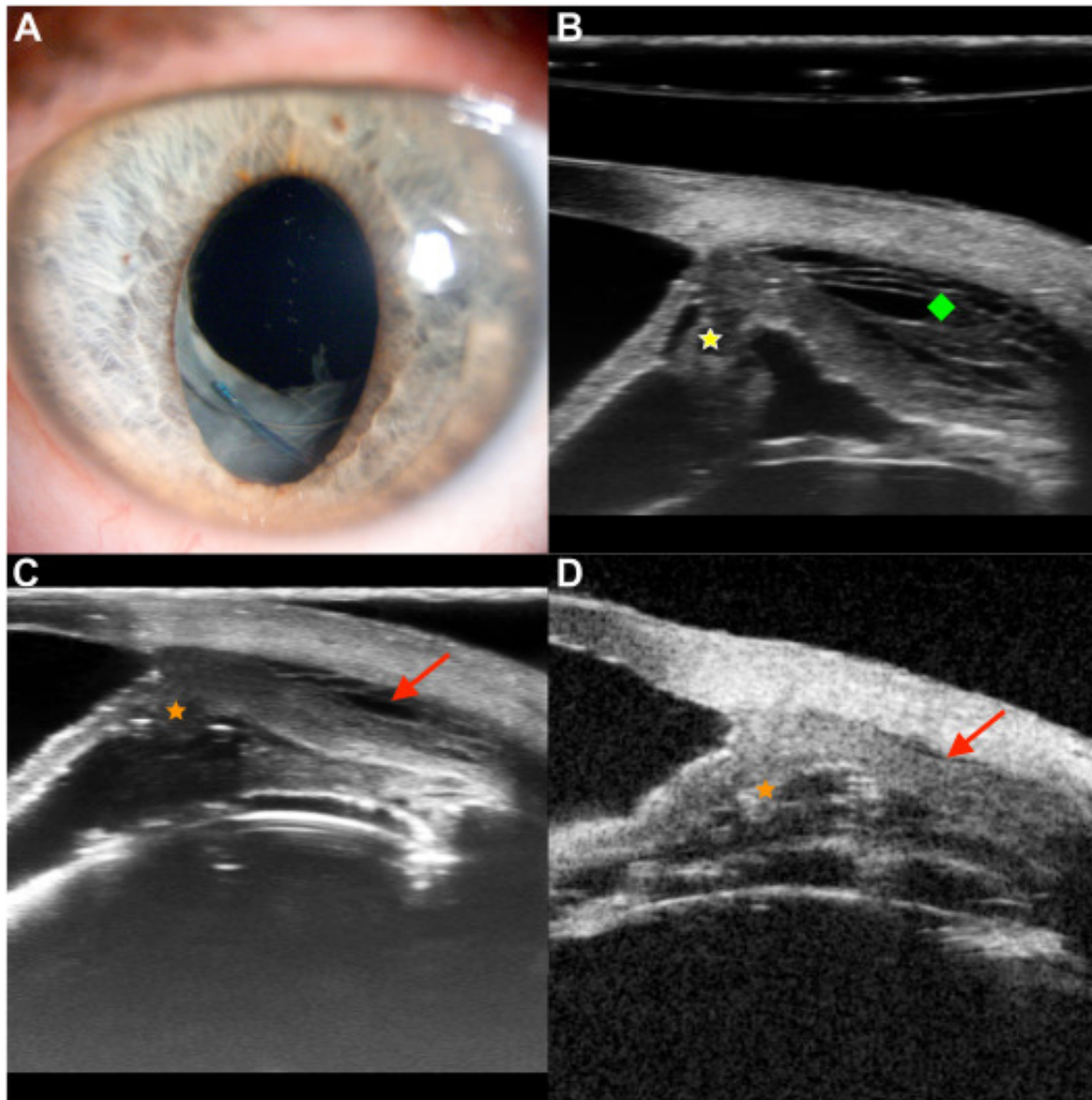


Ultrahigh and High-frequency Ultrasound Imaging in Uveal Effusion



Four weeks after a successful combined surgery for recurrent inferior rhegmatogenous retinal detachment (vision 20/200), a 65-year-old White man presented with suspected uveal effusion: severe hypotony (4 mmHg), atonic iris (**A**) without contributing fundus findings. Ultrahigh-frequency (70 MHz) ultrasound provided essential information (**B**): spongy

edematous ciliary body (CB) region (yellow star) and interstitial lacunae beneath the sclera (green square), mainly within the inferior 180°. The patient did not respond to prednisone medication. Early silicone oil injection partially resolved uveal effusion (vision 20/200, intraocular pressure stabilized at 12 mmHg): 6 months postoperatively, the 70 MHz probe (**C**) accurately showed residual anterior uveal edema (red arrow) with CB atrophy (orange star), compared with the classical high-frequency (50 MHz) probe (**D**). Silicone oil removal was not attempted. (Magnified version of Figure **A-D** is available online at www.aaojournal.org).