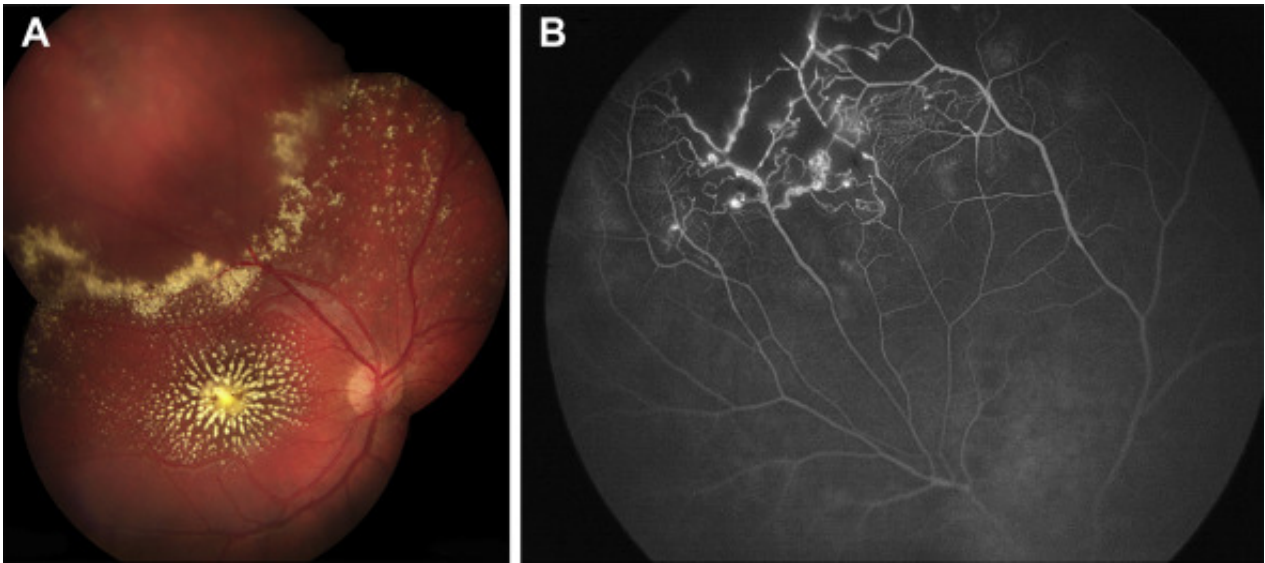


# Coats' Disease Presenting with Macula Star



An 8-year-old boy presented after failed vision screening with reduced vision to counting fingers in his right eye. **(A)** Color montage photograph of the right eye shows lipid in a macular star configuration from large amount of subretinal exudation in the fovea, and a superotemporal exudative detachment with surrounding hard exudates. **(B)** Fluorescein angiography shows superotemporal telangiectatic vessels, leaking aneurysms, and peripheral capillary dropout, characteristic of Coats' disease.

## Article info

## Copyright

© 2020 by the American Academy of Ophthalmology