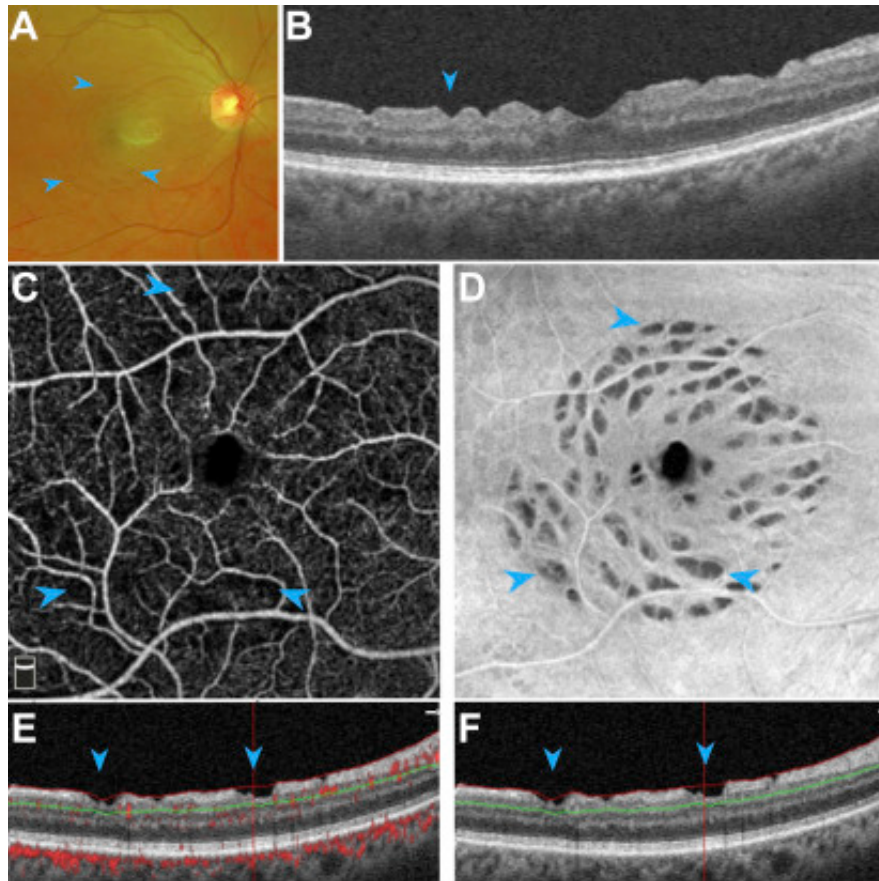


Multimodal Imaging of Dissociated Optic Nerve Fiber Layer after Internal Limiting Membrane Peel



A 60-year-old woman with previous macular hole repair sought treatment for concentric perifoveal spots revealed on fundus photography (A). OCT imaging (B) showed inner retinal dimples (arrowheads). En face OCT angiography (C–D) with decorrelation overlay (E–F) highlighted superficial capillary flow voids within these defects (arrowheads). Dissociated optic nerve fiber layer, a pattern of inner retinal injury after surgical peeling of the internal limiting membrane, is believed to be related to Müller cell trauma. Our patient demonstrated capillary nonperfusion associated with dissociated optic nerve fiber layer findings. Additional research is needed to understand if this is a retinal injury sequela or a risk factor for dissociated optic nerve fiber layer development.