

DR & DME: Imaging Pathophysiology

Multimodal OCT: Research and Routine

Prof Usha Chakravarthy, PhD

The editor for this module is:

Prof Usha Chakravarthy, PhD
Institute of Clinical Science,
The Queen's University of Belfast,
Belfast, UK



 **Click the tabs for Copyright Notice, Financial Disclosure and Acknowledgements**

Copyright Notice

Financial Disclosure

Acknowledgements

Objectives

Modern imaging technologies - particularly OCT - can provide great detail on the pathophysiology of diabetic retinopathy and diabetic macular edema.

This module will explore the information we can learn about changes that happen in the retinal microvasculature, the features of ischemia and the breakdown of the blood-inner retinal barrier in diabetic patients.

Having completed this module, you will be able to:

- ✓ Describe how imaging has been used to describe the different stages of the pathophysiology of diabetic eye disease
- ✓ Describe the classification systems used to describe the manifestations and severity of diabetic eye disease
- ✓ Identify the kind of information that is provided by various imaging technologies in the investigation of diabetic eye disease
- ✓ Describe the appearance of various changes in microvasculature, ischaemia and the breakdown of the blood-retinal barrier that can be seen on OCT

Recommended Reading

Boyer et al's 2013 paper provides an excellent analysis of the pathophysiology of diabetic retinopathy and diabetic macular edema. This is **free to read online**:

[Boyer DS, Hopkins JJ, Sorof J, Ehrlich JS. Anti-vascular endothelial growth factor therapy for diabetic macular edema. *Therapeutic Advances in Endocrinology and Metabolism*. 2013;4\(6\):151-169](#)

Overview

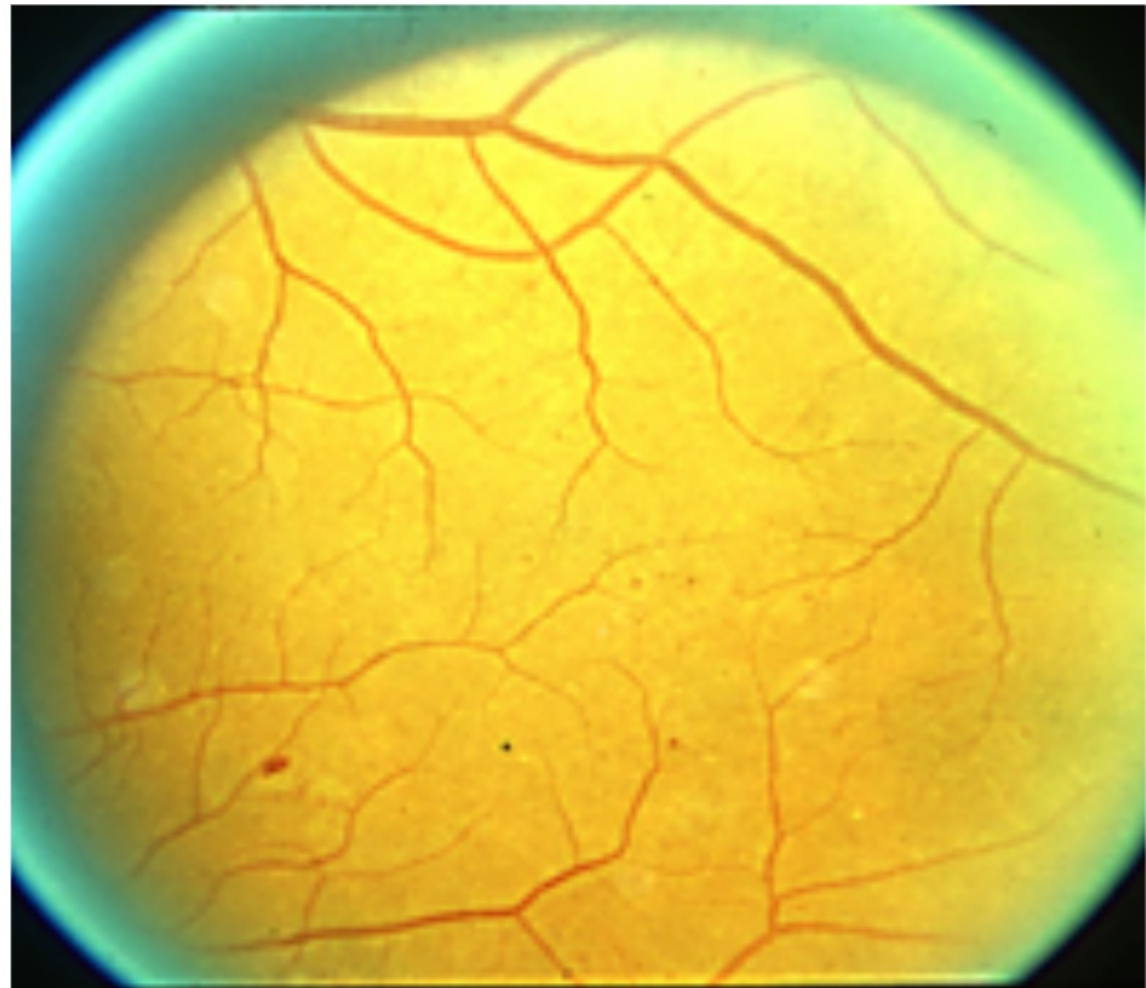
This module is divided into the topics listed below; each is followed by a quiz if you chose this option on the first screen. Click next to begin. Revisit any section by clicking it here.

Imaging for Classification of Diabetic Retinopathy

Imaging Pathophysiology in DR & DME

Summary

Knowledge Check



Click the buttons above to visit a specific topic or the next button below to visit all topics in order

Overview

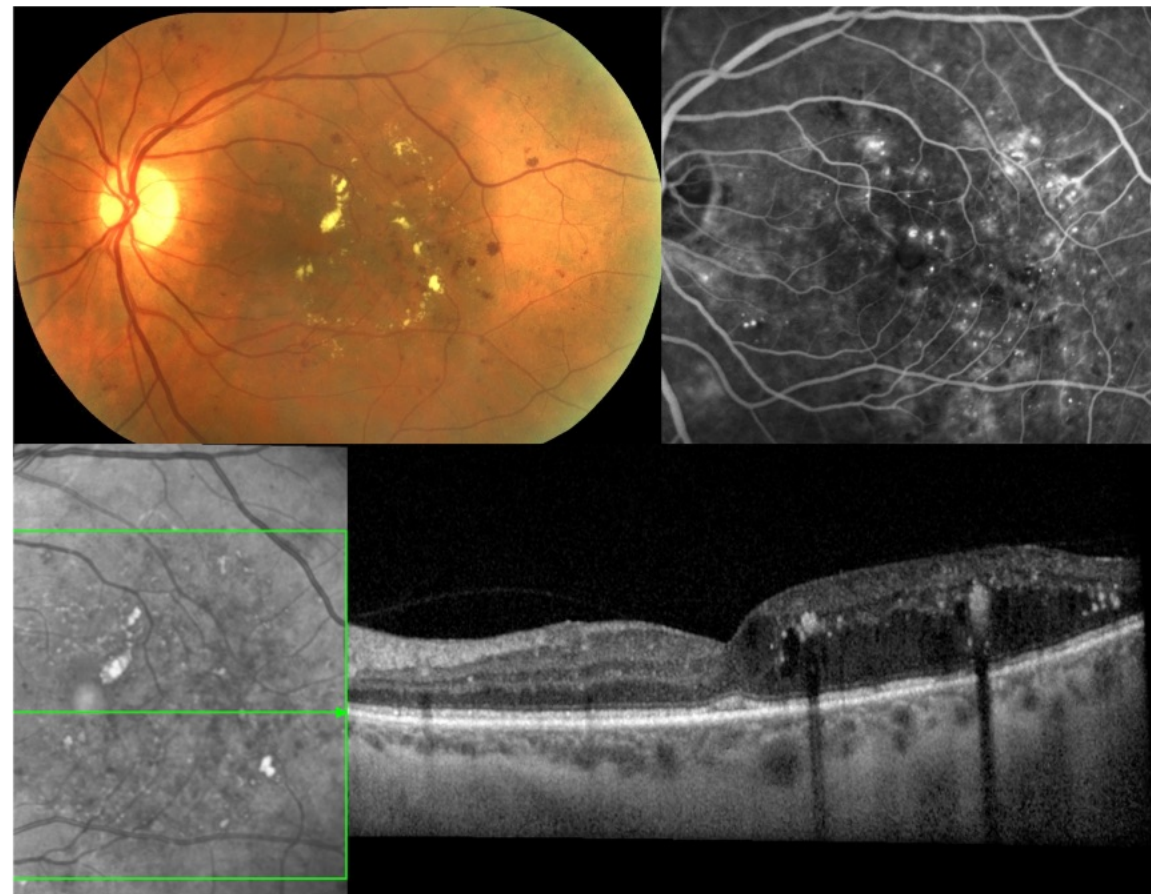
This module is divided into the topics listed below; each is followed by a quiz if you chose this option on the first screen. Click next to begin. Revisit any section by clicking it here.

Imaging for Classification of Diabetic Retinopathy

Imaging Pathophysiology in DR & DME

Summary

Knowledge Check



Click the buttons above to visit a specific topic or the next button below to visit all topics in order

Overview

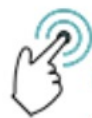This module is divided into the topics listed below; each is followed by a quiz if you chose this option on the first screen. Click next to begin. Revisit any section by clicking it here.

Imaging for Classification of Diabetic Retinopathy

Imaging Pathophysiology in DR & DME

Summary

Knowledge Check



Click the buttons above to visit a specific topic or the next button below to visit all topics in order

Overview

This module is divided into the topics listed below; each is followed by a quiz if you chose this option on the first screen. Click next to begin. Revisit any section by clicking it here.

Imaging for Classification of Diabetic Retinopathy

Imaging Pathophysiology in DR & DME

Summary

Knowledge Check



Click the buttons above to visit a specific topic or the next button below to visit all topics in order

Module Progress:

Welcome 

Imaging for Classification of DR

Imaging Pathophysiology of DR & DME

Summary

Knowledge Check

Imaging for Classification of Diabetic Retinopathy

Introduction

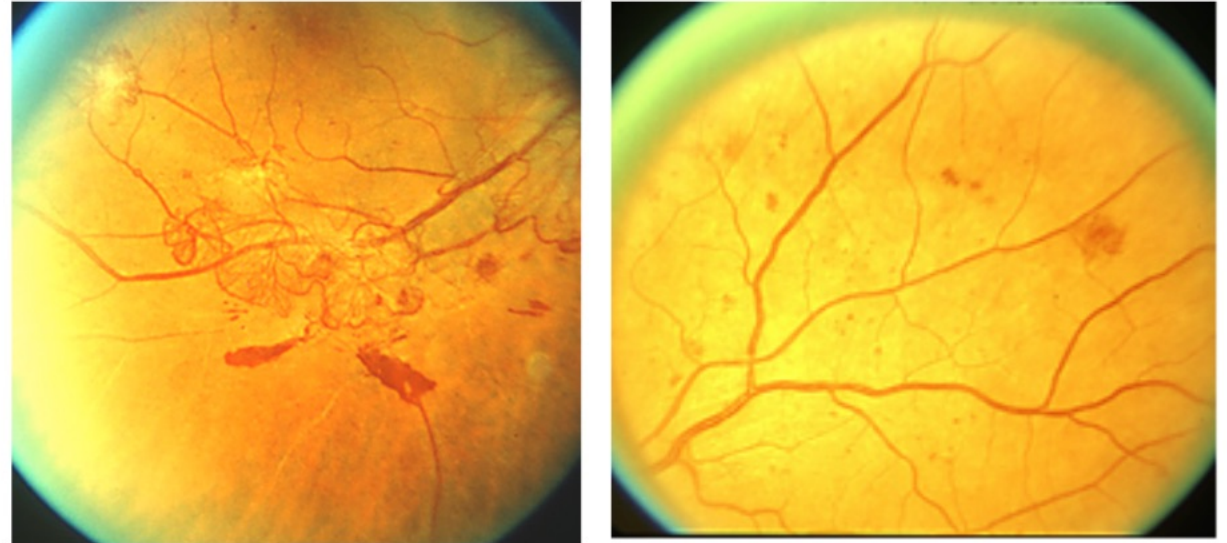
Diabetes causes a range of changes in the retinal microvasculature, leading to ischaemia and the eventual breakdown of the blood-retinal barrier.

Key events that can be imaged include:

- Pre-retinal neovascularisation
- Capillary non perfusion
- Microaneurysms

With multimodal imaging, we are gaining better understanding of these events.

We can also plot their course- how they develop and where they develop (within the layers of the retina).



ETDRS Standard Photographs, ETDRS Study Group and Reading Centre at the University of Wisconsin

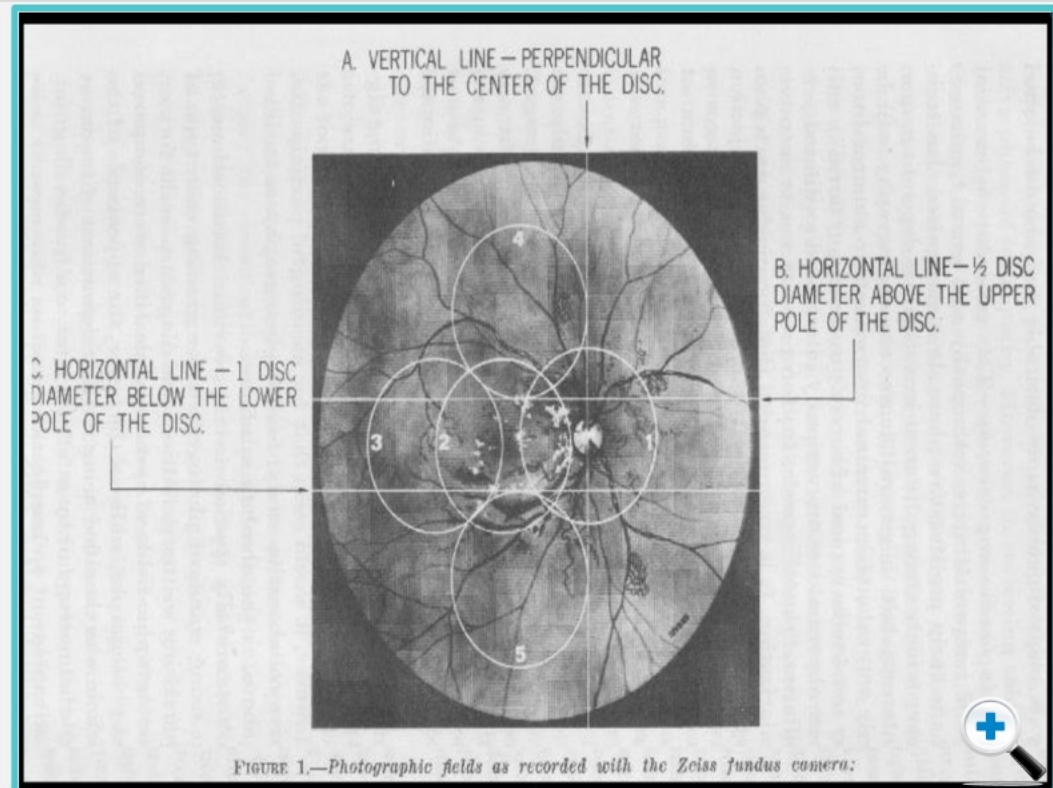
DR Classification & Grading: Fundus Photographs

This topic will explore the development of colour fundus photograph-based classification and grading systems to describe diabetic eye disease.

These systems used colour fundus photographs to provide a structured, feature-based grading system that demonstrates:

- The clinical manifestations of diabetic retinopathy
- The extent/number of these manifestations at each stage of the disease (describing disease progression)

In the original **Airlie House** publication, photographs were taken, and images drawn to grade diabetic retinopathy.



Use the arrows to see examples of the ETDRS standard photographs.

Airlie House Imaging for Classification of Diabetic Retinopathy



ine

D

Th
of
cla
de

Th
ph
fea
de

- T
- T

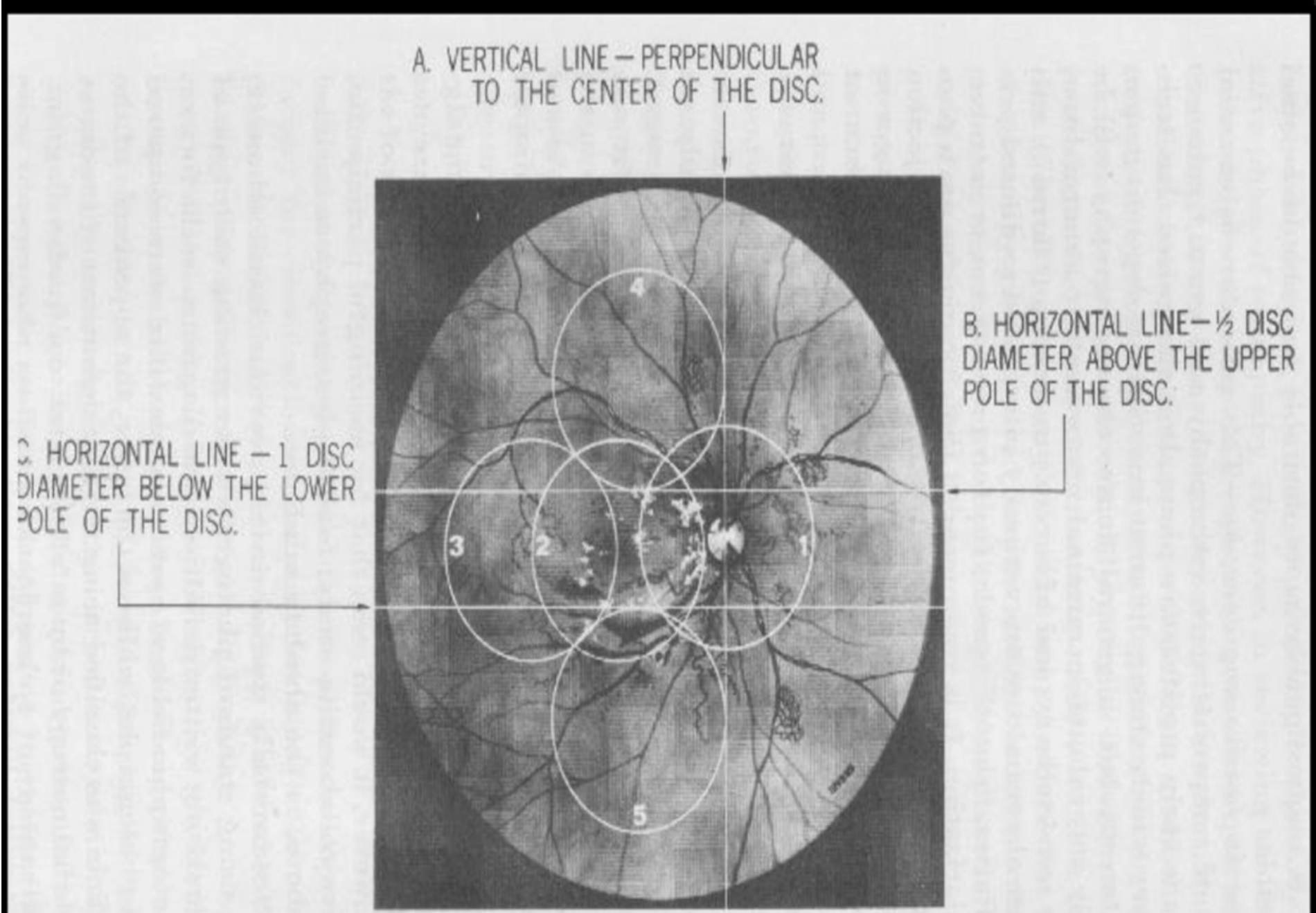


FIGURE 1.—Photographic fields as recorded with the Zeiss fundus camera:

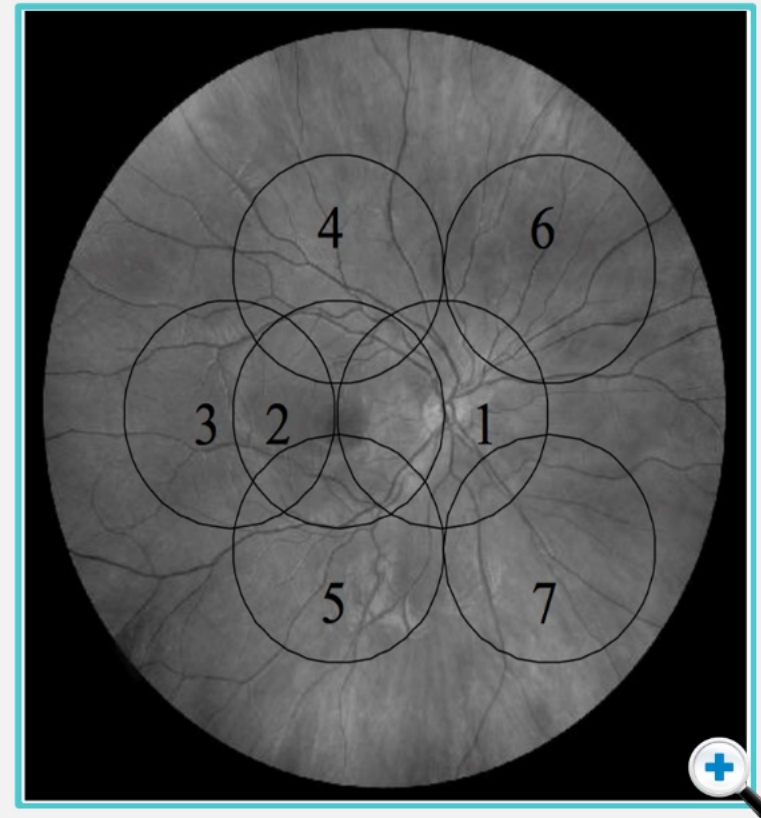
DR Classification & Grading: Fundus Photographs

This topic will explore the development of colour fundus photograph-based classification and grading systems to describe diabetic eye disease.

These systems used colour fundus photographs to provide a structured, feature-based grading system that demonstrates:

- The clinical manifestations of diabetic retinopathy
- The extent/number of these manifestations at each stage of the disease (describing disease progression)

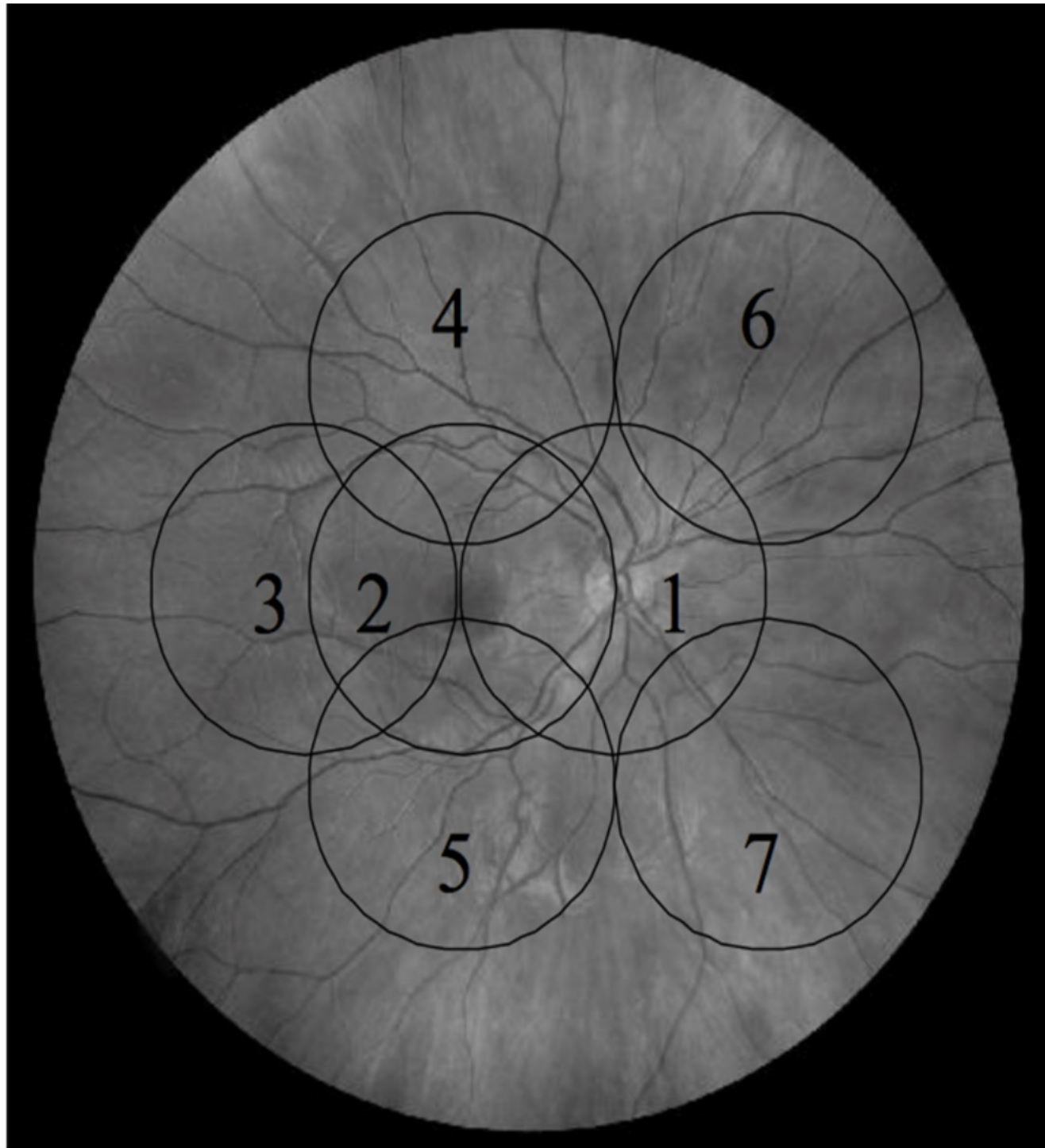
In 1971, the Airlie House classification was modified for the **Diabetic Retinopathy Study (DRS)**. Disease severity was graded based on colour fundus images.



 Use the arrows to see examples of the ETDRS standard photographs.



DRS Imaging for Classification of Diabetic Retinopathy



D

The of clade

The ph fea de

- T r
- T r c p

ine



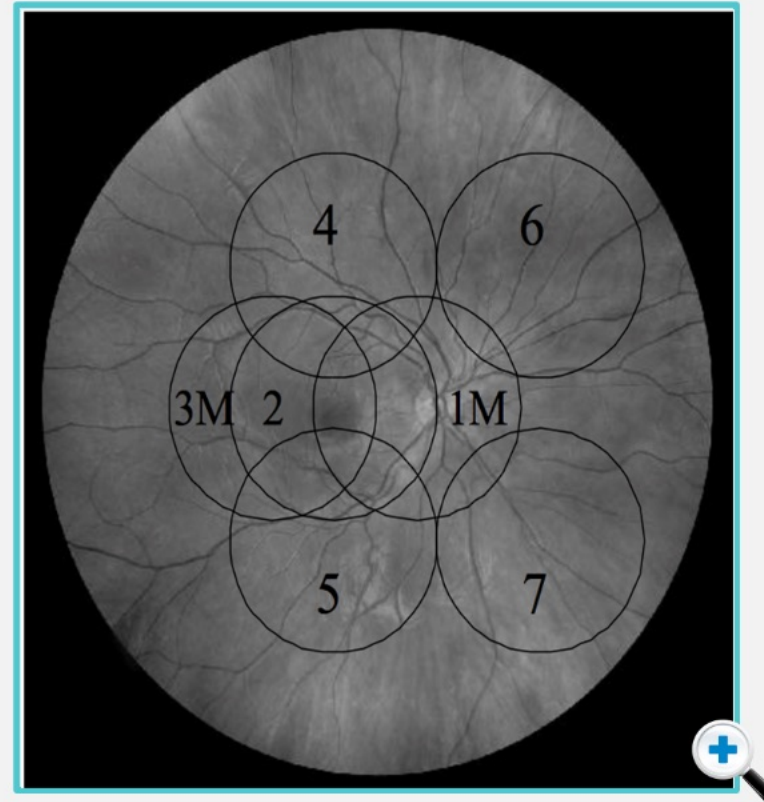
DR Classification & Grading: Fundus Photographs

This topic will explore the development of colour fundus photograph-based classification and grading systems to describe diabetic eye disease.

These systems used colour fundus photographs to provide a structured, feature-based grading system that demonstrates:

- The clinical manifestations of diabetic retinopathy
- The extent/number of these manifestations at each stage of the disease (describing disease progression)

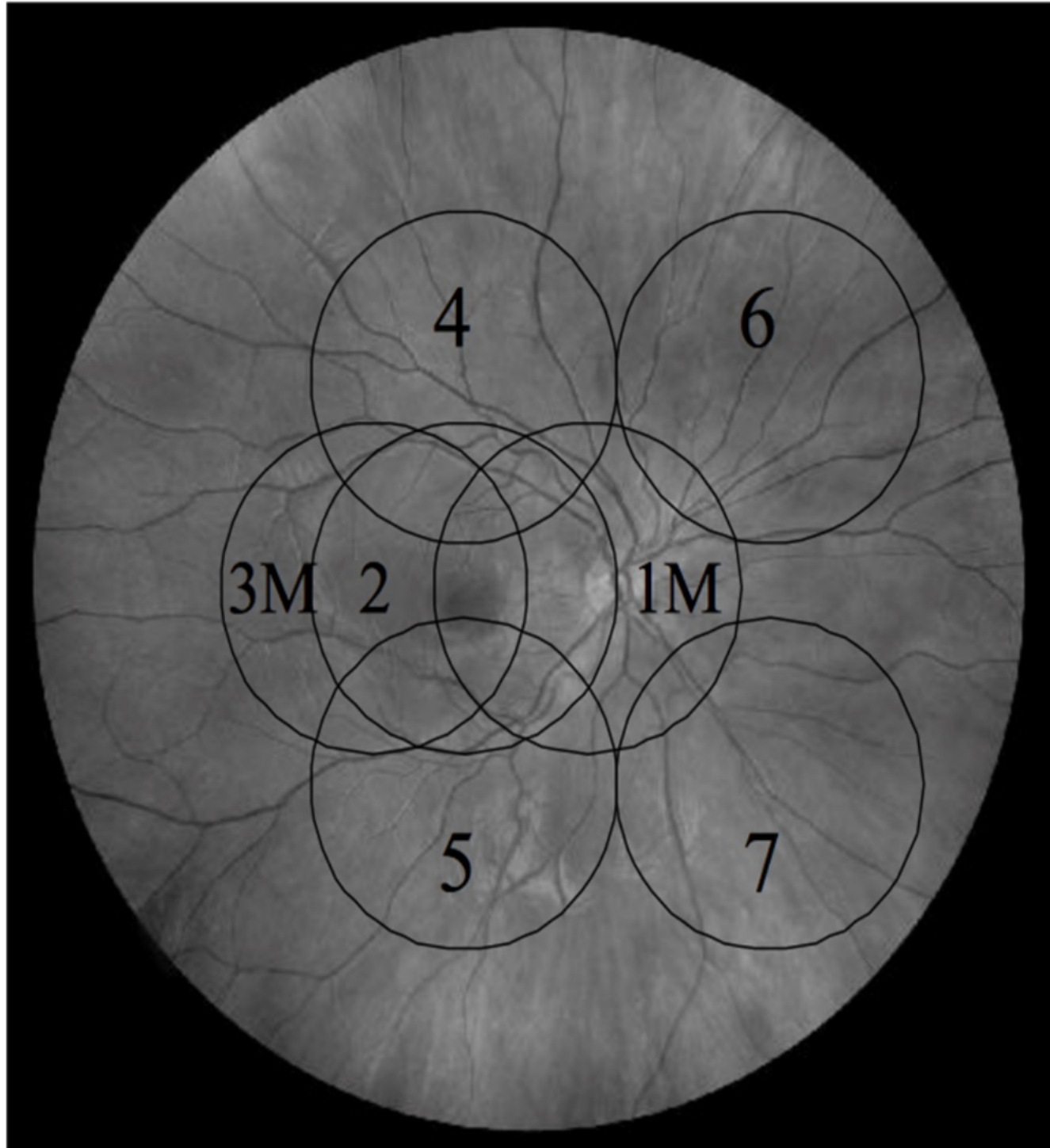
In the 1990s, the DRS classification was modified for the **Early Treatment of Diabetic Retinopathy Study (ETDRS)**. This system also relied on determining features of DR on colour fundus photography.



Use the arrows to see examples of the ETDRS standard photographs.



ETDRS Imaging for Classification of Diabetic Retinopathy



The
of
cla
de

Th
ph
fea
de
• T
r
• T
r
c
p

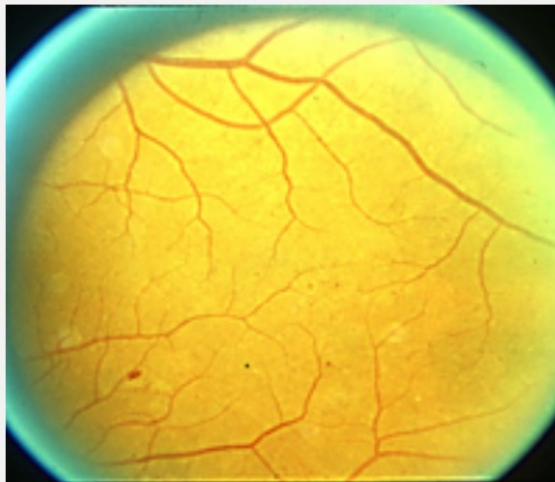
ine

Severity of Disease Grading

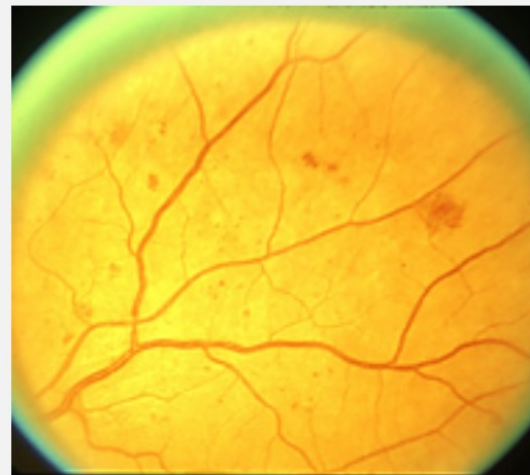
The ETDRS standard photographs offer a structured method for grading disease severity.

Lower Severity

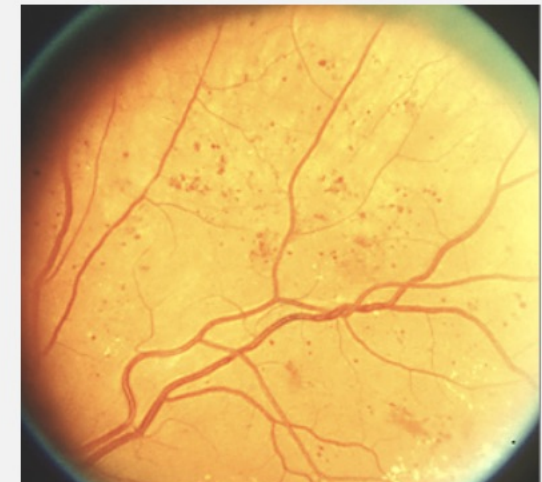
Haemorrhages and microaneurysms can be seen (on colour photography, these can be difficult to differentiate, so they are commonly considered as H/Ma).



ETDRS Standard photograph 1:
Occasional / few areas of
haemorrhage/ microaneurysms



ETDRS Standard photograph 2A
Scattered areas of haemorrhage/
microaneurysms



ETDRS Standard photograph 2B
More extensive haemorrhage/
microaneurysms



Use the arrows to see examples of the ETDRS standard photographs.

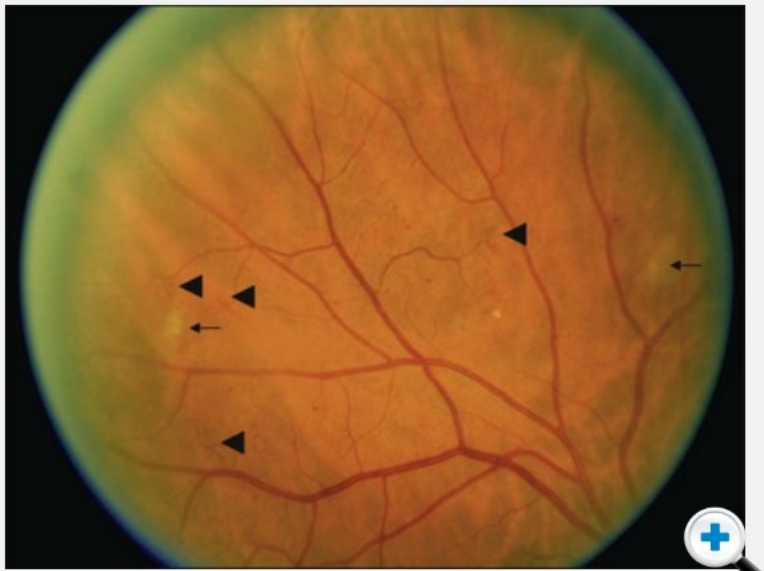
ETDRS Standard Photographs, ETDRS Study Group and Reading Centre at the University of Wisconsin

Severity of Disease Grading

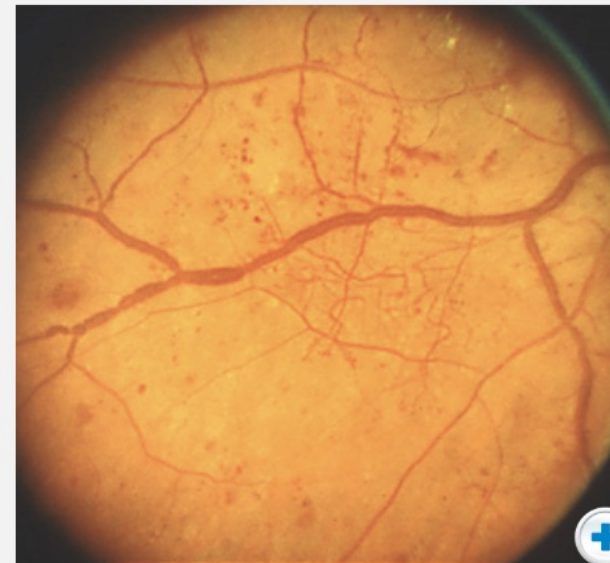
The ETDRS standard photographs offer a structured method for grading disease severity.

Lower Severity

Intraretinal microvascular abnormalities (IRMA), are seen as areas of vessel telangiectasia.



Standard Photograph 8A
Less severe soft exudates (Cotton Wool Spots) & IRMA



Standard Photograph 6B
Clusters regions of telangiectatic irregularly dilated small blood vessels. This image also shows beading of the larger retinal veins



Use the arrows to see examples of the ETDRS standard photographs.

ETDRS Standard Photographs, ETDRS Study Group and Reading Centre at the University of Wisconsin



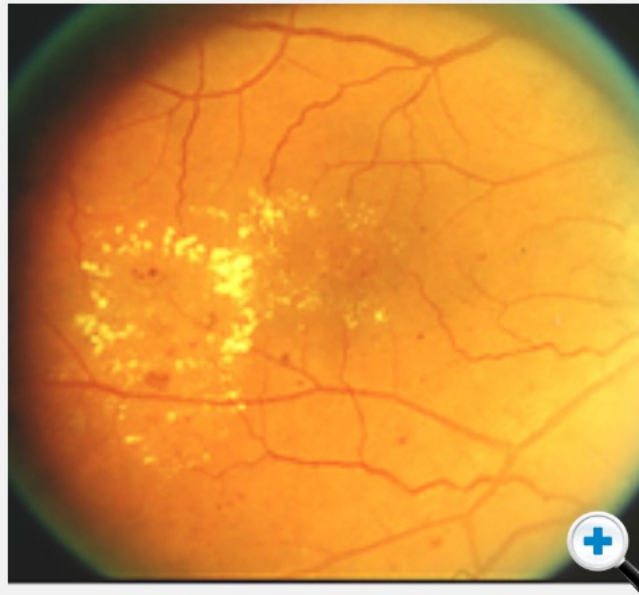
Severity of Disease Grading

The ETDRS standard photographs offer a structured method for grading disease severity.

Lower Severity

At the macula, there are two options - presence or absence of

- **hard exudates**
- **diabetic macular edema**



Standard Photograph 4

A ring of circularly disposed yellowish collection of hard exudates



Use the arrows to see examples of the ETDRS standard photographs.

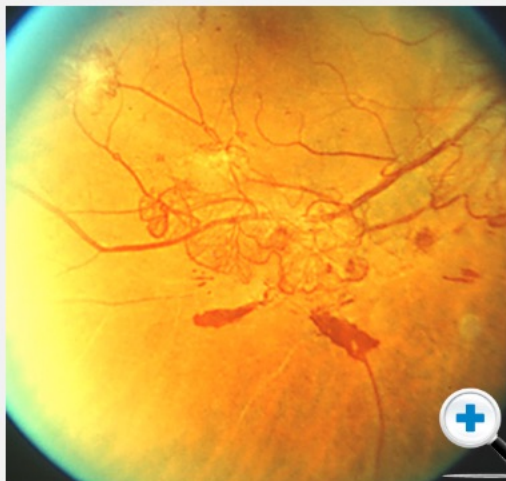ETDRS Standard Photographs, ETDRS Study Group and Reading Centre at the University of Wisconsin

Severity of Disease Grading

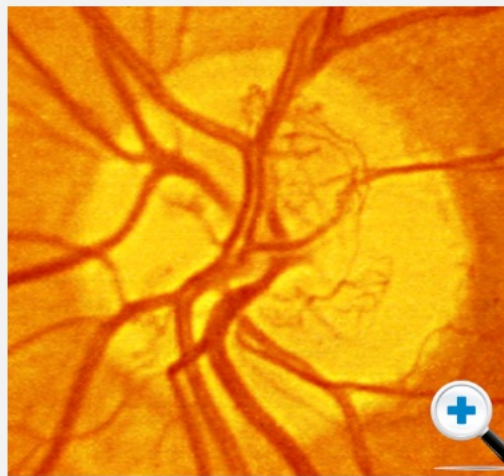The ETDRS standard photographs offer a structured method for grading disease severity.

Higher Severity

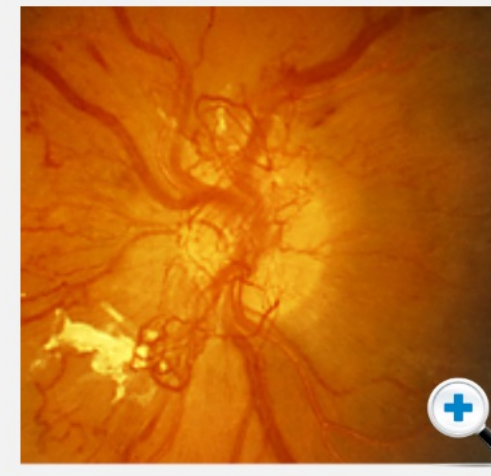
Neovascularisation: **New Vessels Elsewhere (NVE)**, **New Vessels on the Disc (NVD)**



ETDRS Standard photograph 7:
A network of tangled new vessels in the inferior temporal quadrant in an area remote from the optic disc. New vessels elsewhere (NVE)



ETDRS Standard photograph 10A:
NVD. A fine network of abnormal blood vessels are seen distinct from the normal large retinal arteries and veins within the optic disc



ETDRS Standard photograph 10C:
NVD. Extensive new vessel network expanding beyond the margins of the optic disc.



Use the arrows to see examples of the ETDRS standard photographs.

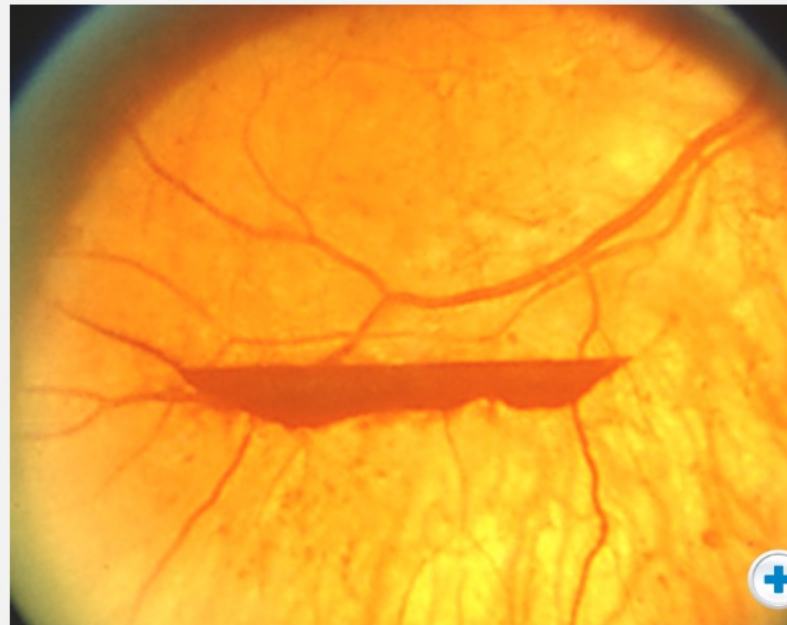
ETDRS Standard Photographs, ETDRS Study Group and Reading Centre at the University of Wisconsin

Severity of Disease Grading

The ETDRS standard photographs offer a structured method for grading disease severity.

Higher Severity

Vitreous Haemorrhage



ETDRS Standard photograph 13: lower boundary of moderate pre retinal haemorrhage



Use the arrows to see examples of the ETDRS standard photographs.

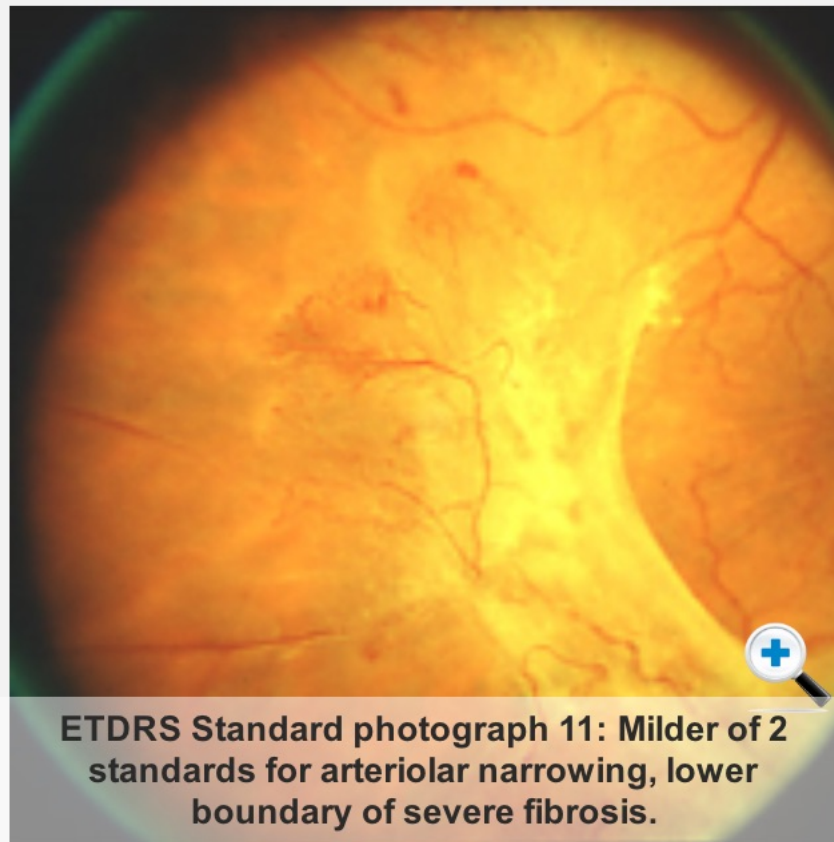ETDRS Standard Photographs, ETDRS Study Group and Reading Centre at the University of Wisconsin

Severity of Disease Grading

The ETDRS standard photographs offer a structured method for grading disease severity.

Higher Severity

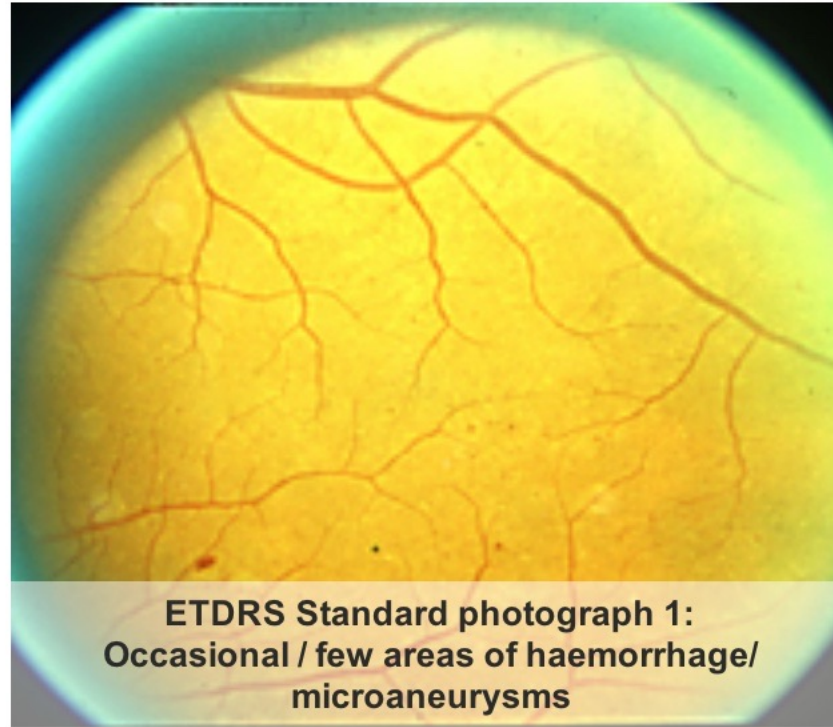
Fibrosis



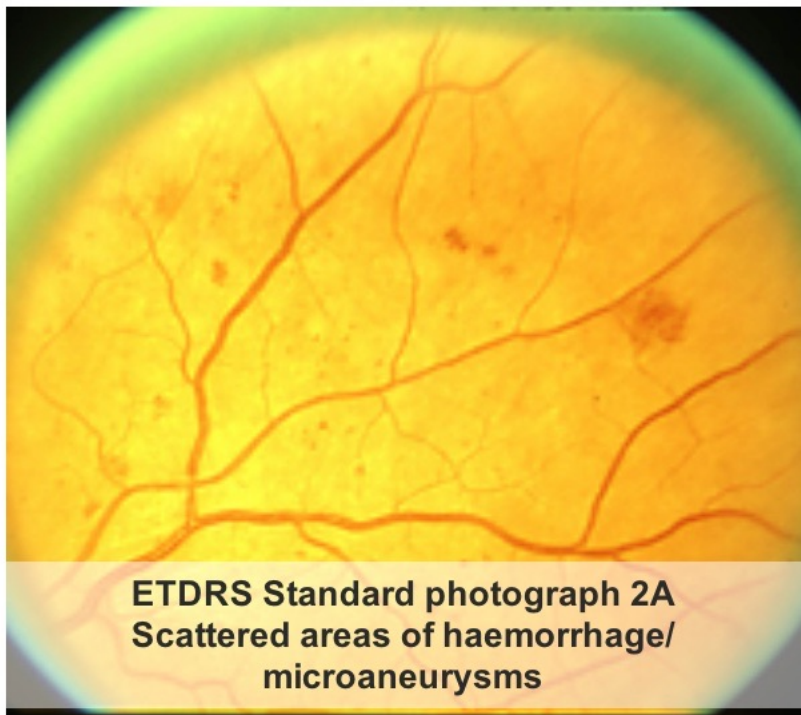Use the arrows to see examples of the ETDRS standard photographs.

ETDRS Standard Photographs, ETDRS Study Group and Reading Centre at the University of Wisconsin

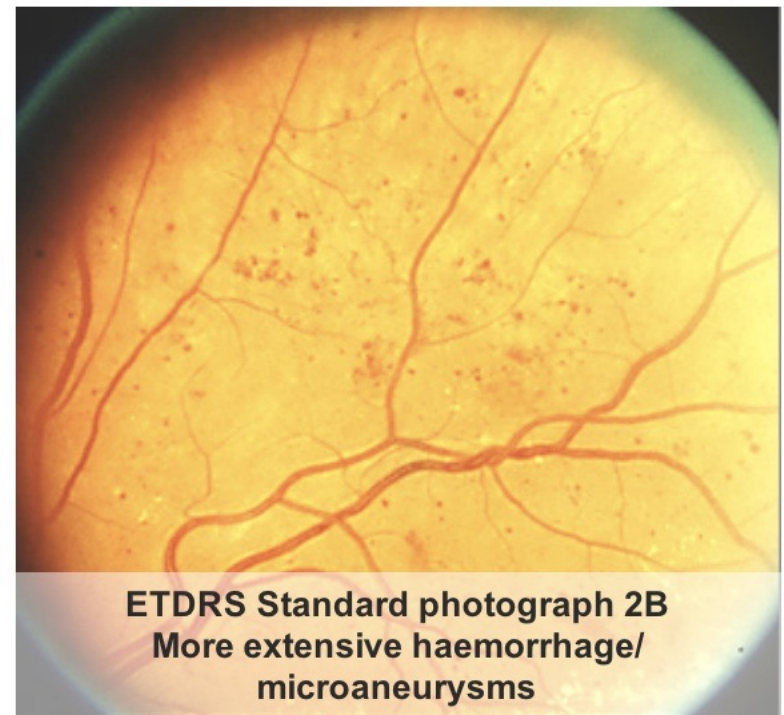Haemorrhages and microaneurysms



ETDRS Standard photograph 1:
Occasional / few areas of haemorrhage/
microaneurysms

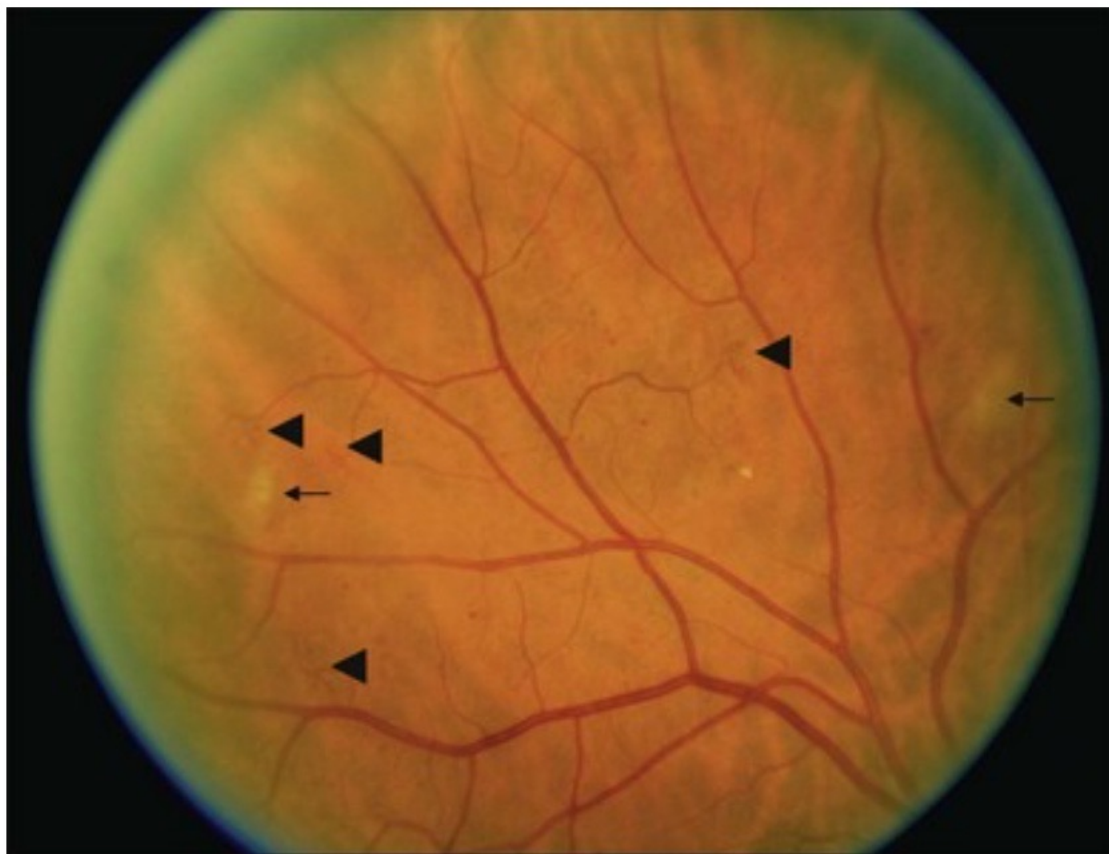


ETDRS Standard photograph 2A
Scattered areas of haemorrhage/
microaneurysms

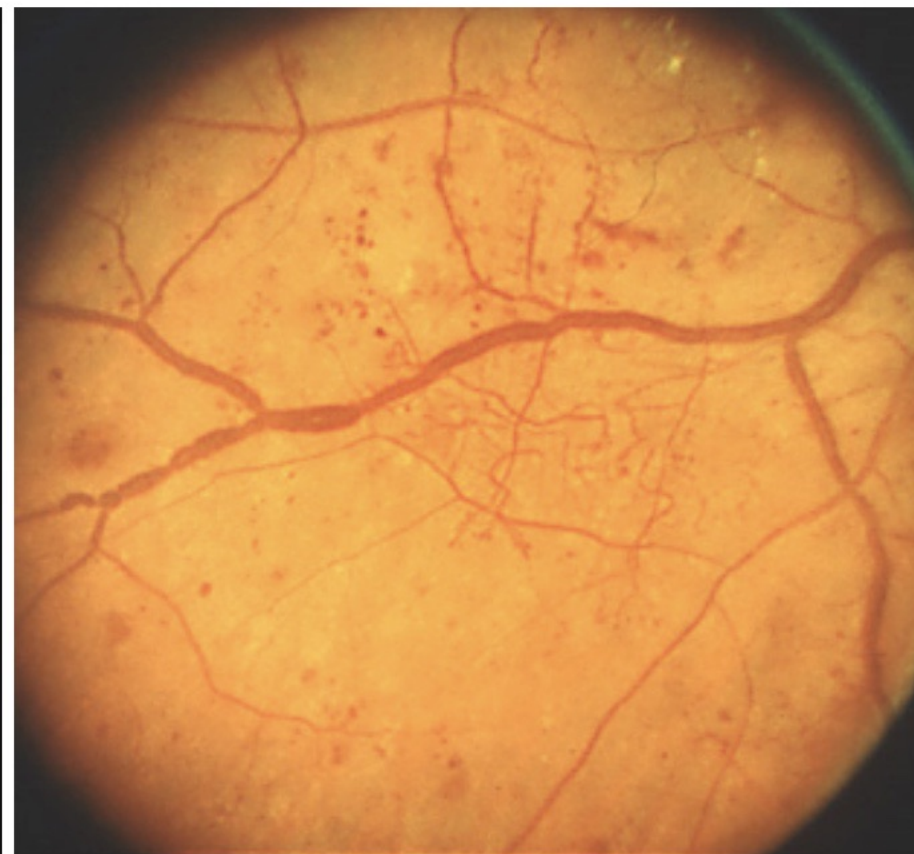

ETDRS Standard photograph 2B
More extensive haemorrhage/
microaneurysms

IRMA, Cotton Wool Spots (Soft Exudates)

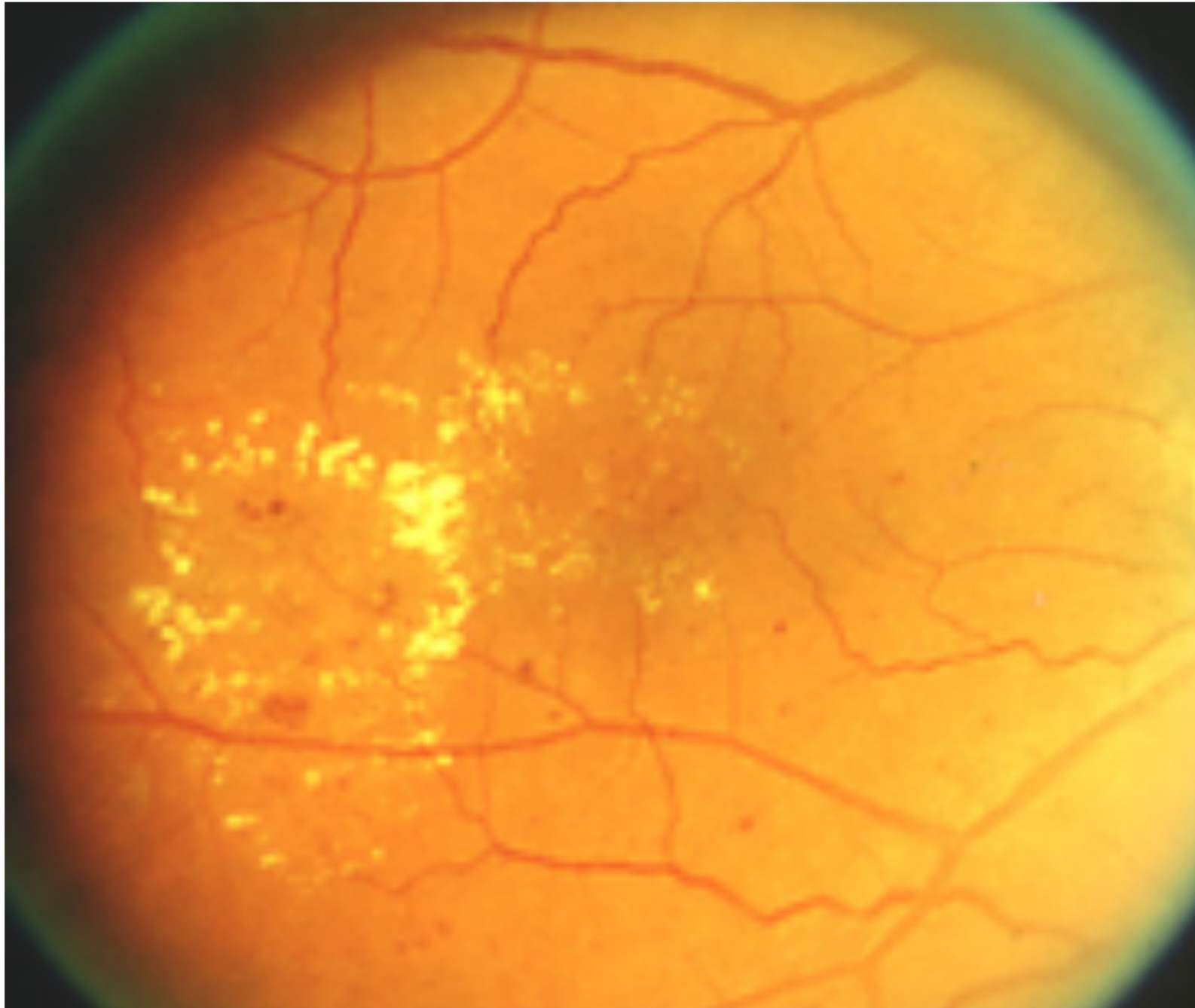


ETDRS Standard Photograph 8A
Less severe soft exudates (Cotton Wool Spots) & IRMA



ETDRS Standard Photograph 6B
Clusters regions of telangiectatic irregularly dilated small blood vessels. This image also shows beading of the larger retinal veins

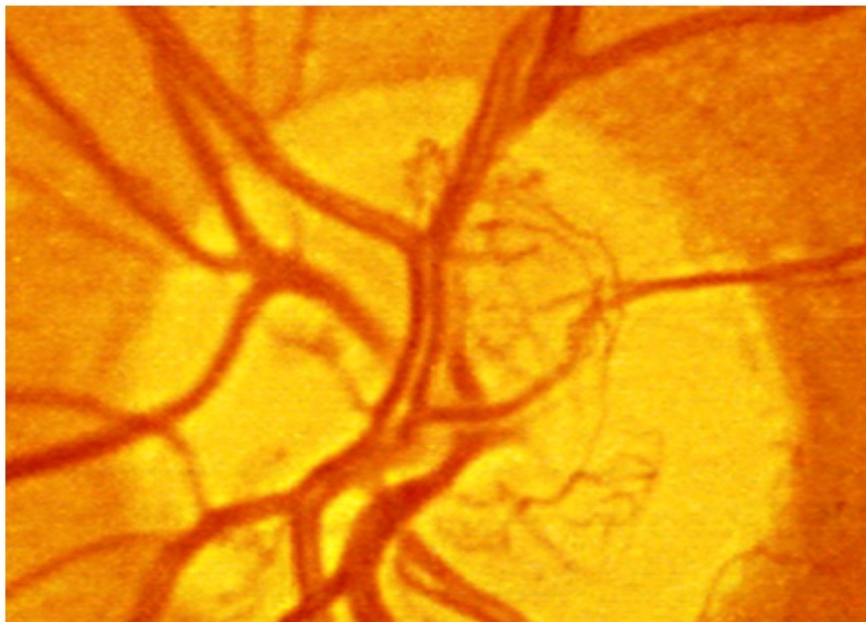
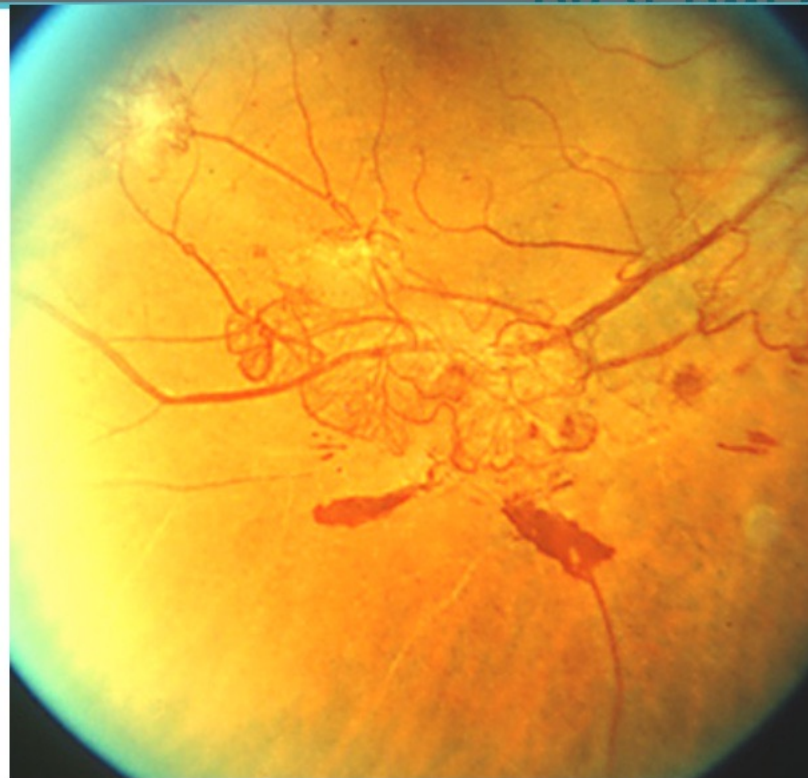
Hard Exudates



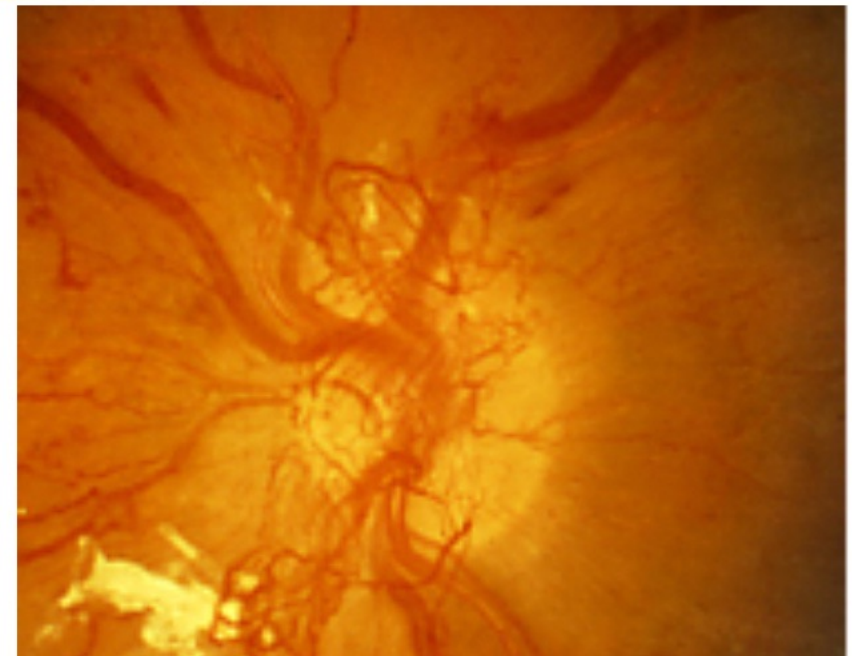
ETDRS Standard Photograph 4
A ring of circularly disposed yellowish collection of hard exudates

New Vessels

ETDRS Standard photograph 7:
A network of tangled new vessels in the inferior temporal quadrant in an area remote from the optic disc. New vessels elsewhere (NVE)

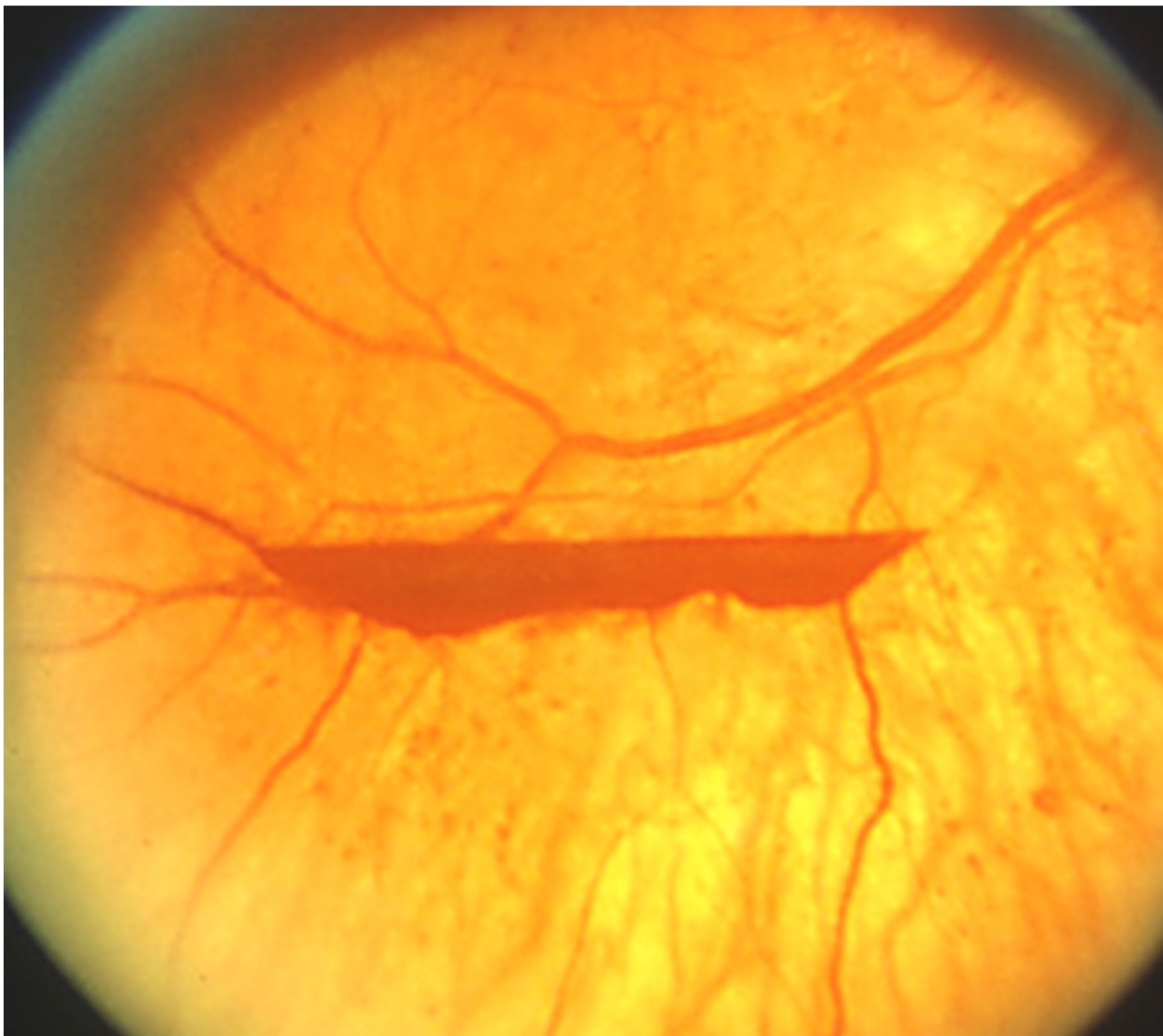


ETDRS Standard photograph 10A:
NVD. A fine network of abnormal blood vessels are seen distinct from the normal large retinal arteries and veins within the optic disc



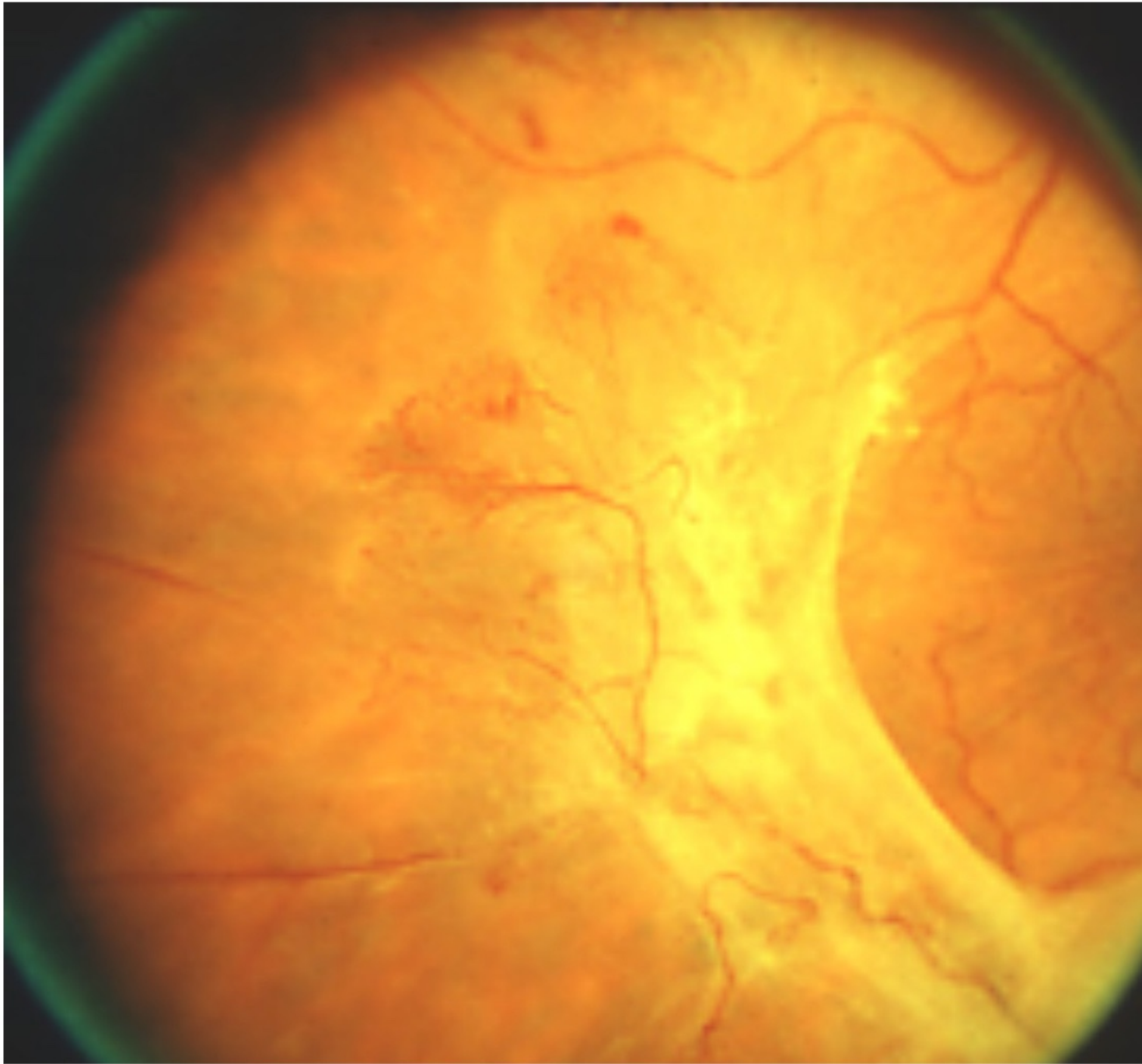
ETDRS Standard photograph 10C:
NVD. Extensive new vessel network expanding beyond the margins of the optic disc.

Vitreous Haemorrhage



ETDRS Standard photograph 13: lower boundary of moderate pre retinal haemorrhage

Fibrosis



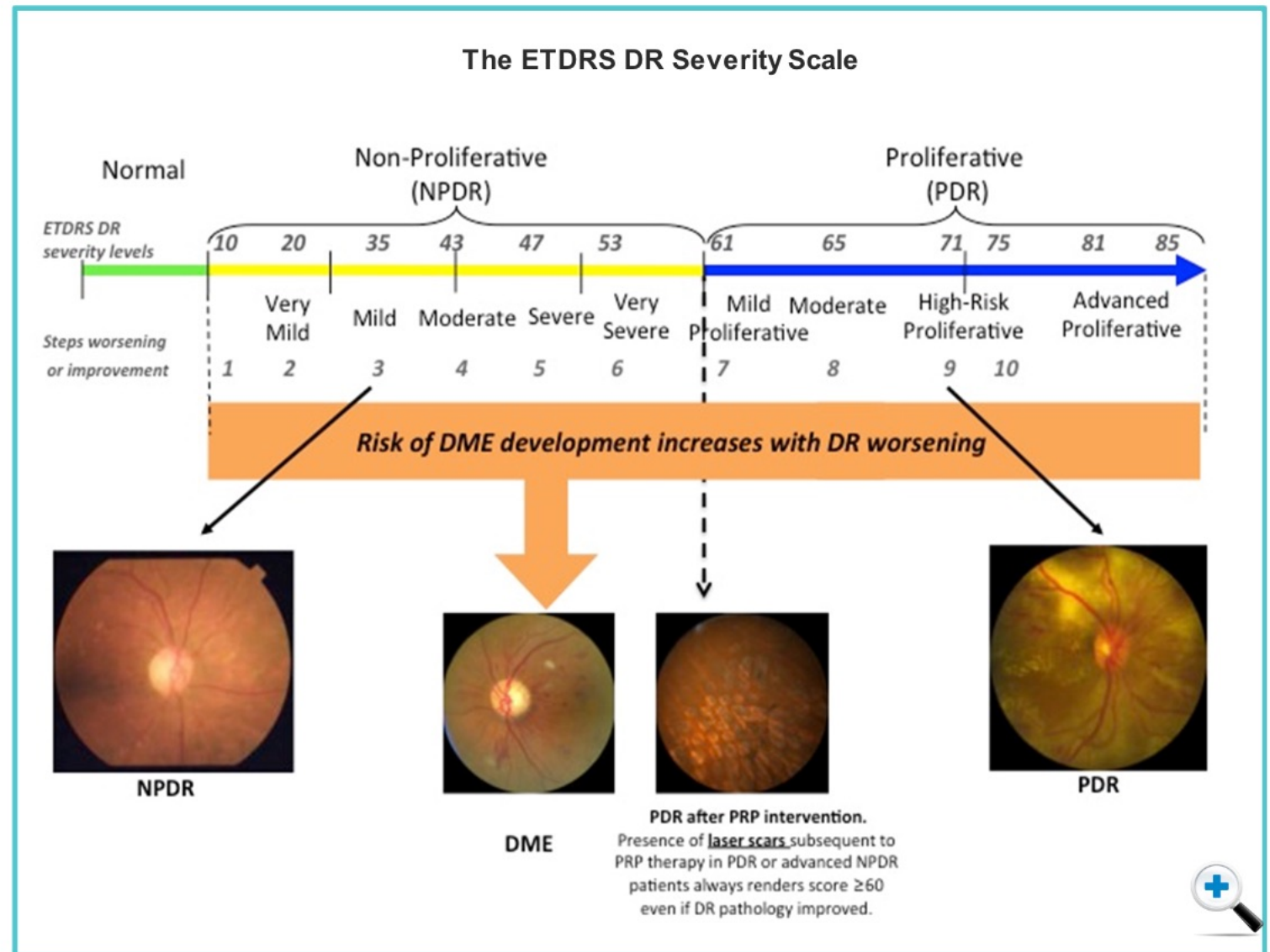
ETDRS Standard photograph 11: Milder of 2 standards for arteriolar narrowing, lower boundary of severe fibrosis.

Severity Scale

The pathophysiological features were plotted by the ETDRS into this severity scale.

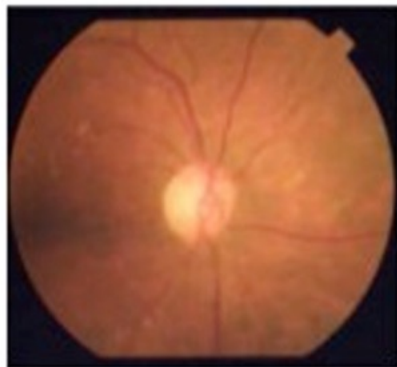
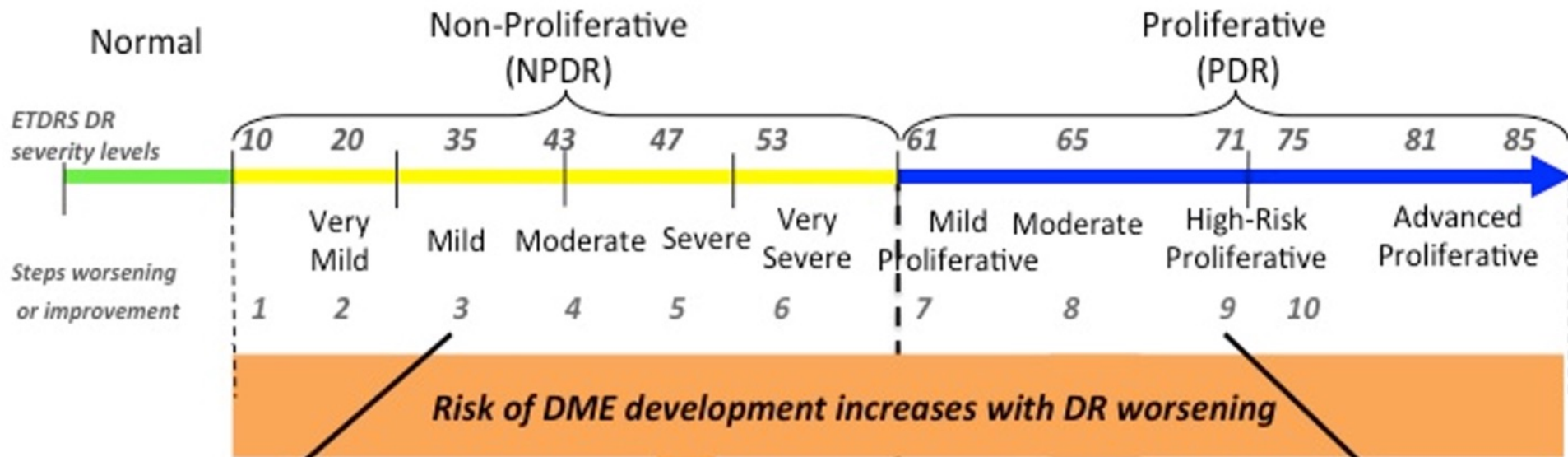
Moving from the left (normal) to right, one can move from lower levels of severity of nonproliferative diabetic retinopathy to very severe levels of proliferative diabetic retinopathy.

The risk of DME increases in correspondence with the severity of diabetic retinopathy.

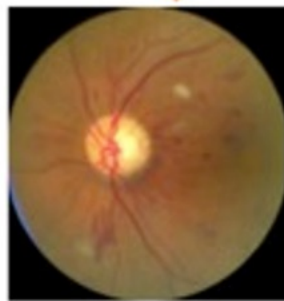



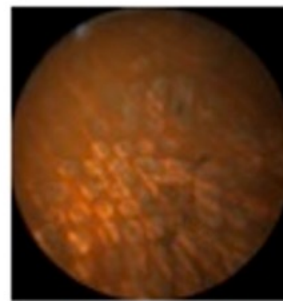
The ETDRS DR Severity Scale



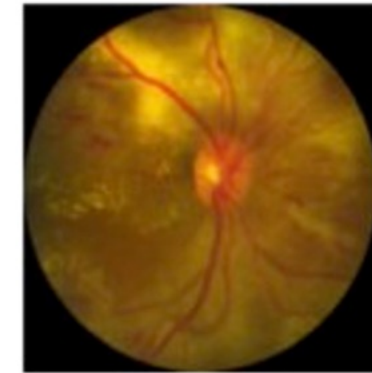
NPDR



DME



PDR after PRP intervention
 Presence of laser scars subsequent to PRP therapy in PDR or advanced NPDR patients always renders score ≥ 60 even if DR pathology appears to be improved



PDR

Imaging for Classification of Diabetic Retinopathy: Quick Quiz

Next, you'll be asked a series of questions about the use of imaging technology to investigate the pathophysiology of diabetic retinopathy and diabetic macular edema.

Don't worry, your answers are not used for assessment. They are intended simply to help you better understand how much you have learned.

After the quiz, you'll get a chance to review your answers, and some advice based on your attempt.



Click the Next button to continue.



Question 1 of 5

Which option best completes this sentence?

The Airlie house, DRS and ETDRS standard photographs...

- classified the development of diabetic eye disease (diabetic retinopathy and diabetic macular edema)
- matched the clinical manifestation of diabetic eye disease to underlying disease processes
- mapped the retina, giving each area a defined name, making it easier to describe the location of retinal changes

Submit

Question 1 of 5

Which option best completes this sentence?

The Airlie house, DRS and ETDRS standard photographs...

- classified the development of diabetic eye disease (diabetic retinopathy and diabetic macular edema)
- matched the clinical manifestation of diabetic eye disease to underlying disease processes
- mapped the retina, giving each area a defined name, making it easier to describe the location of retinal changes

That's right

Airlie house, DRS and ETDRS standard photographs classified the development of diabetic eye disease (diabetic retinopathy and diabetic macular edema).

Continue

Question 3 of 5

On colour fundus photography-based classification systems for diabetic eye disease, why are microaneurysms and haemorrhages grouped together?

- They can't be differentiated on colour fundus images, so are called "H/Ma" (Haemorrhages/Microaneurysms)
- Several studies have shown that their presence (together or individually) presents the same risk for development of DME, so they are treated as the same event for the purpose of risk assessment
- They are a consequence of the same pathophysiological mechanism, so can be considered the same event with regard to the development of diabetic retinopathy

Submit

Question 3 of 5

On colour fundus photography-based classification systems for diabetic eye disease, why are microaneurysms and haemorrhages grouped together?

- They can't be differentiated on colour fundus images, so are called "H/Ma" (Haemorrhages/Microaneurysms)
- Several studies have shown that their presence (together or individually) presents the same risk for development of DME, so they are treated as the same event for the purpose of risk assessment
- They are a single event with

That's right

Haemorrhages and microaneurysms can't be distinguished on colour fundus photography. Therefore, they are often referred to as "H/Ma".

Continue

Question 4 of 5

Standard photographs used in classification systems are used to show (identify 2):

- the key areas of the retina that should be investigated for signs of diabetic eye disease
- the extent (i.e. number) of clinical manifestations for each level of severity in diabetic retinopathy
- the key events in the progression of diabetic retinopathy to the development of diabetic macular edema
- the appearance of clinical manifestations of diabetic retinopathy

That's not it

The use of standard photographs provides an excellent feature-based grading system, showing:

- The appearance of clinical manifestations of diabetic retinopathy
- The extent of these manifestations at each level of severity in diabetic retinopathy

Continue

Question 5 of 5

What is the relationship between the development of diabetic retinopathy and the risk of diabetic macular edema?

- Patients are at highest risk of developing diabetic macular edema early in the development of diabetic retinopathy
- As diabetic retinopathy worsens, the risk for diabetic macular edema increases
- The risk of diabetic macular edema increases with specific features of diabetic retinopathy, but not with others
- The link between diabetic retinopathy and diabetic macular edema is only in the underlying processes - one cannot be used to predict the risk of the other

Submit

Question 5 of 5

What is the relationship between the development of diabetic retinopathy and the risk of diabetic macular edema?

- Patients are at highest risk of developing diabetic macular edema early in the development of diabetic retinopathy
- As diabetic retinopathy worsens, the risk for diabetic macular edema increases
- The risk of diabetic macular edema increases with specific features of diabetic retinopathy, but not with others
- The link between the two is complex and one cannot predict the risk of developing macular edema based on the severity of retinopathy

That's right

As diabetic retinopathy worsens, the risk for developing diabetic macular edema increases.

Continue

Module Progress:

Welcome ✓

Imaging for Classification of DR ✓

Imaging Pathophysiology of DR & DME

Summary

Knowledge Check

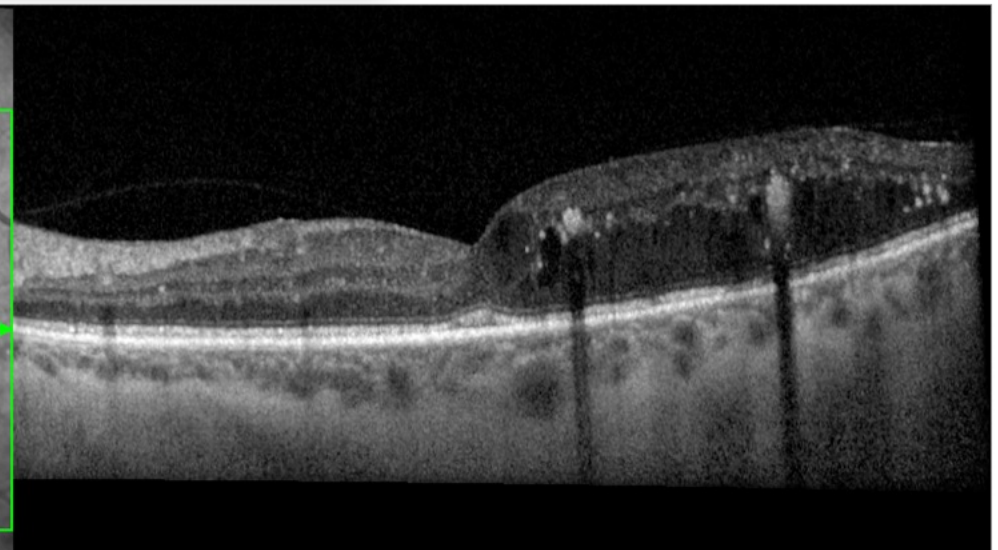
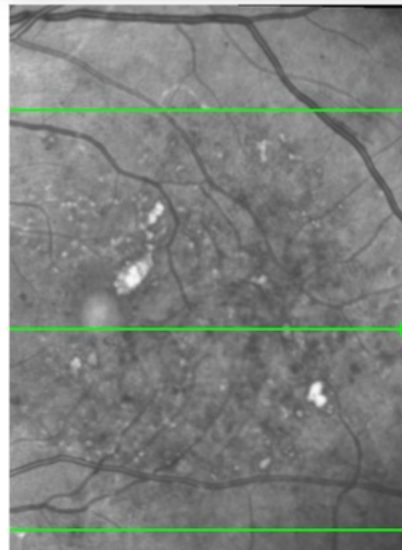
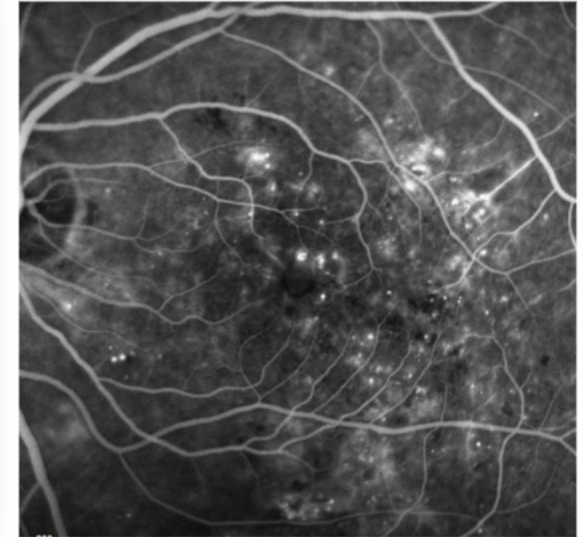
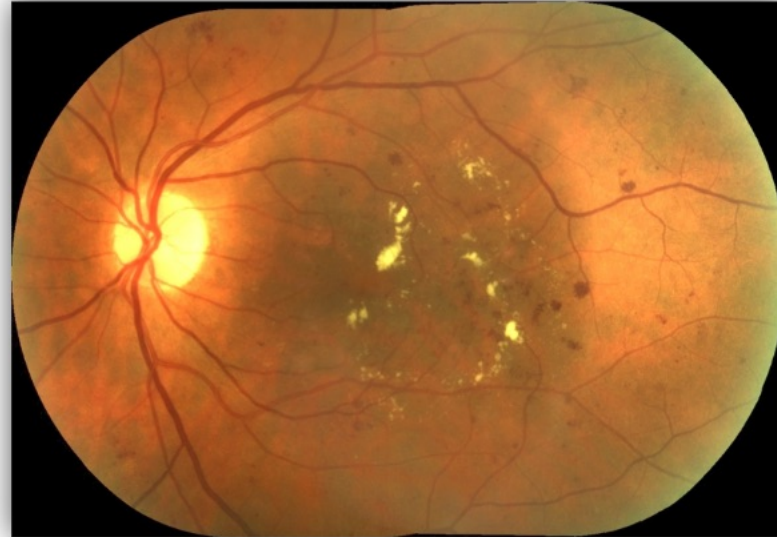Imaging Pathophysiology of DR & DME

Introduction

While classification and grading systems have been very useful in monitoring diabetic eye disease and assessing risk of progression, they show us the clinical manifestation of underlying pathophysiological processes.

In the age of multimodal imaging, these pathophysiological processes can be viewed directly, using:

- **Fundus fluorescein angiography** to see changes to vasculature
- **Optical coherence tomography (OCT)** to see changes to retinal architecture
- **Comparison between these and colour fundus imaging** to better understand the phenomena being seen on each



Colour Fundus Photography vs FFA



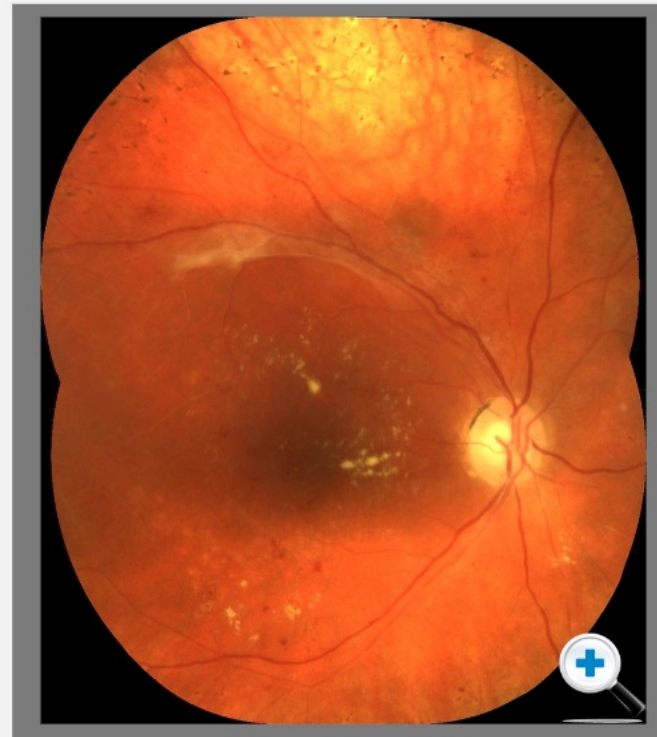
Use the arrows to scroll through examples of the clinical features before you answer the question

Colour Fundus Photography

This montage colour fundus photograph shows several features of diabetic retinopathy.



Click image to enlarge.



Next, we will look at optical coherence tomography. Can you remember the key benefit of OCT over colour fundus and FFA?

- You can view 2 dimensional retinal architecture
- You can view choroidal blood flow

Submit

Colour Fundus Photography vs FFA



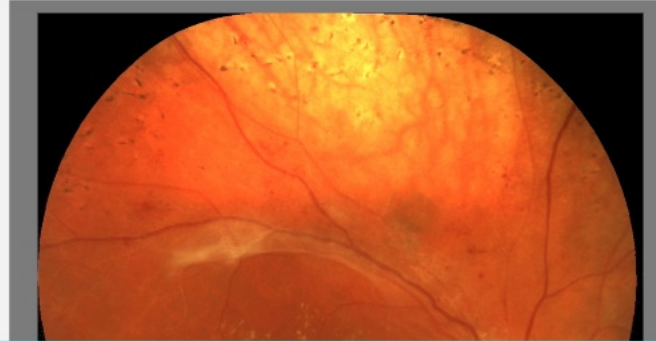
Use the arrows to scroll through examples of the clinical features before you answer the question

Colour Fundus Photography

This montage colour fundus photograph shows several features of diabetic retinopathy.



Click image to enlarge.



That's right

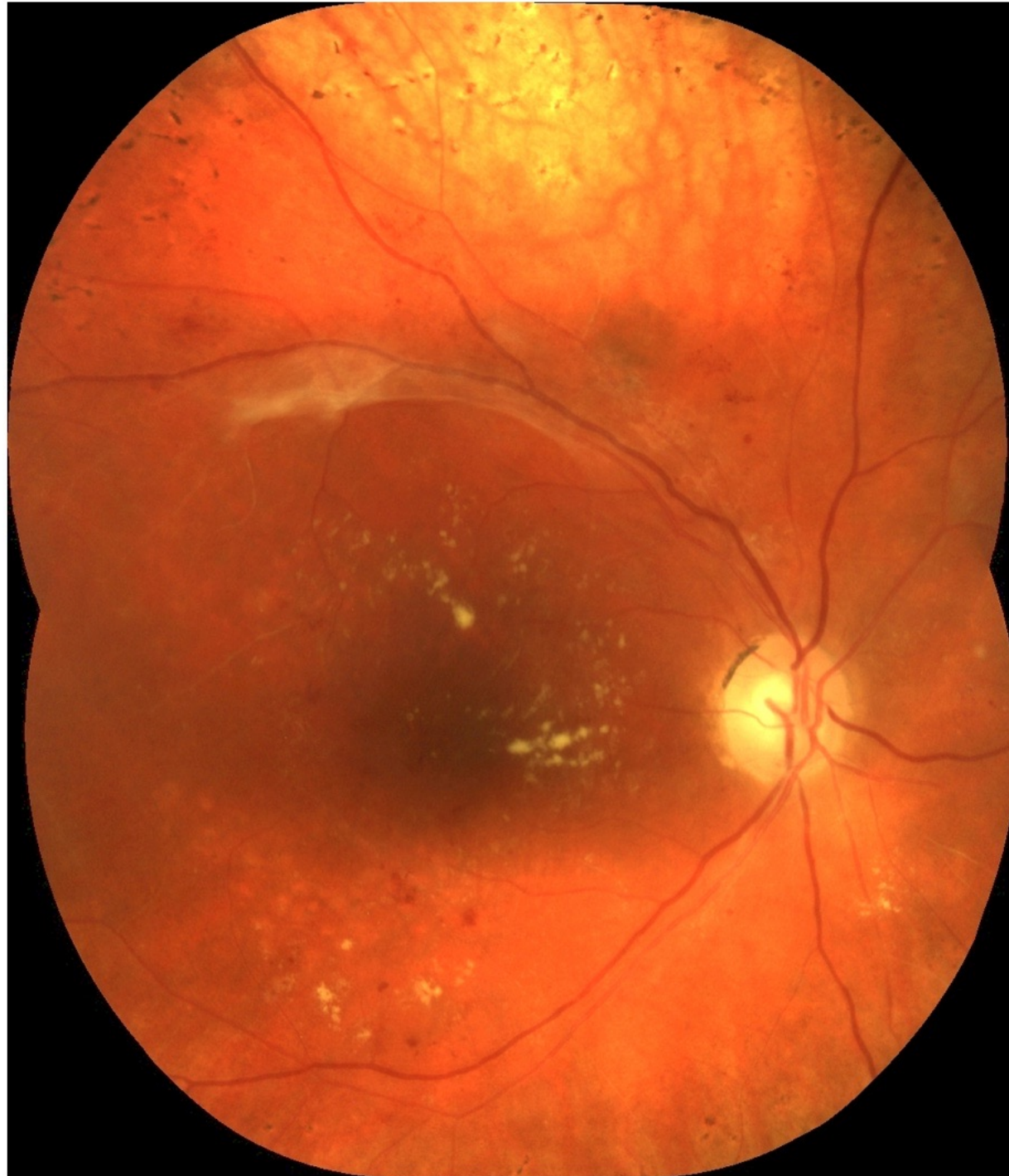With OCT, one can image 2 dimensional retinal architecture. This offers a great deal of information and detail about disease processes.

Next, we will look at o
tomography. Can you
of OCT over colour fu

hitecture

Close

Montage Colour Fundus Photograph Showing Features of Diabetic Retinopathy



Colour Fundus Photography vs FFA




Use the arrows to scroll through examples of the clinical features before you answer the question

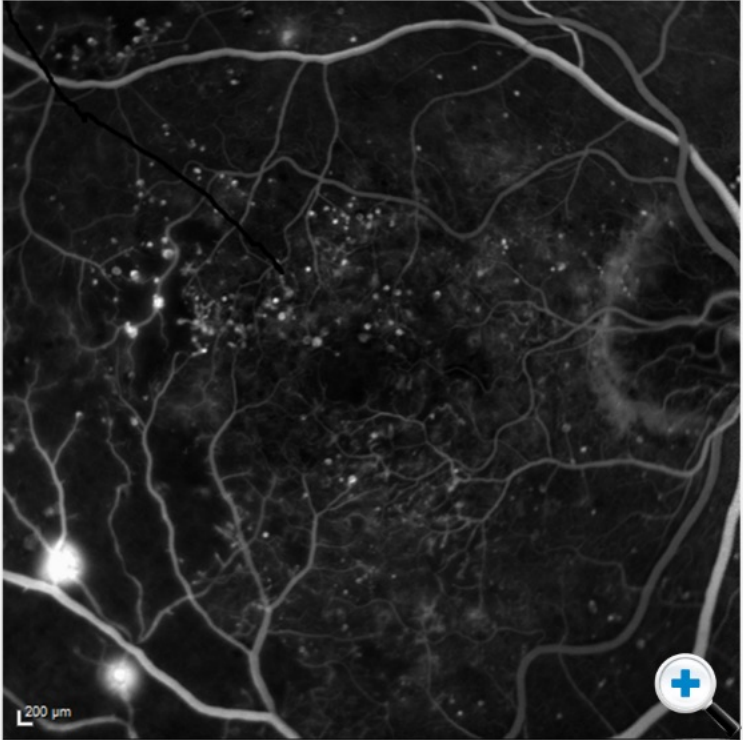
Fluorescein Angiography

With fluorescein angiography, a lot more detail is available.

Changes in vascular caliber	Microaneurysms
Areas of capillary non-perfusion	IRMA
Areas of capillary leakage	New/ shunt vessel formation

 Tap image to enlarge and explore details.

○ ● ○



200 μm

<

>


Next, we will look at optical coherence tomography. Can you remember the key benefit of OCT over colour fundus and FFA?

- You can view 2 dimensional retinal architecture
- You can view choroidal blood flow

Submit

Fluorescein Angiography



 *Hover over the listed characteristics to see them indicated on the image.*

Changes in vascular caliber

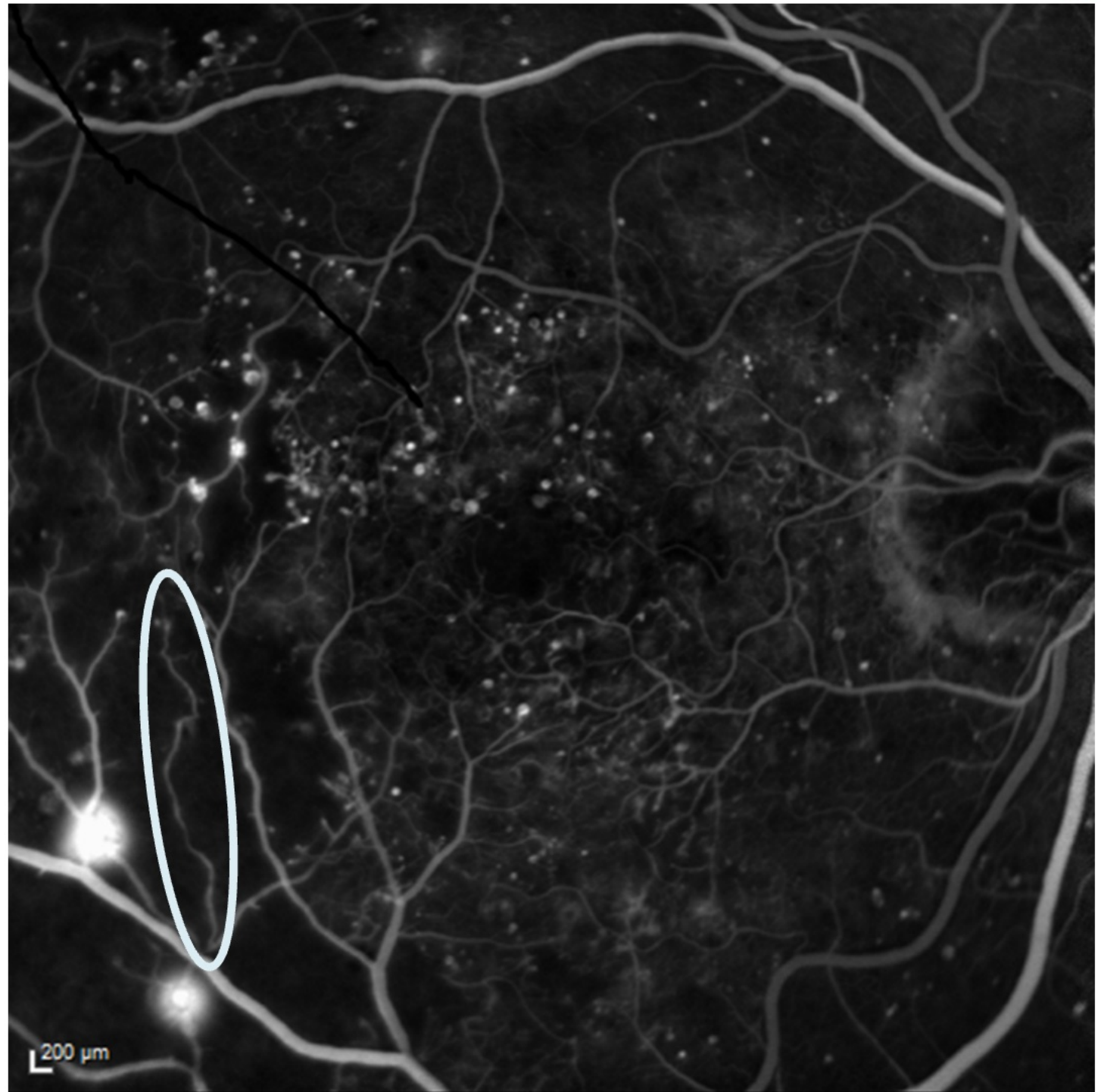
Areas of capillary non-perfusion

Areas of capillary leakage


Microaneurysms lighting up out-pouchings

Intraretinal microvascular abnormalities (IRMA)

New vessel and shunt vessel formation



Fluorescein Angiography

 *Hover over the listed characteristics to see them indicated on the image.*

Changes in vascular caliber

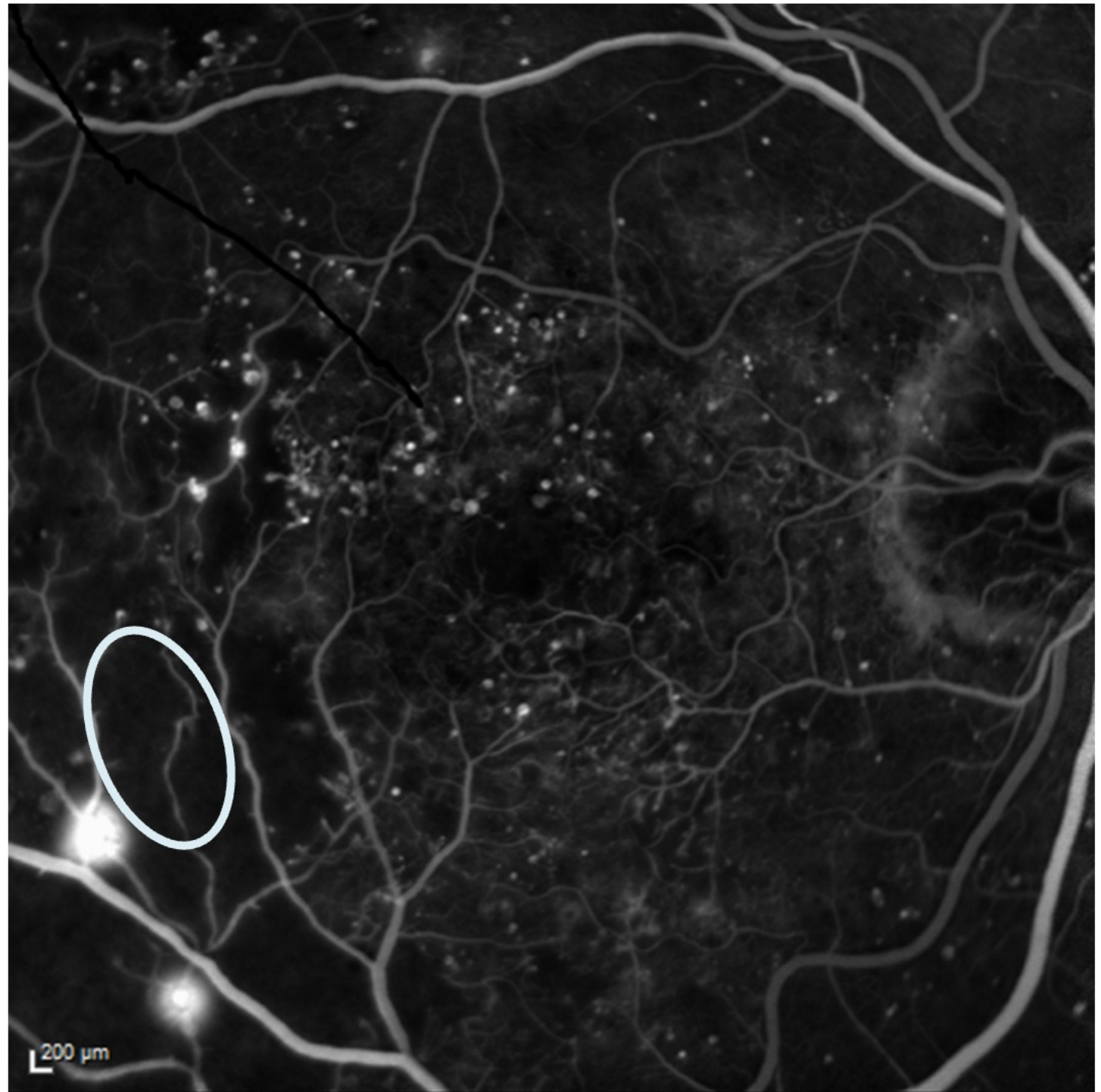
Areas of capillary non-perfusion

Areas of capillary leakage


Microaneurysms lighting up out-pouchings

Intraretinal microvascular abnormalities (IRMA)

New vessel and shunt vessel formation



Fluorescein Angiography

 *Hover over the listed characteristics to see them indicated on the image.*

Changes in vascular caliber

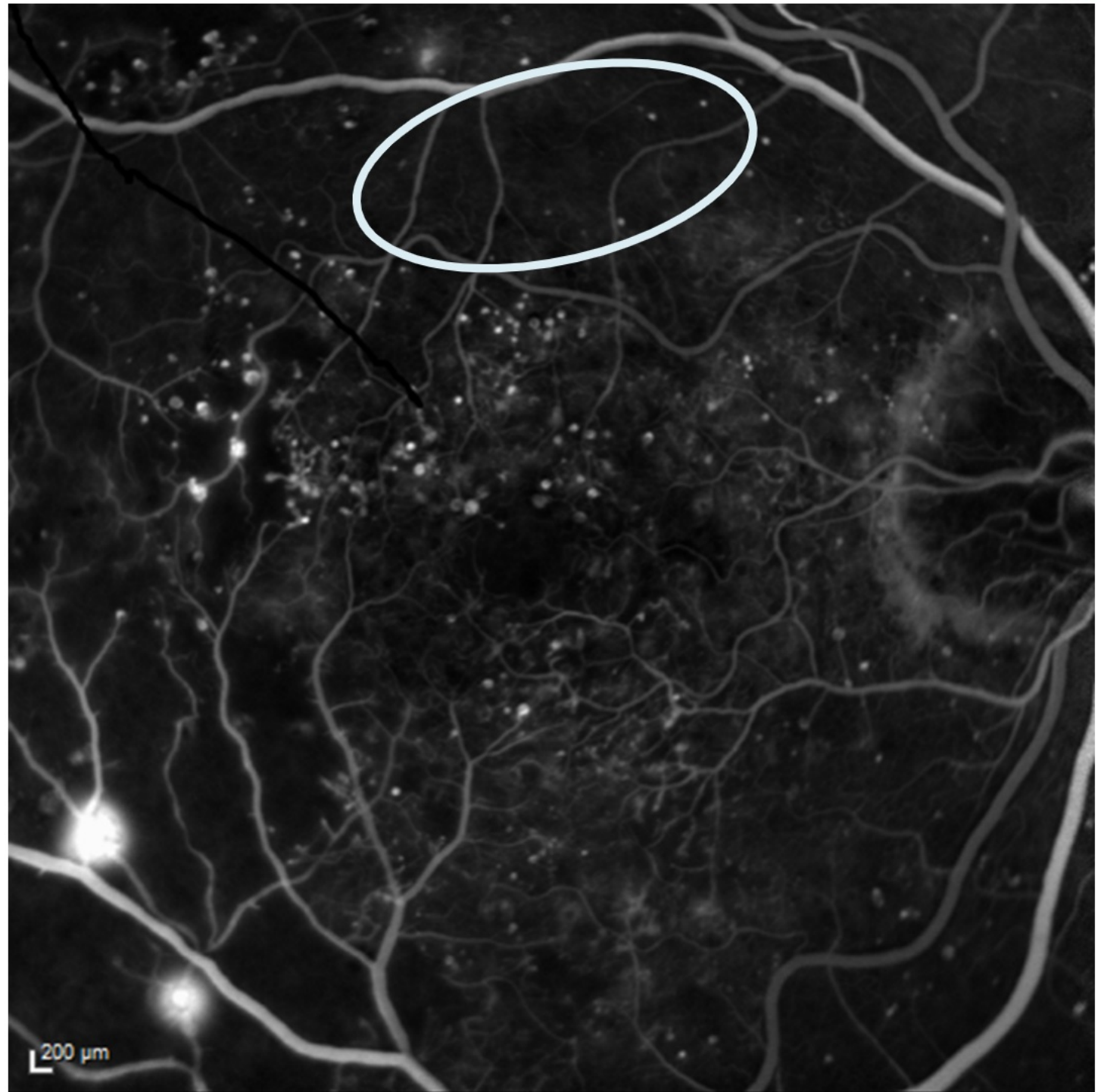
Areas of capillary non-perfusion

Areas of capillary leakage

Microaneurysms lighting up out-pouchings


Intraretinal microvascular abnormalities (IRMA)

New vessel and shunt vessel formation



Fluorescein Angiography



 *Hover over the listed characteristics to see them indicated on the image.*

Changes in vascular caliber

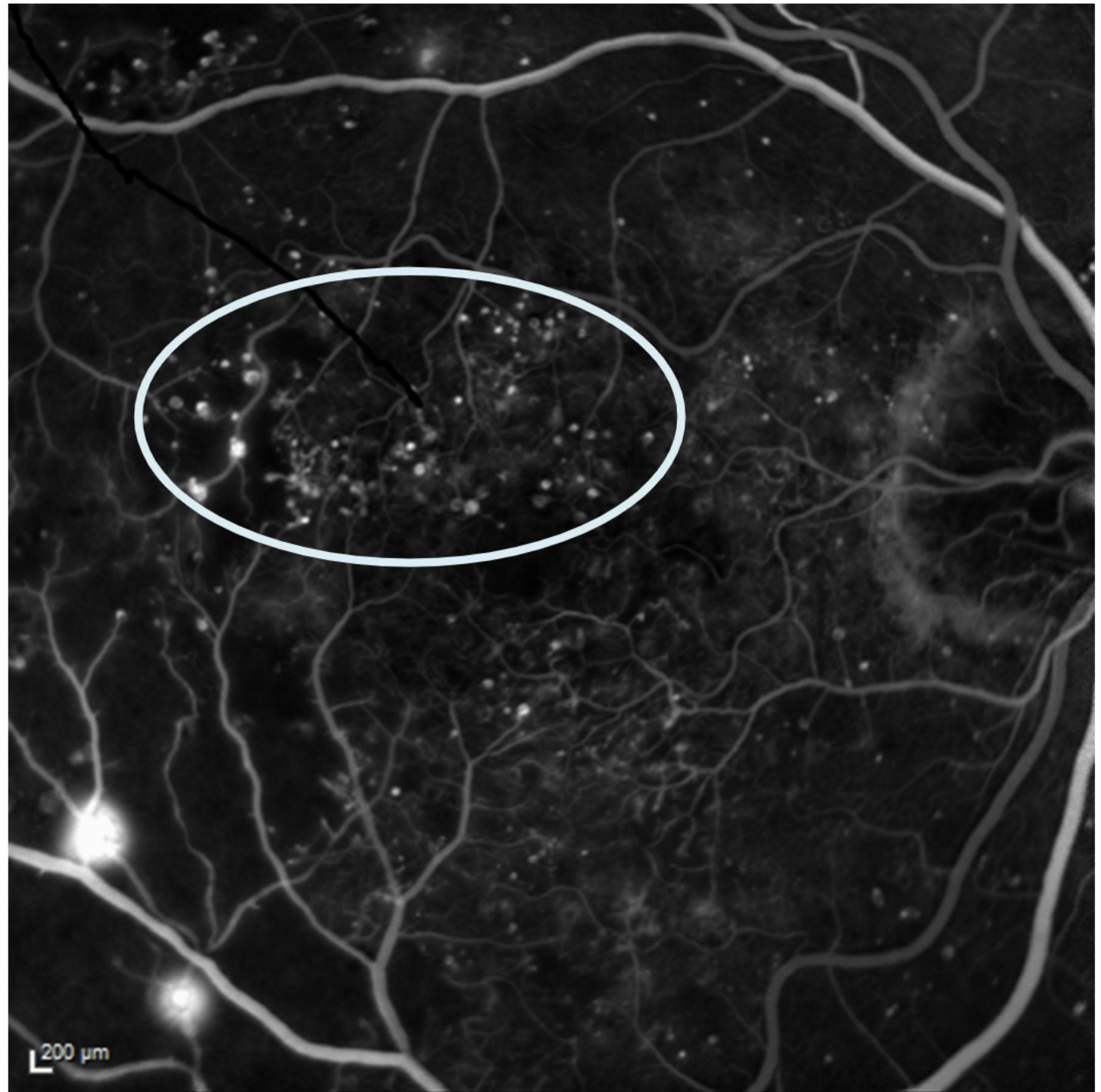
Areas of capillary non-perfusion

Areas of capillary leakage


Microaneurysms lighting up out-pouchings

Intraretinal microvascular abnormalities (IRMA)

New vessel and shunt vessel formation



Fluorescein Angiography

 *Hover over the listed characteristics to see them indicated on the image.*

Changes in vascular caliber

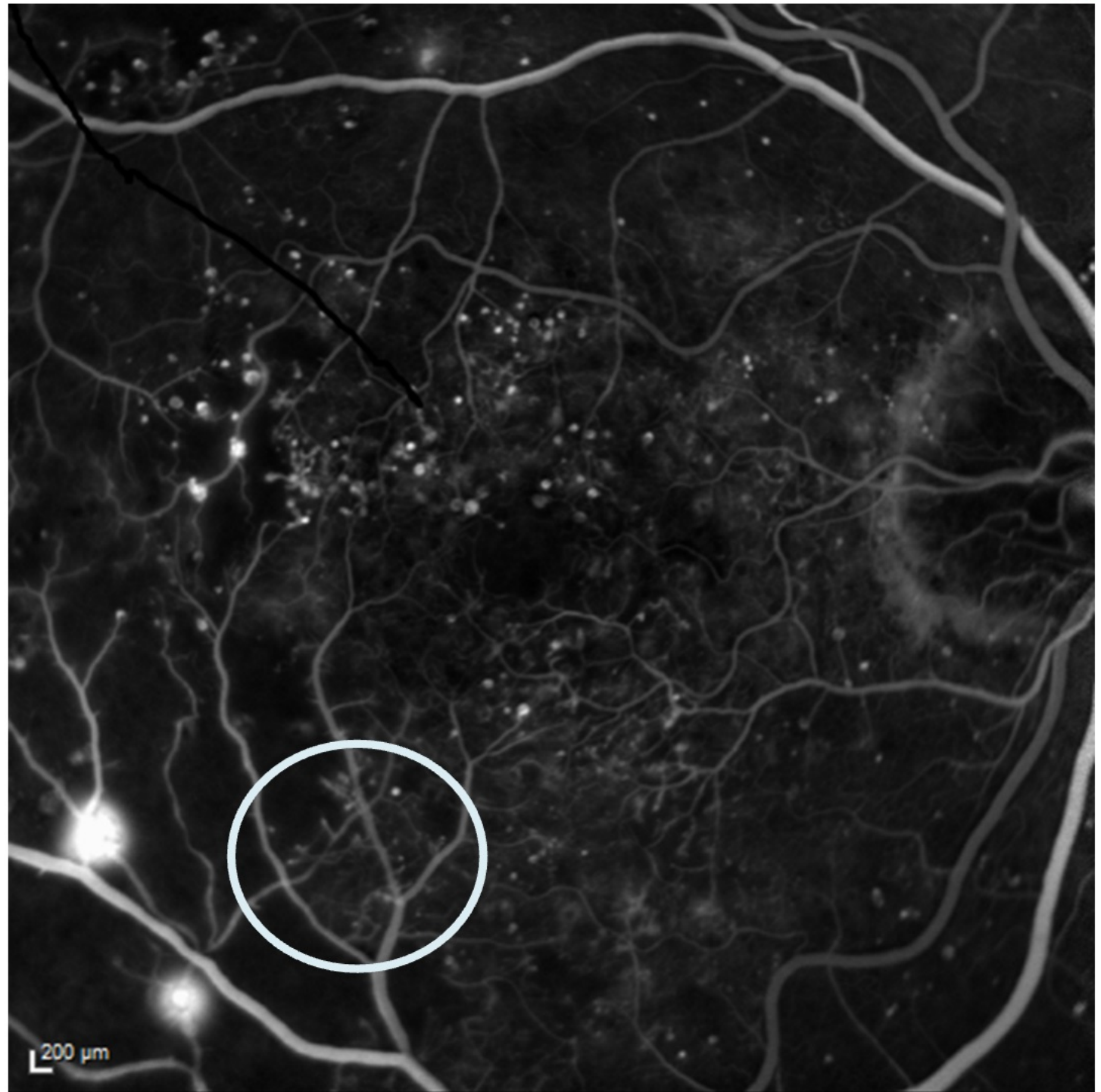
Areas of capillary non-perfusion

Areas of capillary leakage

Microaneurysms lighting up out-pouchings


Intraretinal microvascular abnormalities (IRMA)

New vessel and shunt vessel formation



Fluorescein Angiography



 *Hover over the listed characteristics to see them indicated on the image.*

Changes in vascular caliber

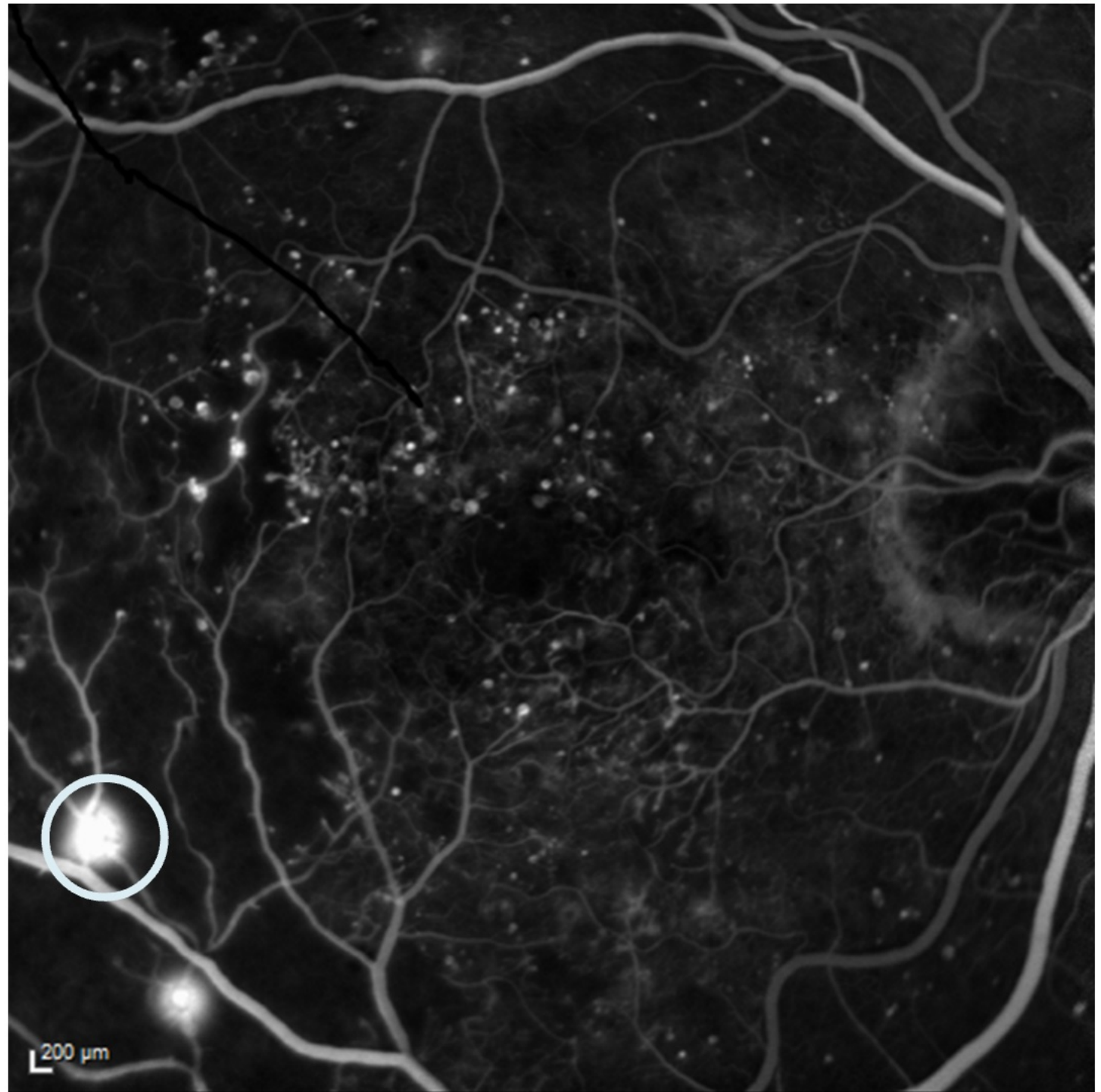
Areas of capillary non-perfusion

Areas of capillary leakage

Microaneurysms lighting up out-pouchings

Intraretinal microvascular abnormalities (IRMA)

New vessel and shunt vessel formation



Colour Fundus Photography vs FFA



Use the arrows to scroll through examples of the clinical features before you answer the question

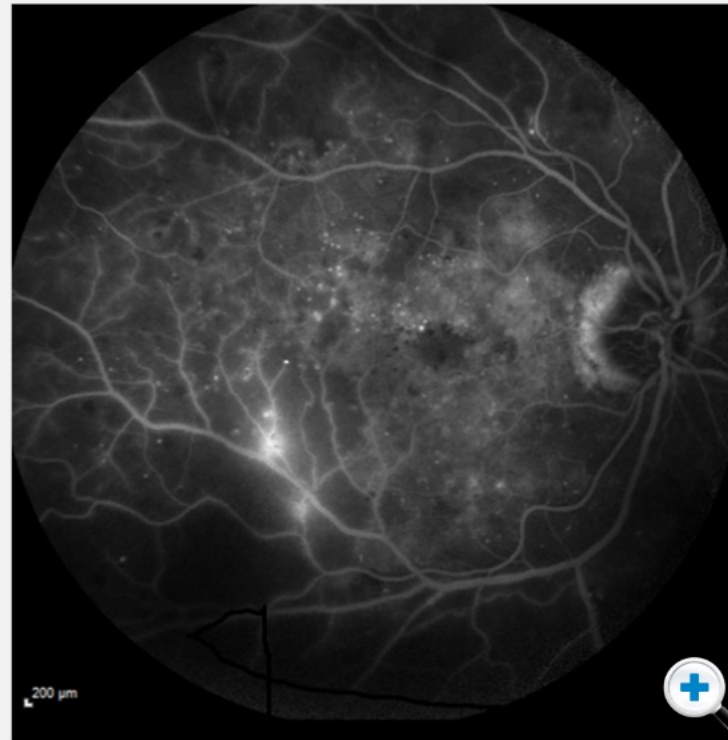
Fluorescein Angiography

Fluorescein angiography is dynamic and will show expanding areas of leakage of dye.

In this example, there is severe macular edema, because the blood-retinal barrier has broken down.



Click image to enlarge and explore the detail.

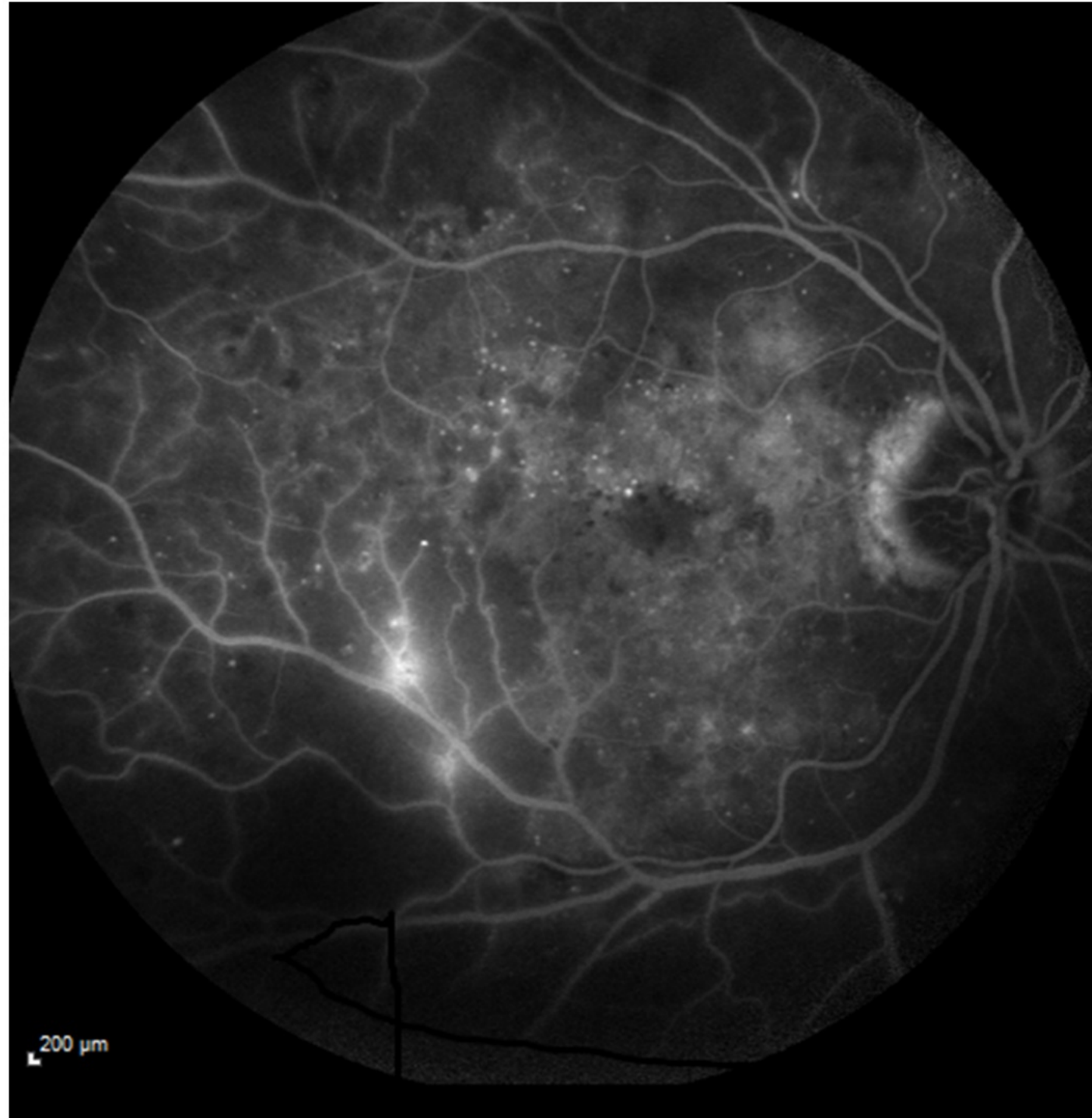


Next, we will look at optical coherence tomography. Can you remember the key benefit of OCT over colour fundus and FFA?

- You can view 2 dimensional retinal architecture
- You can view choroidal blood flow

Submit

Fluorescein Angiography



200 μm

Colour Fundus Photography vs OCT

Cases like this can be seen with colour fundus photography.

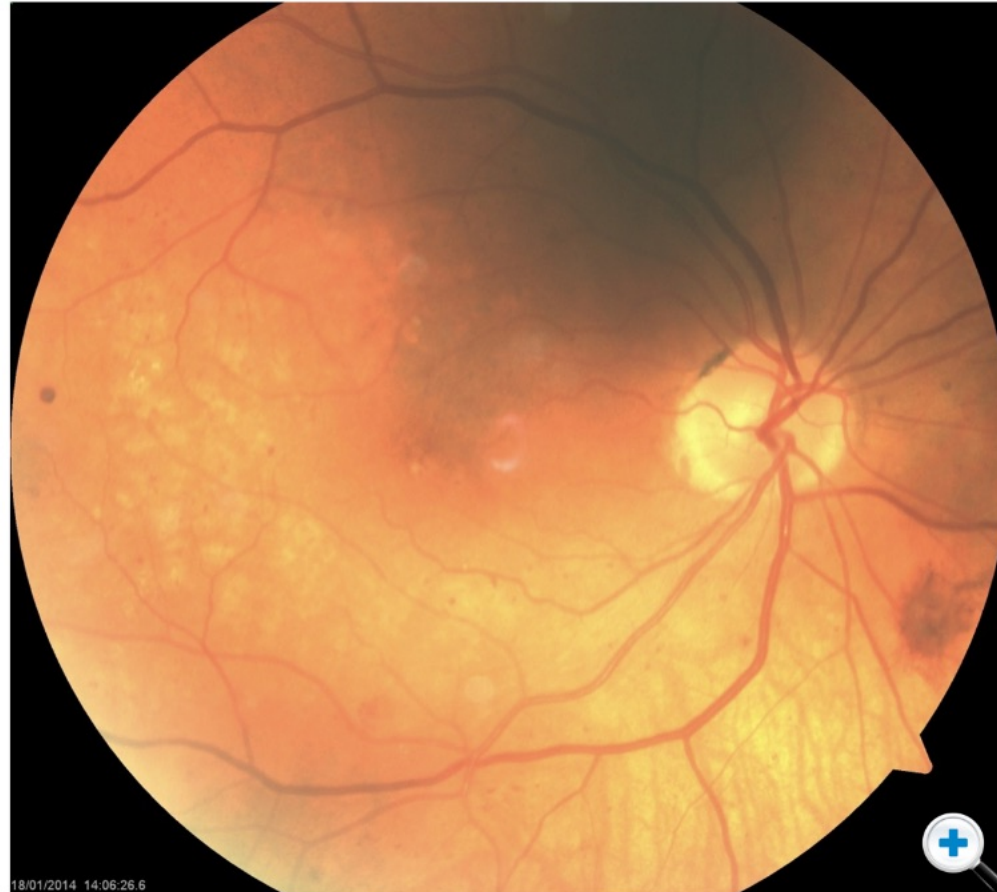One might use a stereoscopic examination to determine whether the retina is elevated.

But it is difficult to determine: ***is there macular edema?***



Tap Check OCT to find out...

Check OCT >



Colour Fundus Photography vs OCT

Cases like this can be seen with colour fundus photography.

One might use a stereoscopic examination to determine whether the retina is elevated.

But it is difficult to determine: ***is there macular edema?***

 Tap Check OCT to find out...

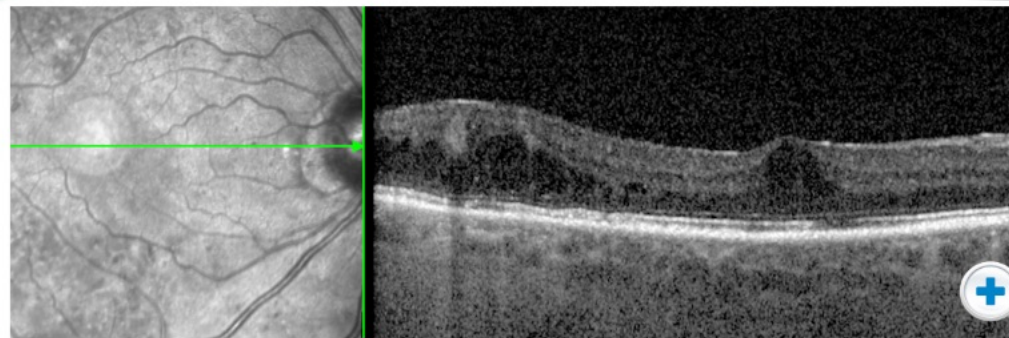
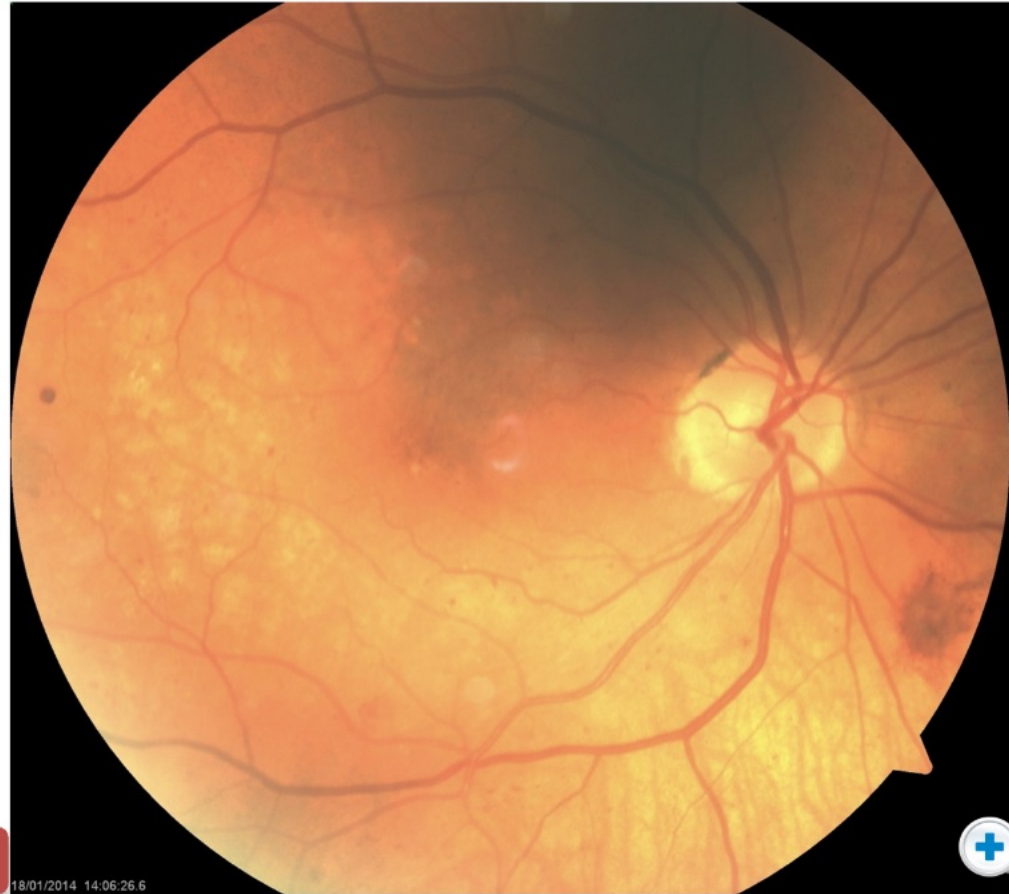Check OCT >

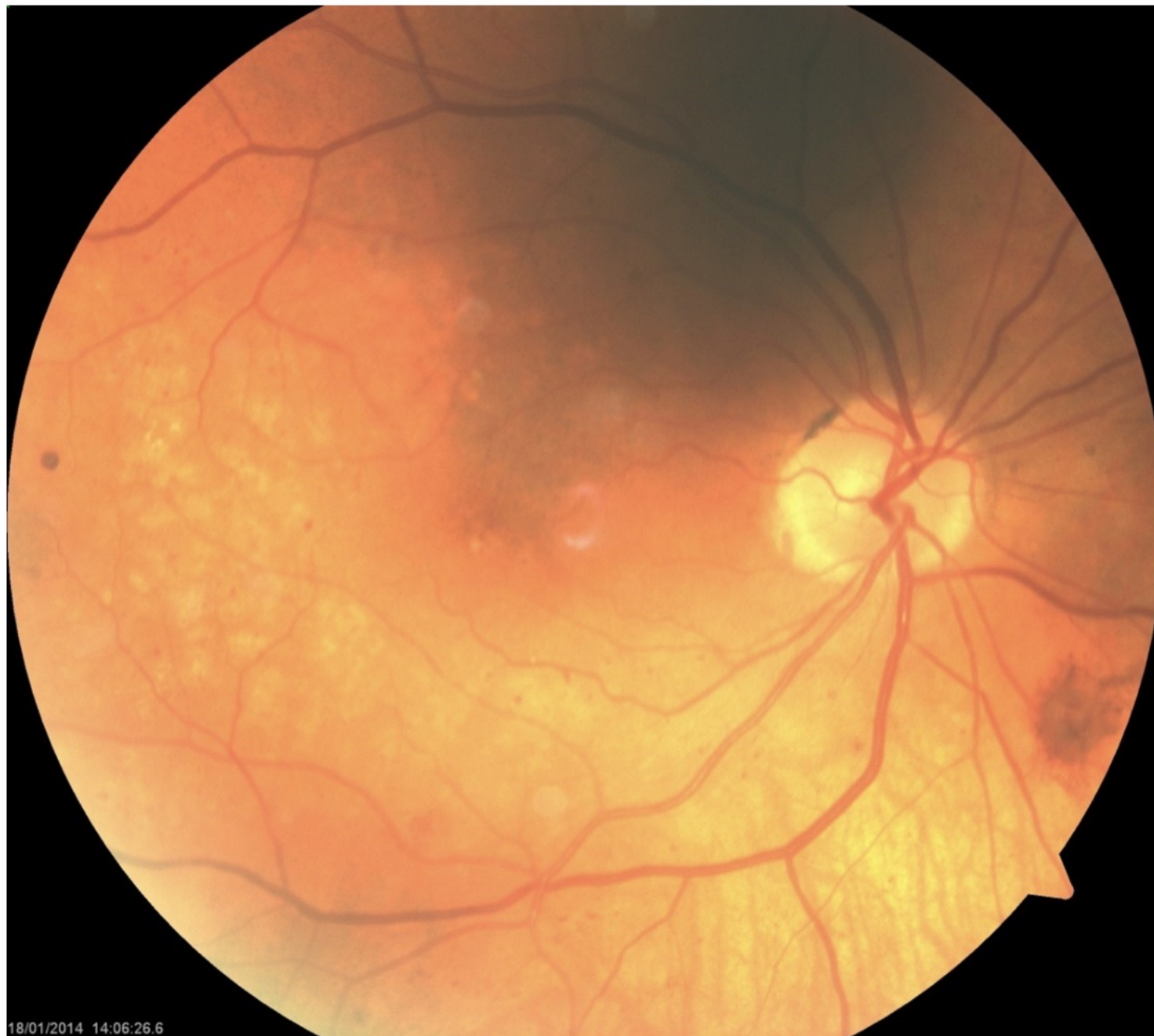< Hide OCT

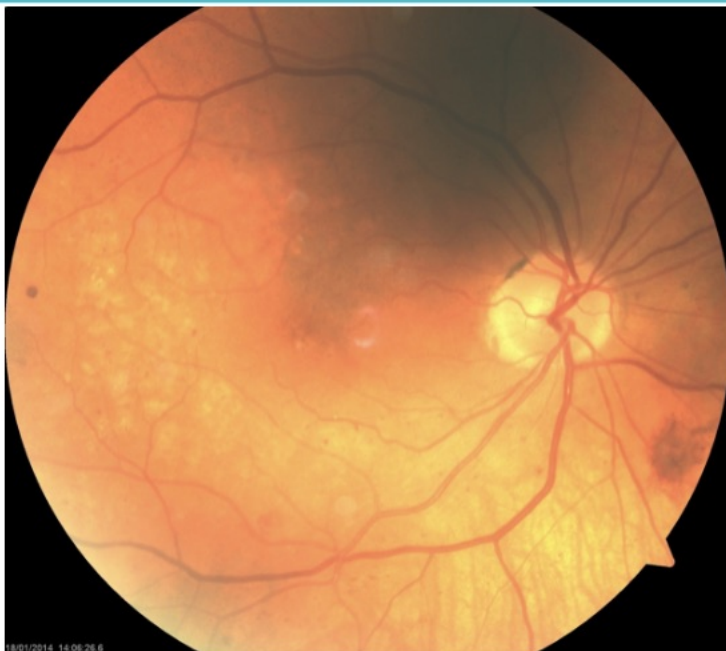With OCT, the 2 dimensional architecture of the retina can be imaged.

This allows you to see the edema directly.

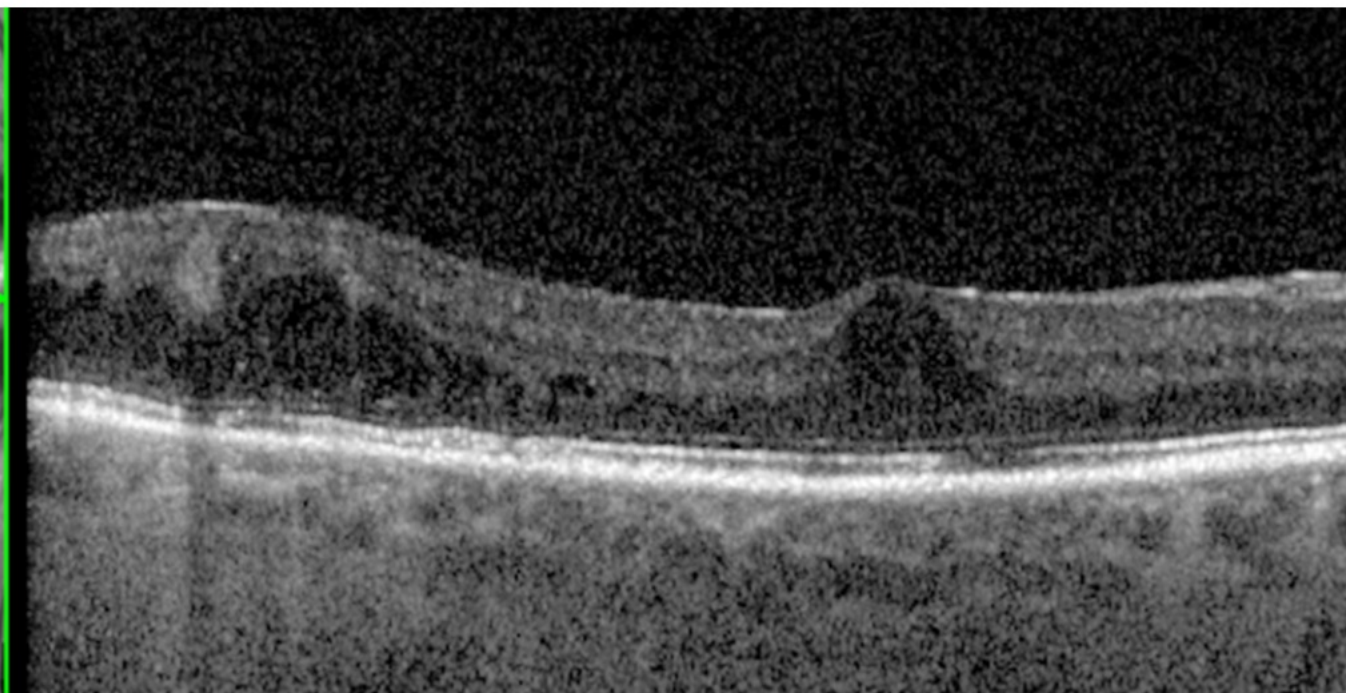
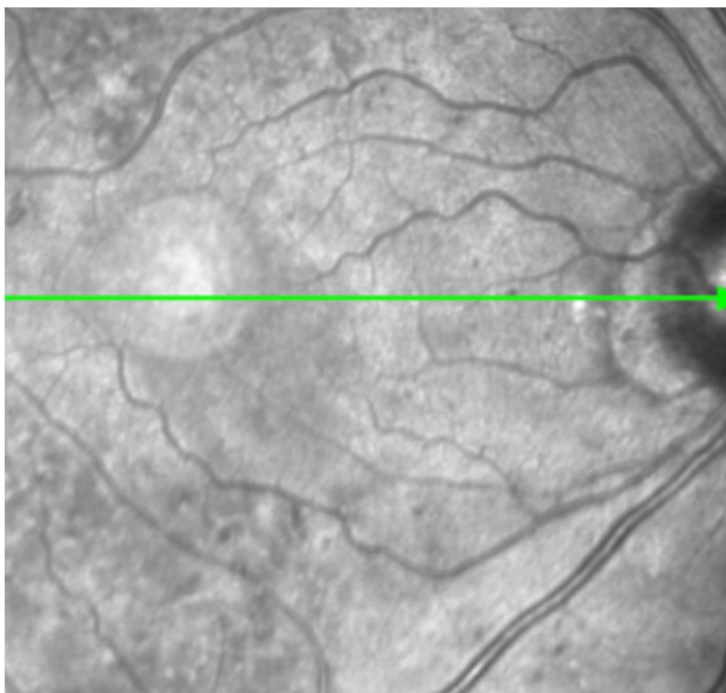
 Click images to enlarge





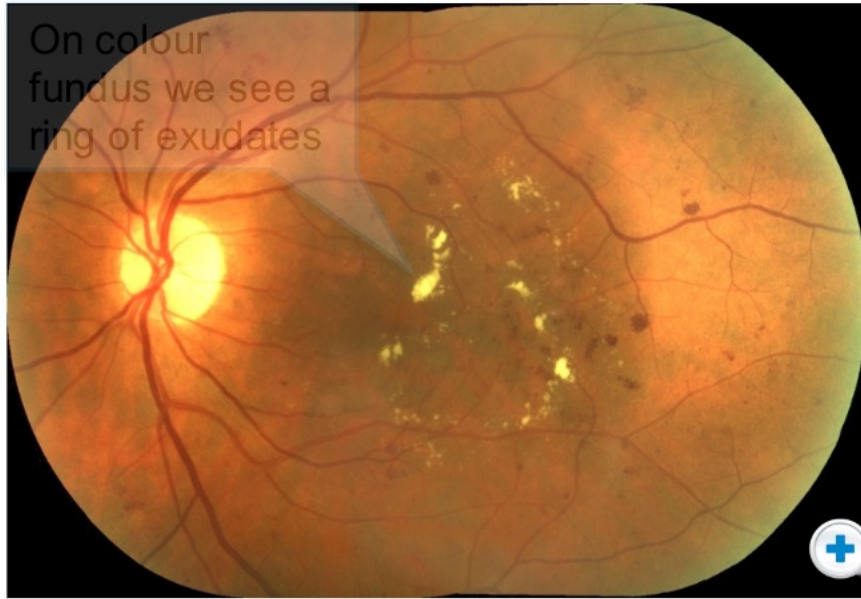


With OCT, the 2 dimensional architecture of the retina can be imaged.
This allows you to see the edema directly.

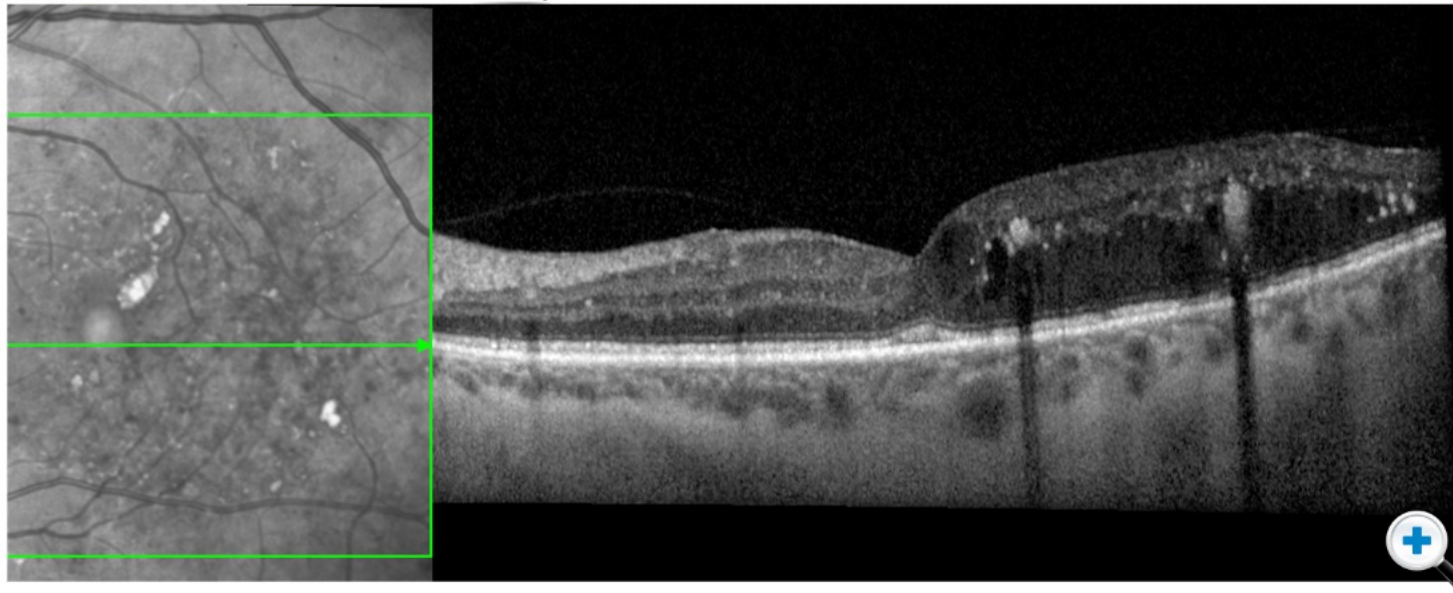
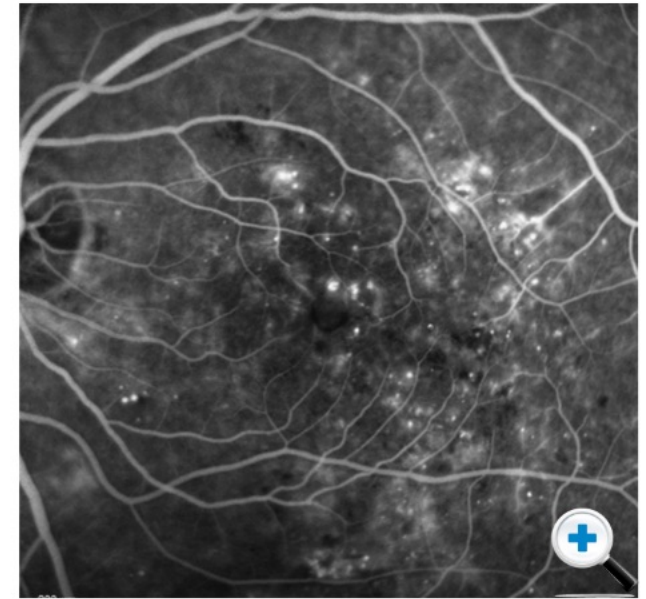


Exudates, Haemorrhages & Edema

These images illustrate how each imaging modality can build up a picture of what is happening at the retina:

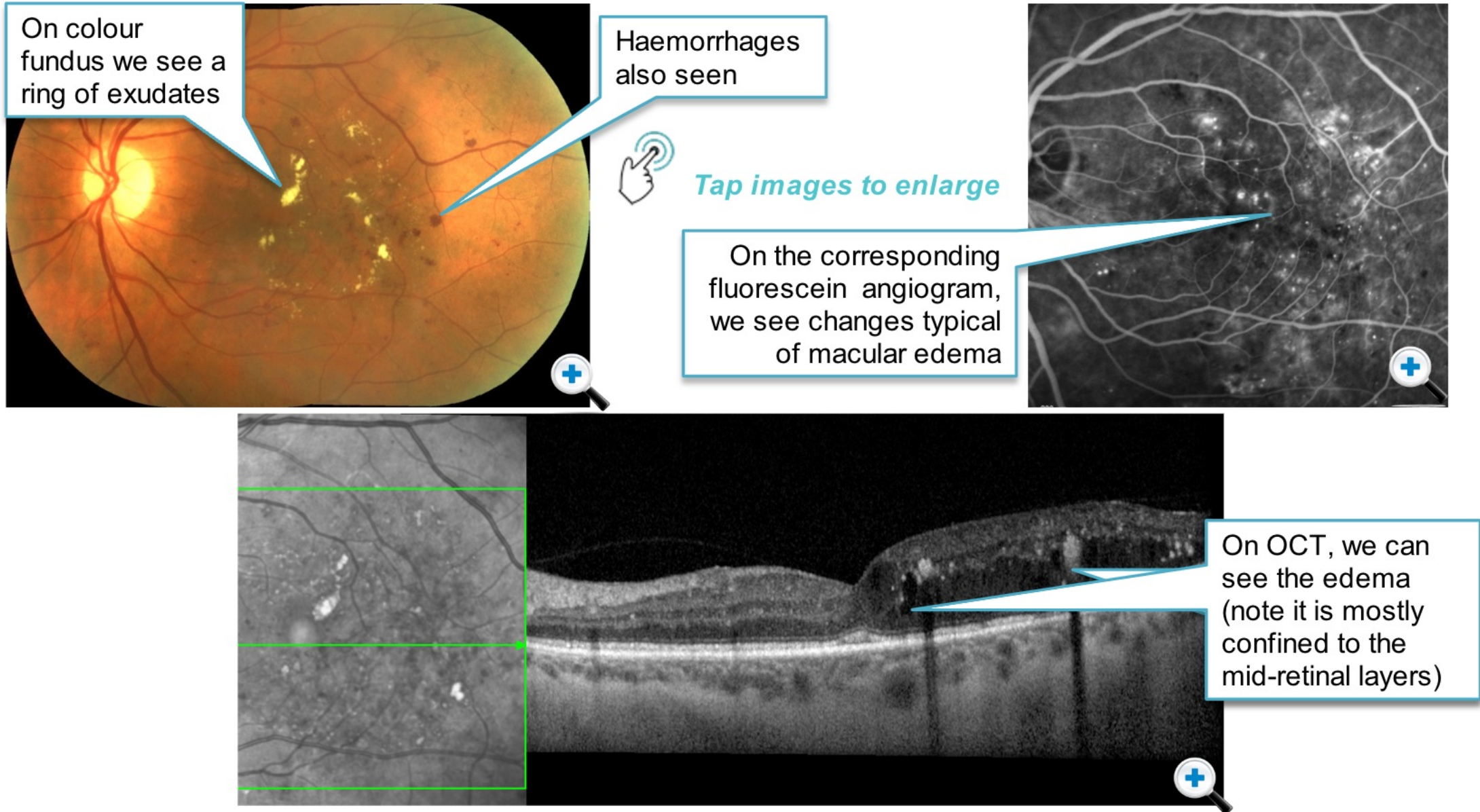


Tap images to enlarge



Exudates, Haemorrhages & Edema

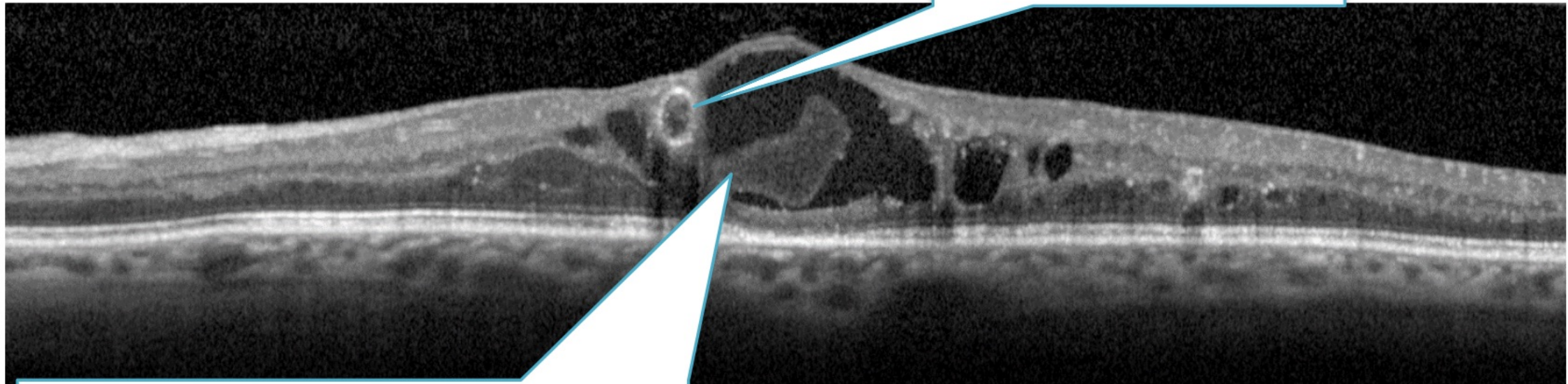
These images illustrate how each imaging modality can build up a picture of what is happening at the retina:



Microaneurysms & Lipid Deposits

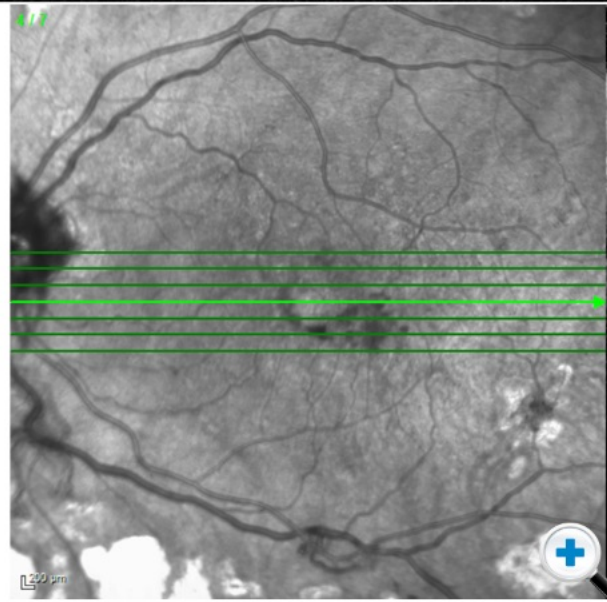
This example shows us microaneurysms and lipid deposits

Microaneurysms here look like almost perfect circles



Homogenous, but diffuse hyperreflectivity indicating turbid fluid containing lipid and protein.

Breakdown of the BRB can take the form of haemorrhage (whole blood), focal areas of lipid (which look whitish or yellowish on colour), and dense homogeneous proteinaceous fluid - best seen on OCT.



Click images to enlarge

Edema, Deposits, Outer Retina Structures

Click the tabs below to explore some of the other features visible using OCT.

Edema

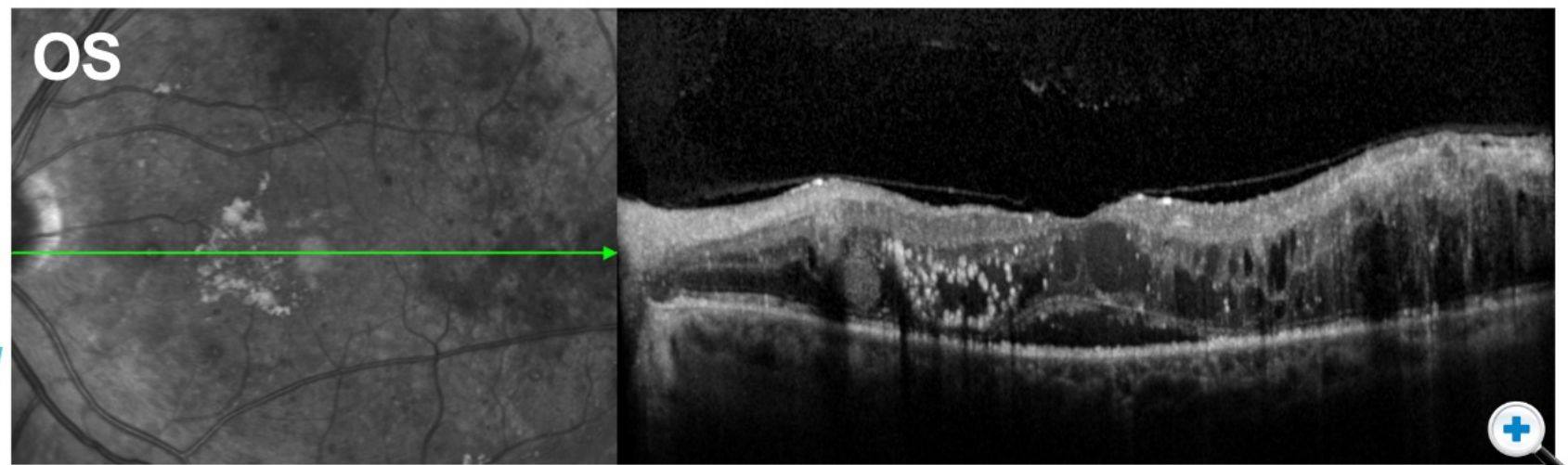
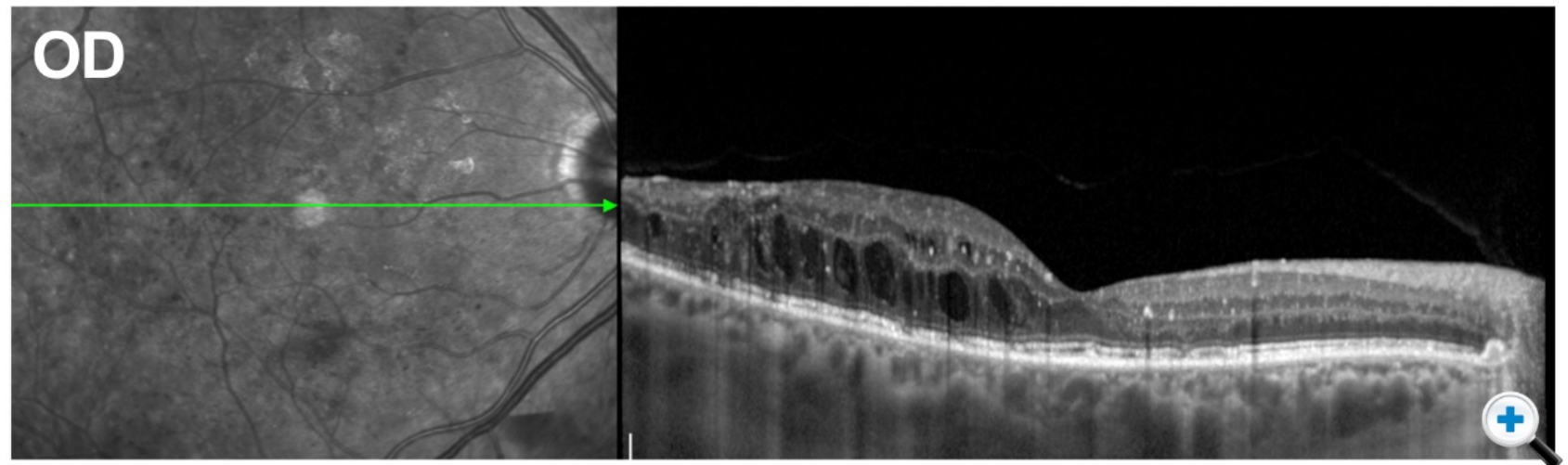
Exudates

Outer Retina Structures

Functional Correlates



Click the tabs to explore more of the features visible using OCT.



Edema, Deposits, Outer Retina Structures

Click the tabs below to explore some of the other features visible using OCT.

Close

Edema

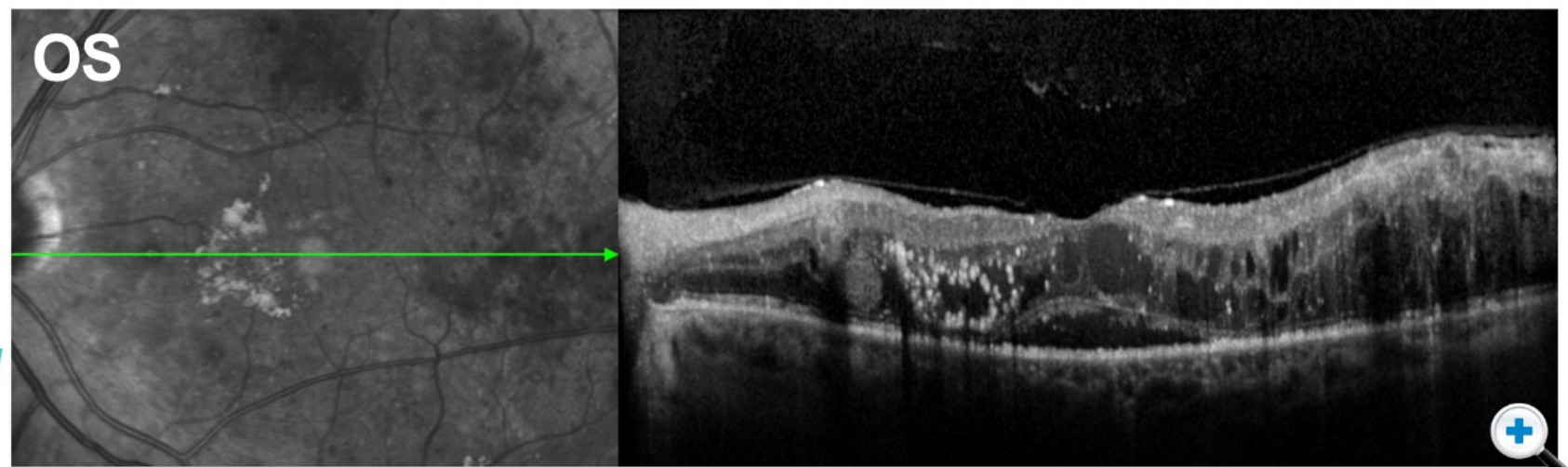
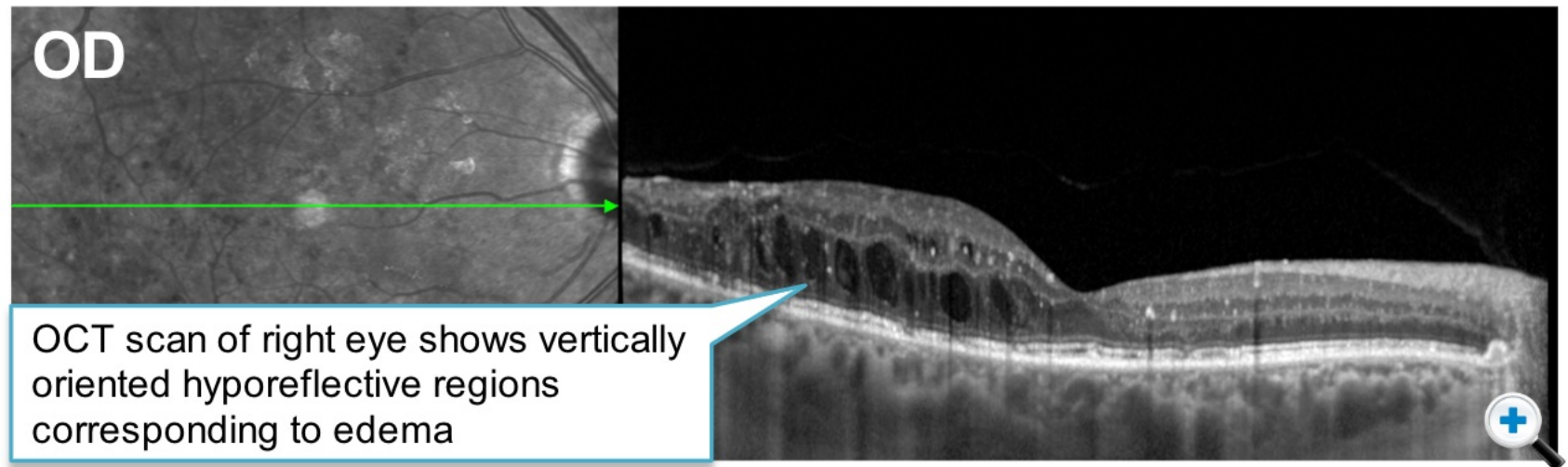
Exudates

Outer Retina Structures

Functional Correlates



Click the tabs to explore more of the features visible using OCT.



Edema, Deposits, Outer Retina Structures

Click the tabs below to explore some of the other features visible using OCT.

Close

Edema

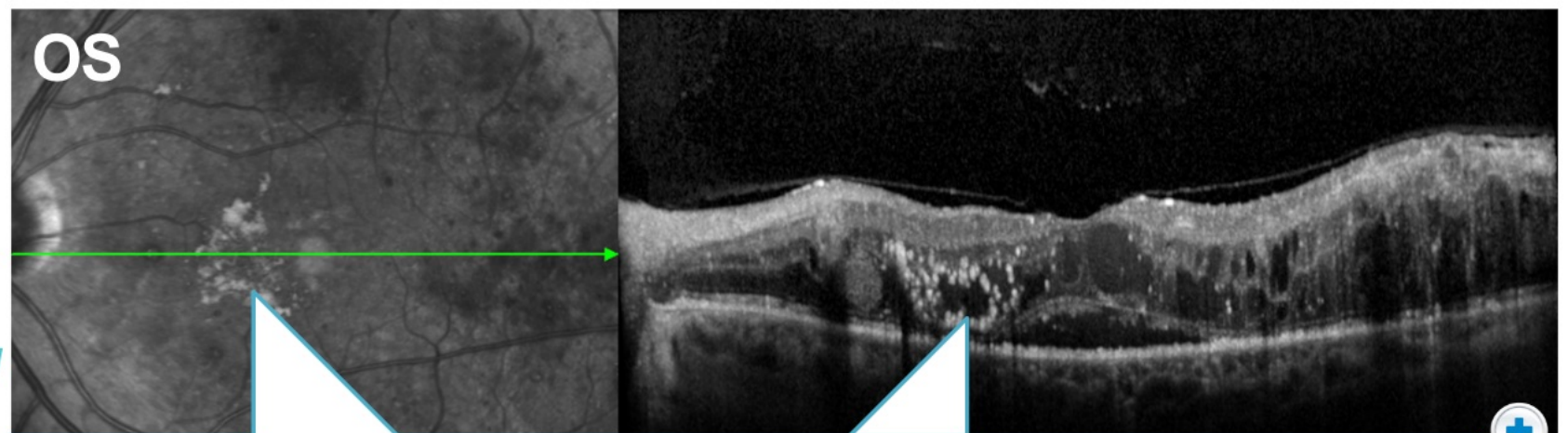
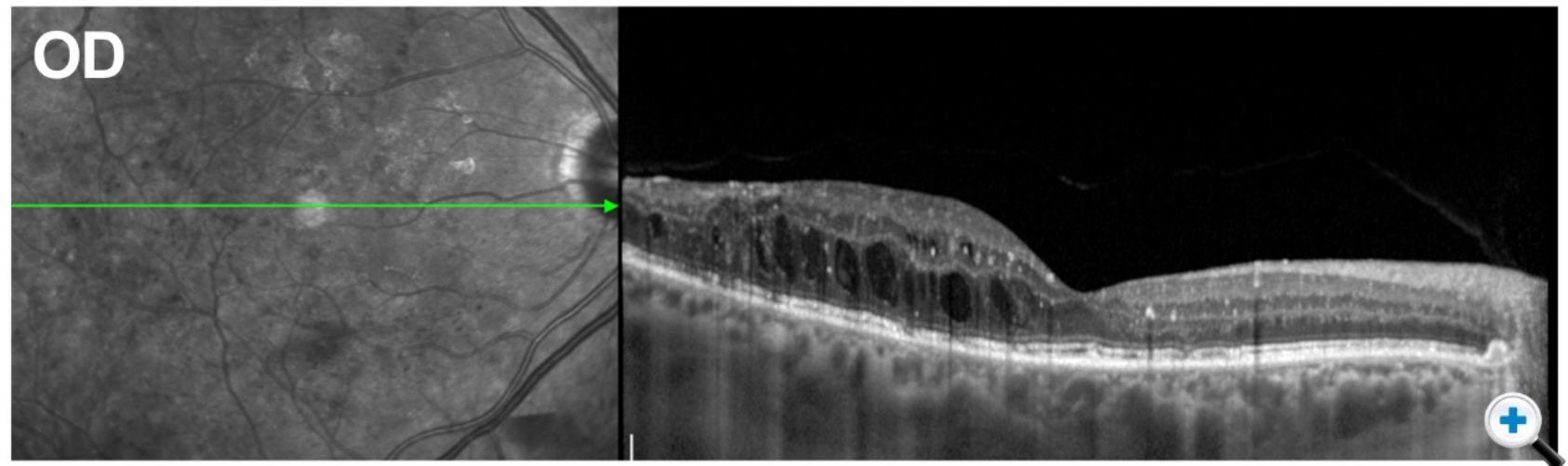
Exudates

Outer Retina Structures

Functional Correlates



Click the tabs to explore more of the features visible using OCT.



In the **left eye**, exudates are seen as hyperreflective areas, often associated with large number of microaneurysms or intraretinal microvascular abnormalities nearby.

Edema, Deposits, Outer Retina Structures

Click the tabs below to explore some of the other features visible using OCT.

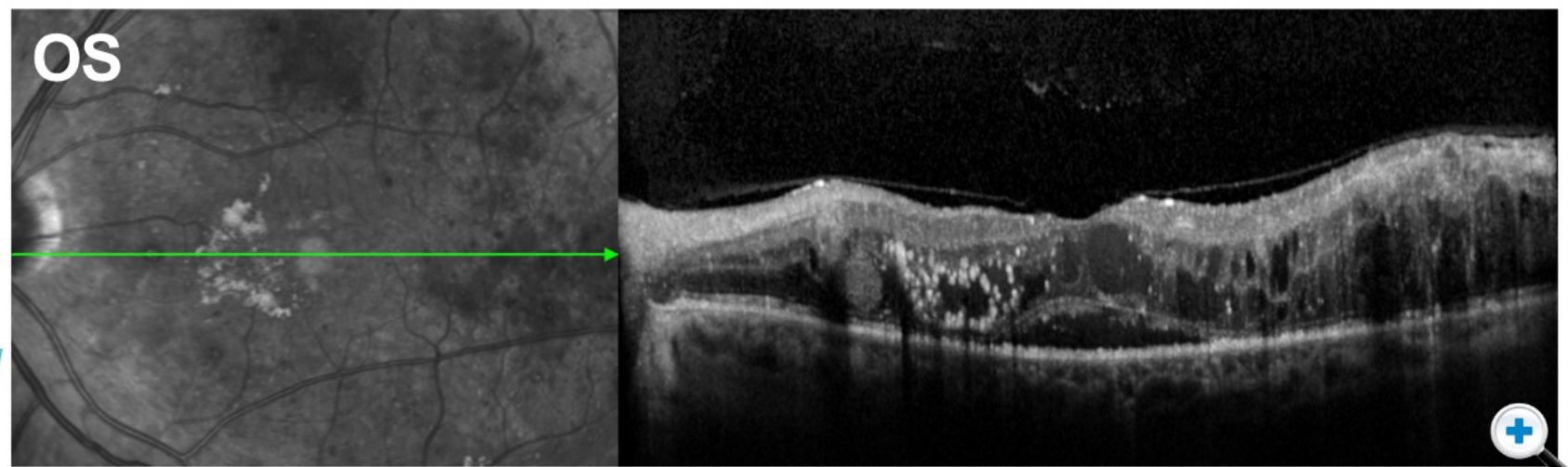
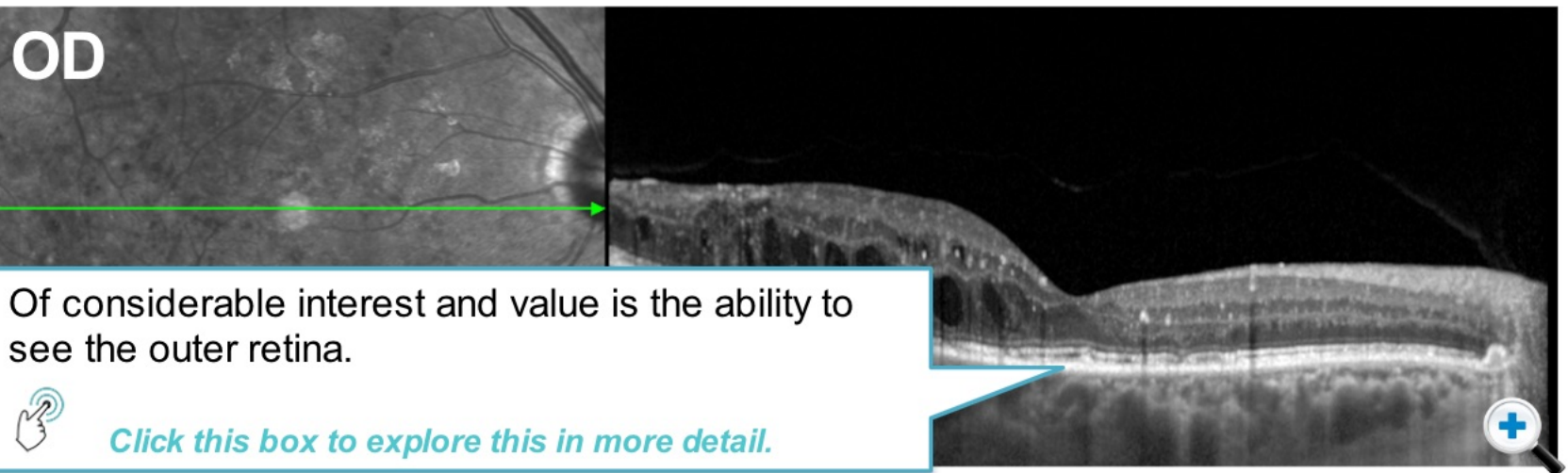
Close


Edema

Exudates

Outer Retina Structures

Functional Correlates



 [Click the tabs to explore more of the features visible using OCT.](#)

Edema, Deposits, Outer Retina Structures

Click the tabs below to explore some of the other features visible using OCT.

Close

Edema

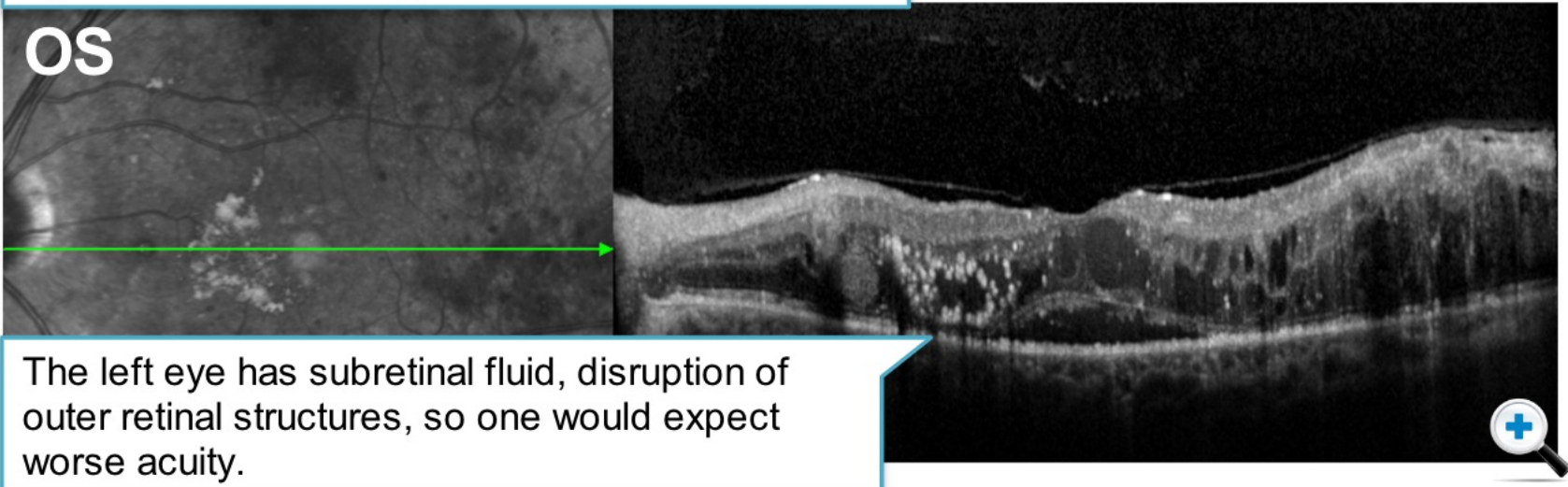
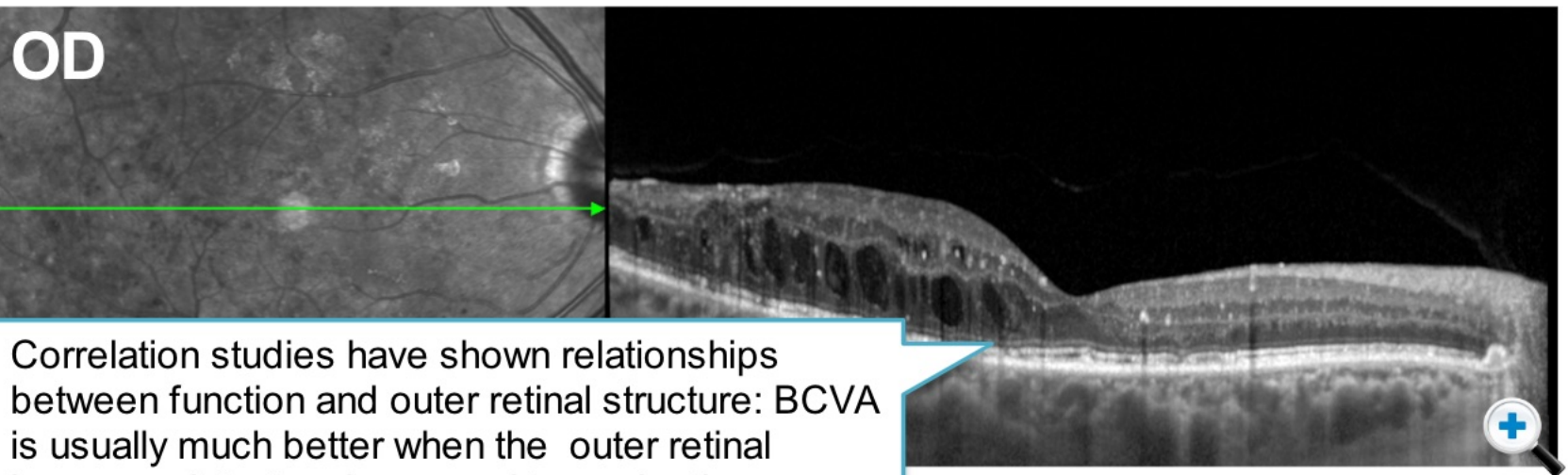
Exudates

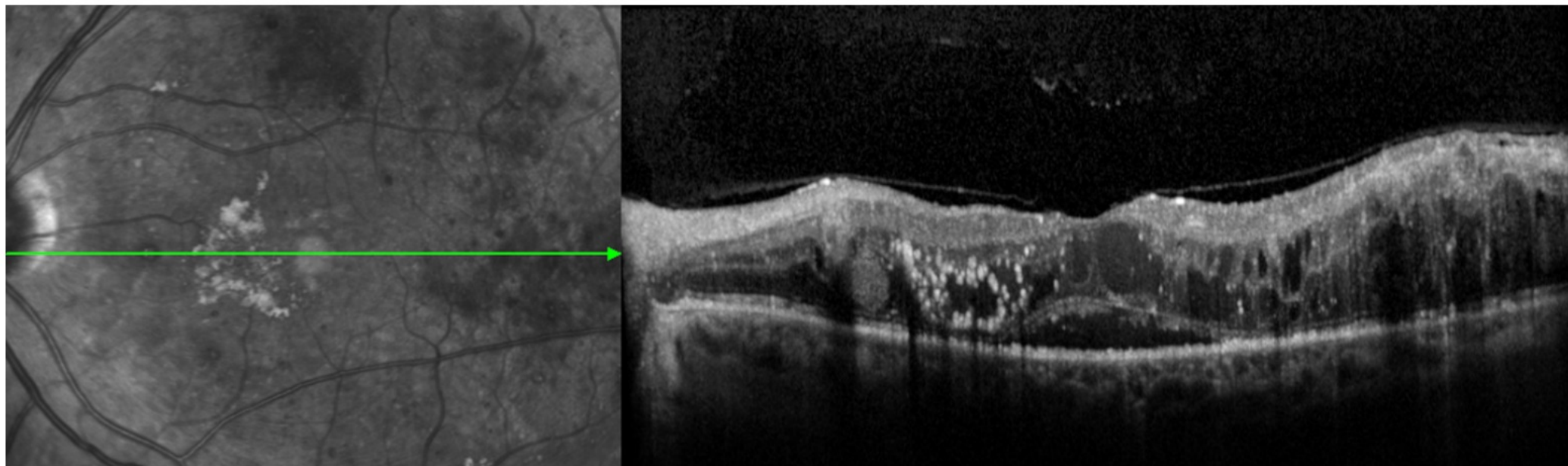
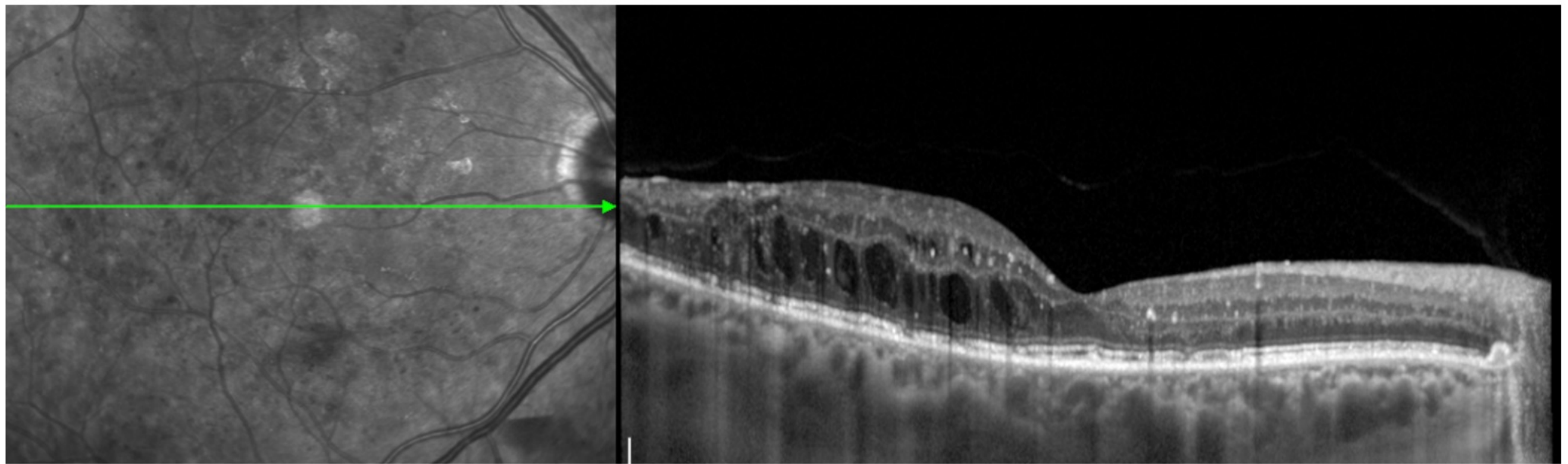
Outer Retina Structures

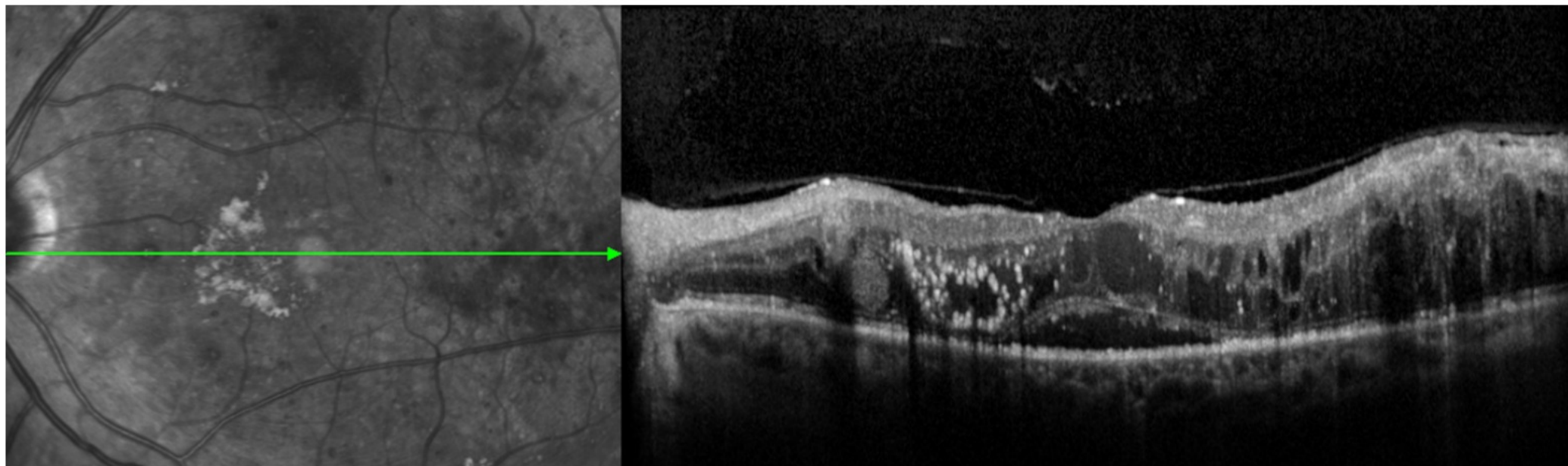
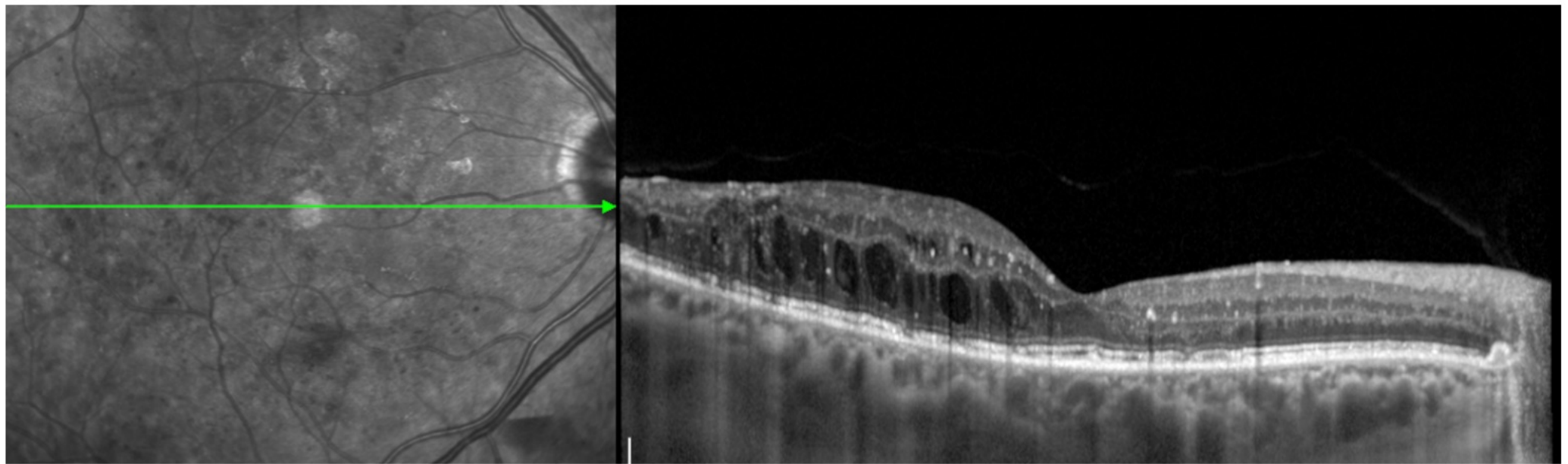
Functional Correlates



Click the tabs to explore more of the features visible using OCT.



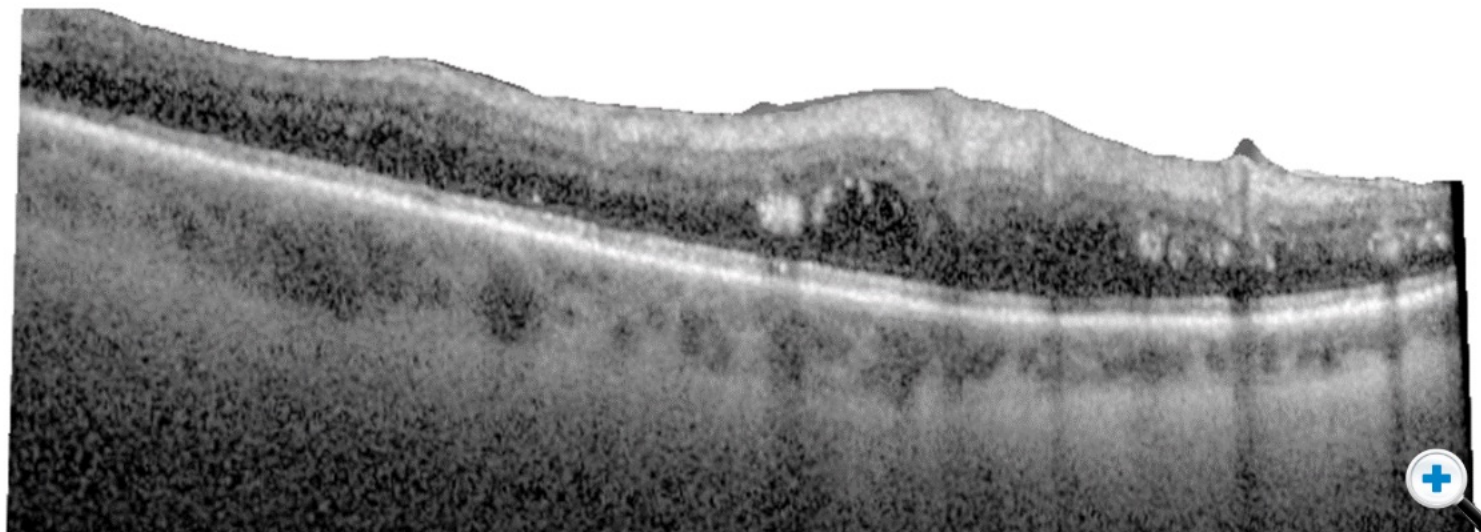
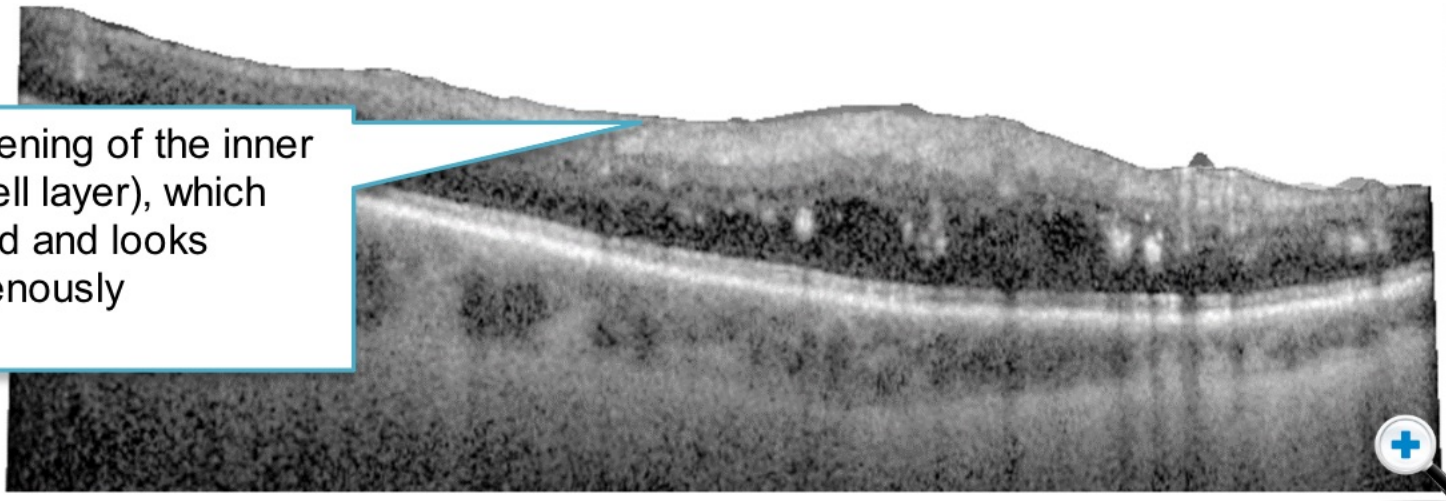




Inner Retina

On OCT all the retinal layers can be appreciated. The inner retina is particularly susceptible to changes arising from DR because the main impact of retinal capillary non perfusion affects the inner retina. On colour fundus photography retinal capillary closure and non perfusion leads to focal areas of infarction, which manifests as cotton wool spots.

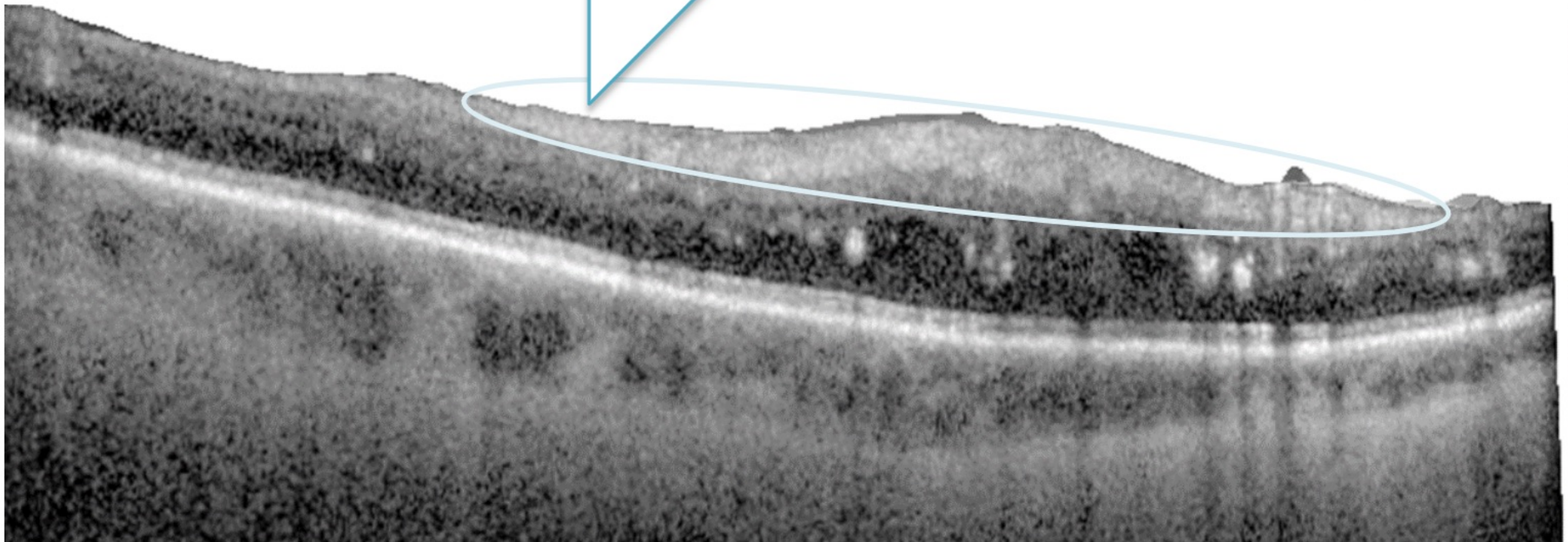
You can see thickening of the inner retina (ganglion cell layer), which becomes infarcted and looks diffusely, homogenously hyperreflective.

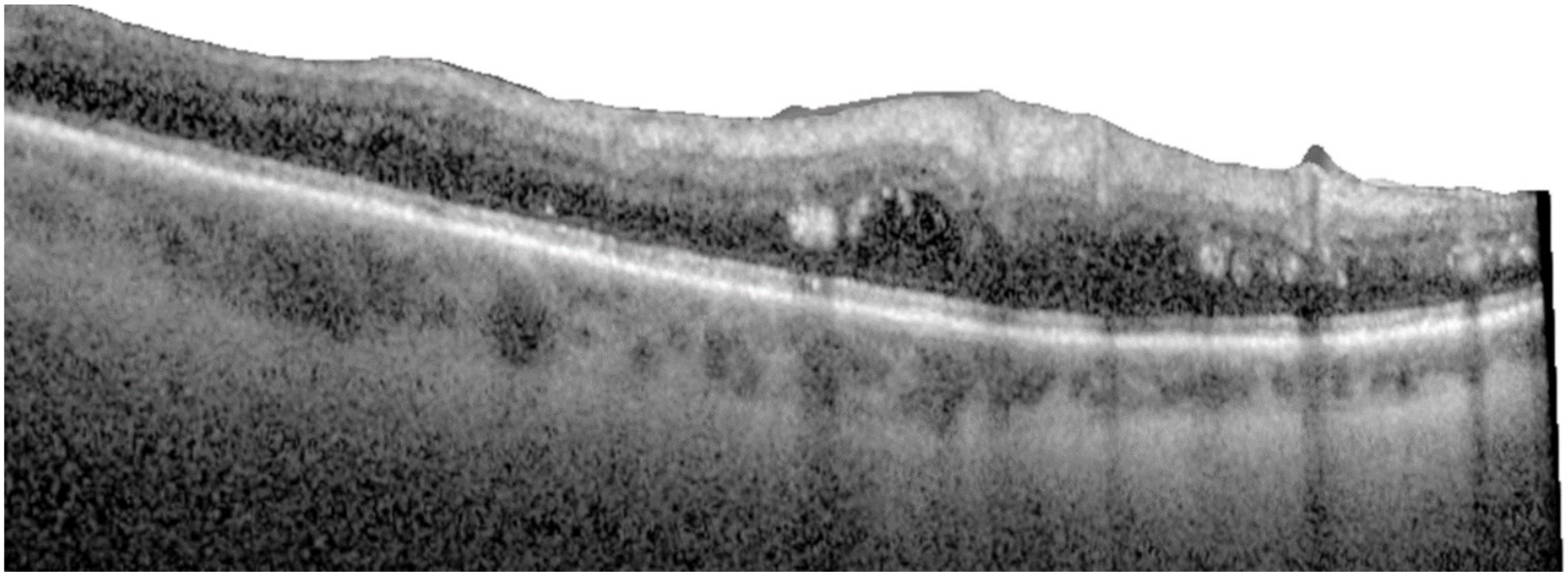


Click images
to enlarge



Thickening of inner retina (ganglion cell layer), which becomes infarcted and looks diffusely, homogeneously hyperreflective. The inner retinal layers can no longer be differentiated from each other - the term used to describe this is Disorganized Retinal Inner Layers or DRIL. DRIL is a manifestation of long term BRB breakdown and ischemia due to capillary non perfusion and reflects severe disease. These changes can become permanent.






Inner/Outer Retina Junction (Lipid Exudate)

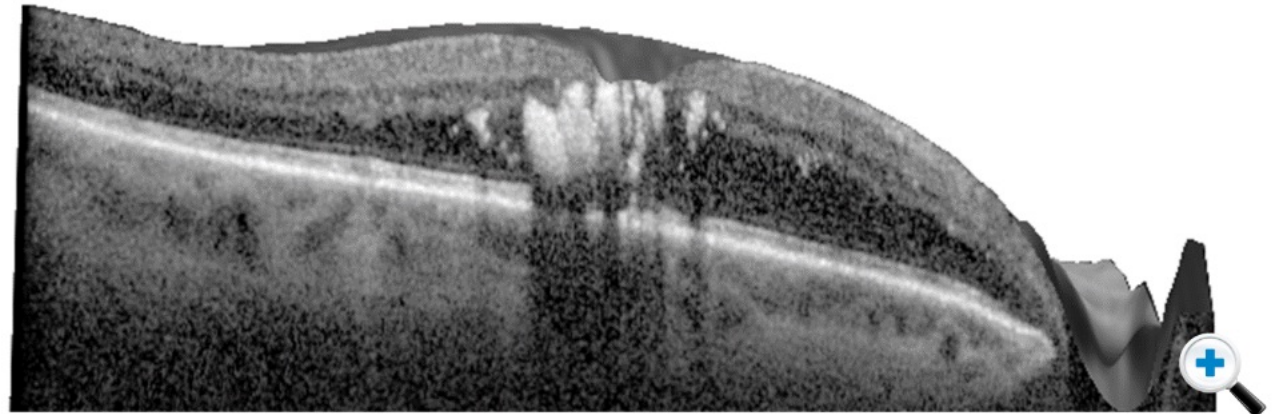
These images illustrate hyperreflectivity associated with lipid exudate.


These can collect at the junction between the outer and inner retina. Thanks to OCT, we are starting to understand where these leaks occur.

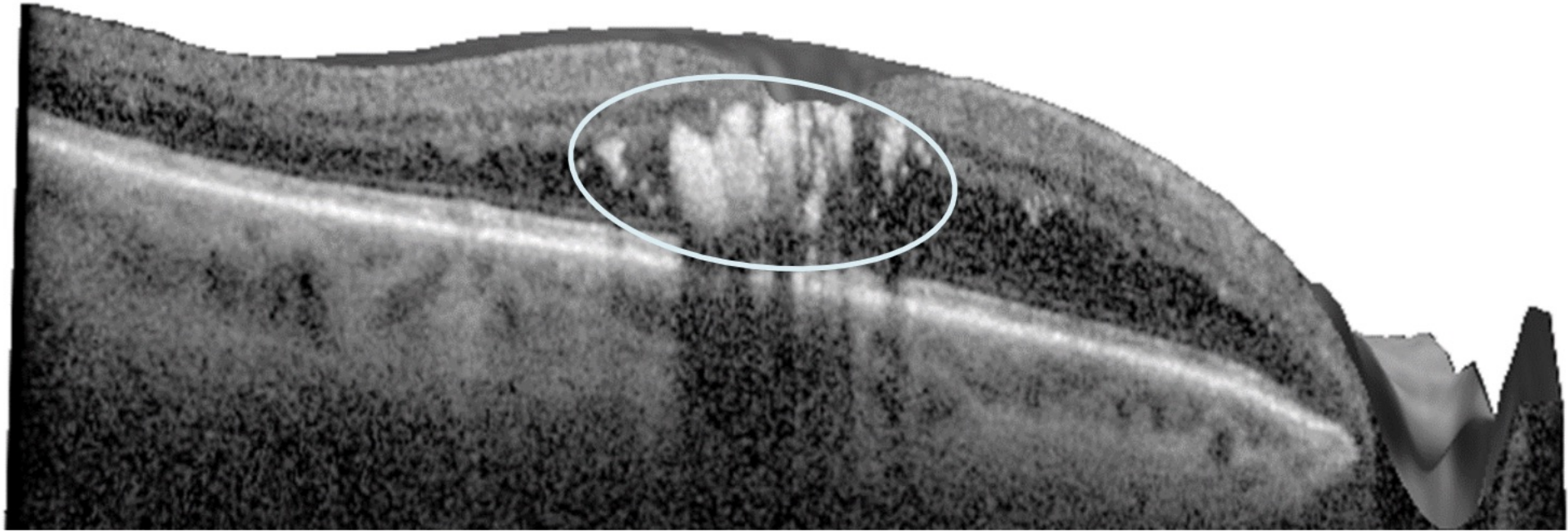
With the development of OCT angiography, it will be interesting to localise these effects to the specific layers of retinal vessels that we now know exist.



[Click images to enlarge](#)





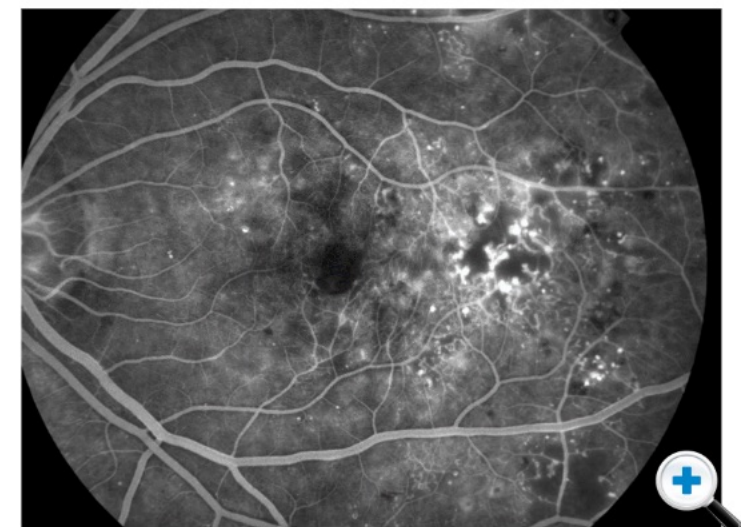
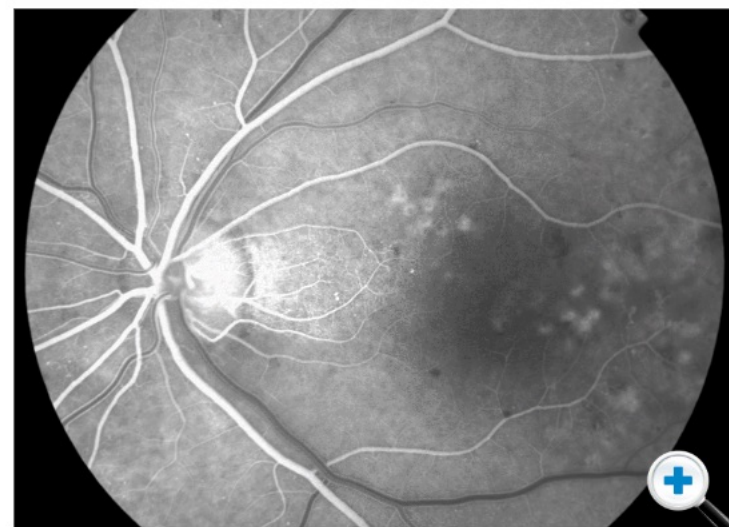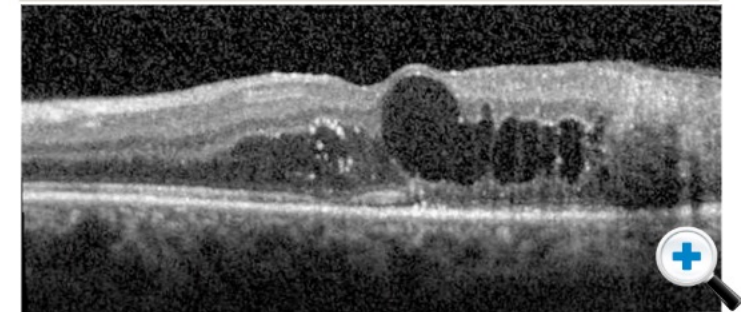
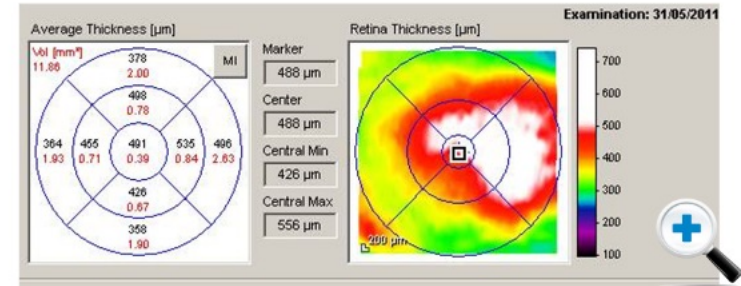

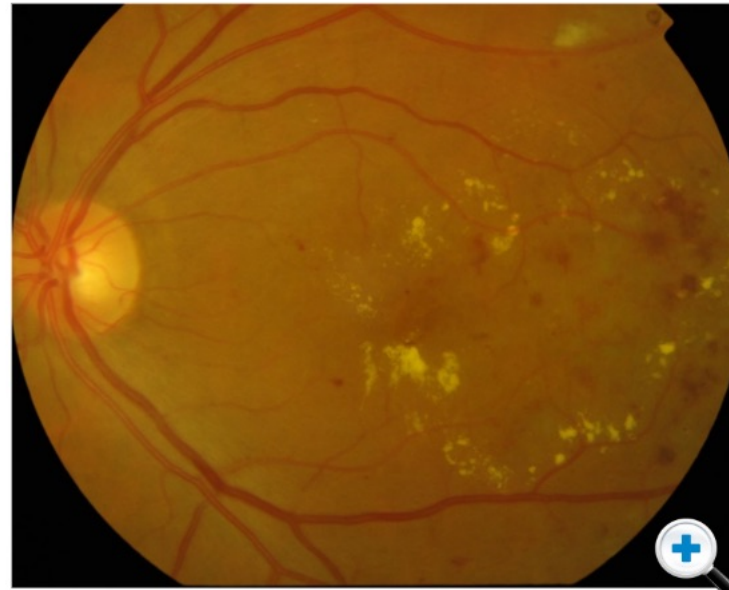
Macular Edema and Thickness Maps

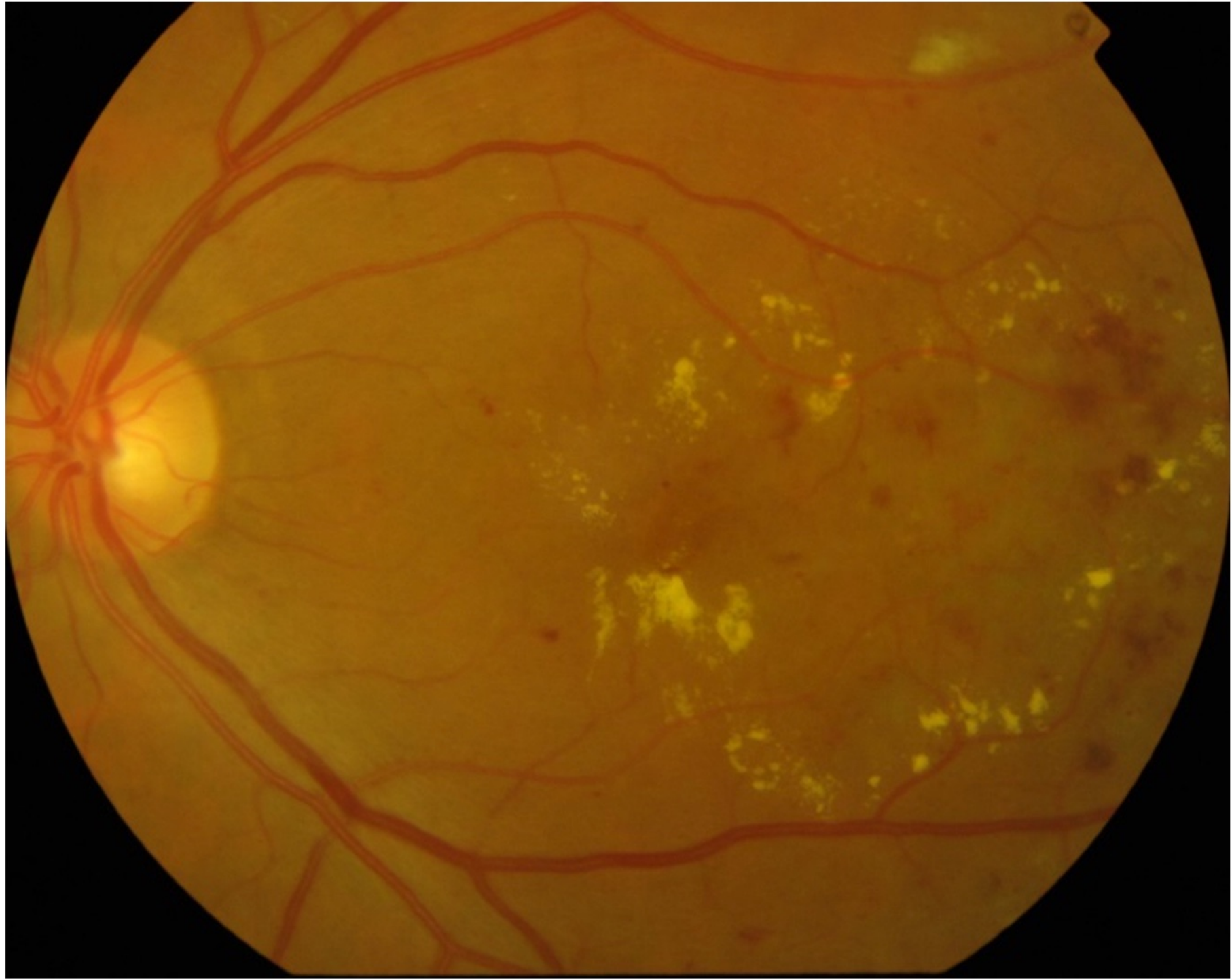
The pathophysiology of diabetic macular edema can be imaged using thickness maps.

Over time, you can monitor changes in OCT thickness on a sectoral basis - not just central macular thickness or central foveal thickness, but looking across the entire macula in an integrated manner.

Here, one can see the greatest thickness seen on OCT corresponds to an area of IRMA on colour.



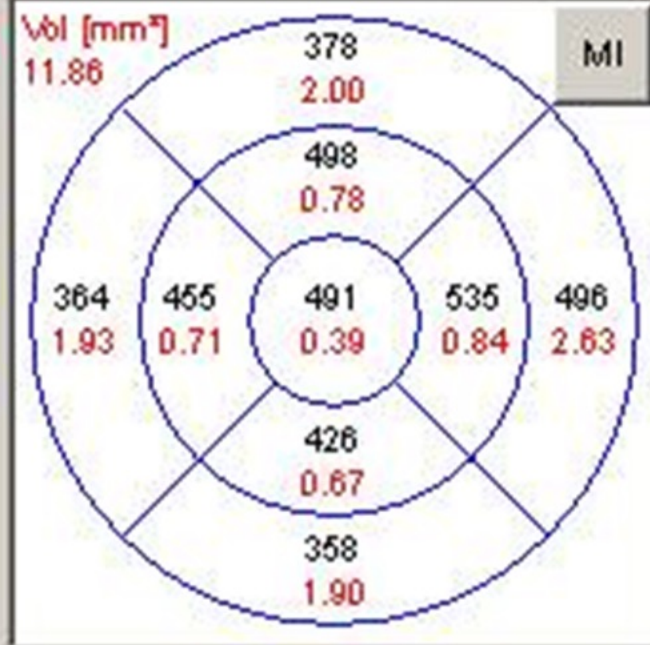
Click images to enlarge





Examination: 31/05/2011

Average Thickness [μm]



Marker

488 μm

Center

488 μm

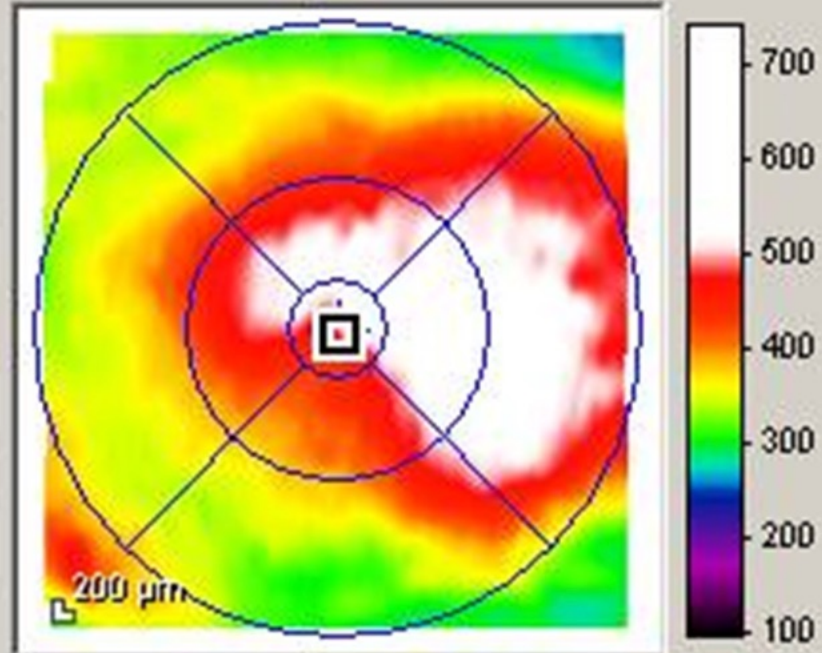
Central Min

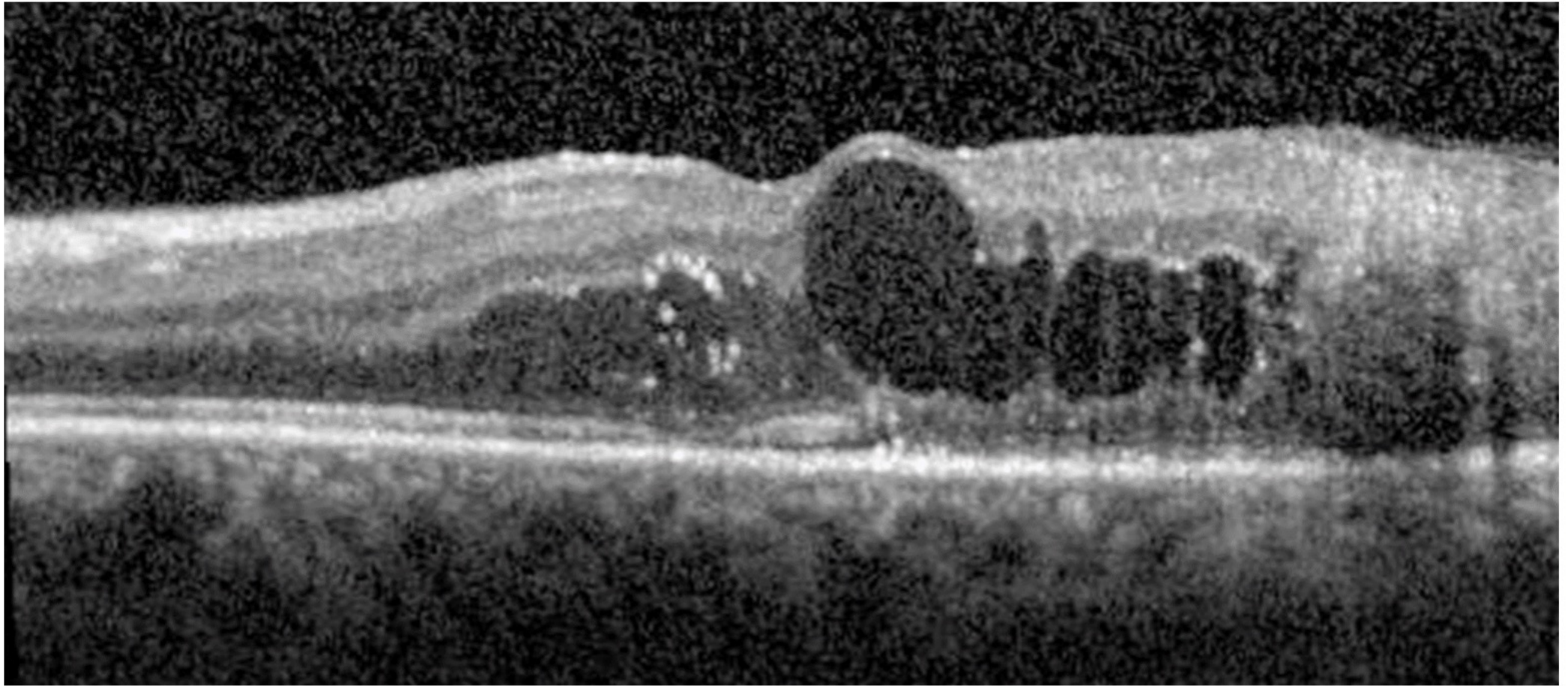
426 μm

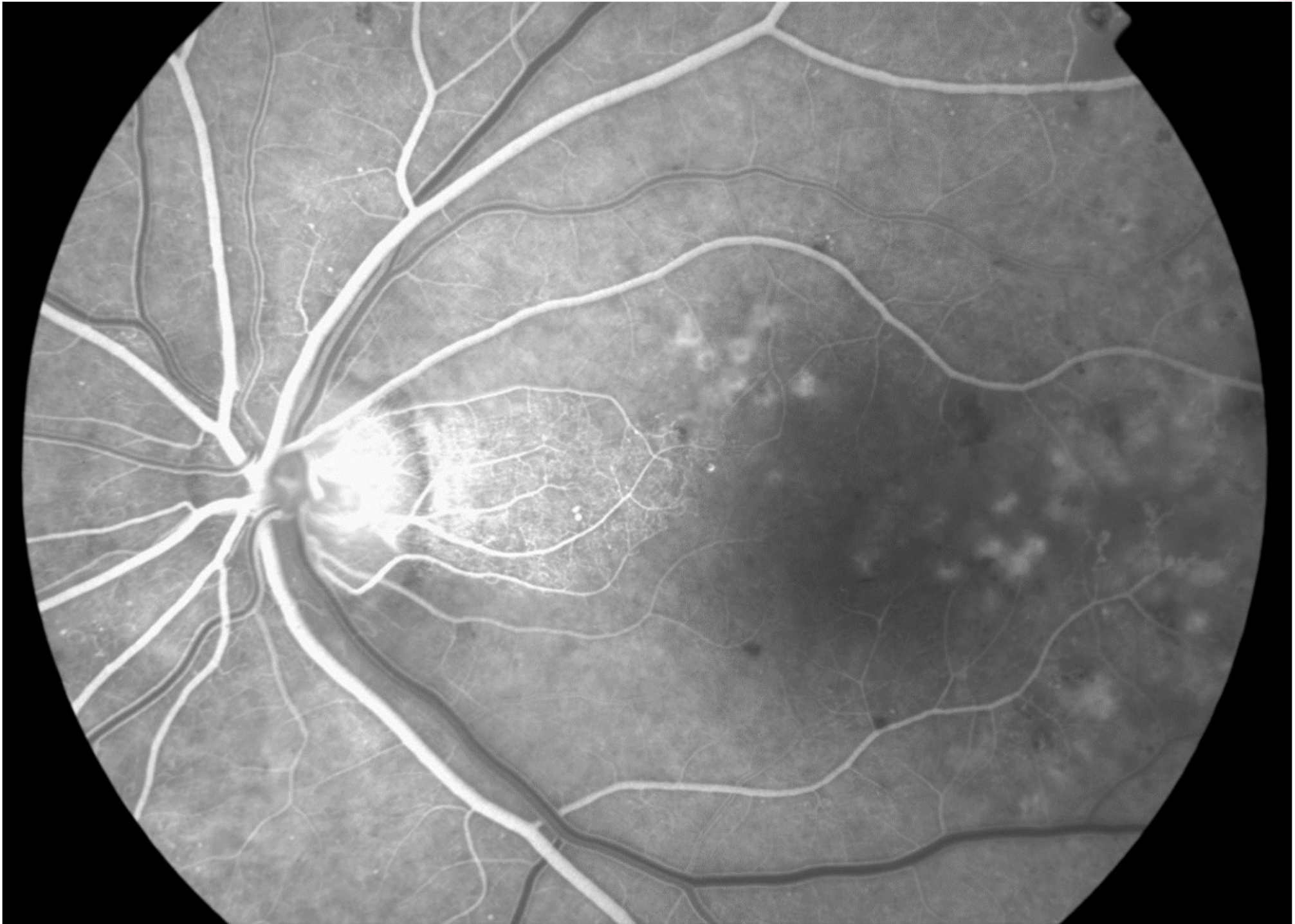Central Max

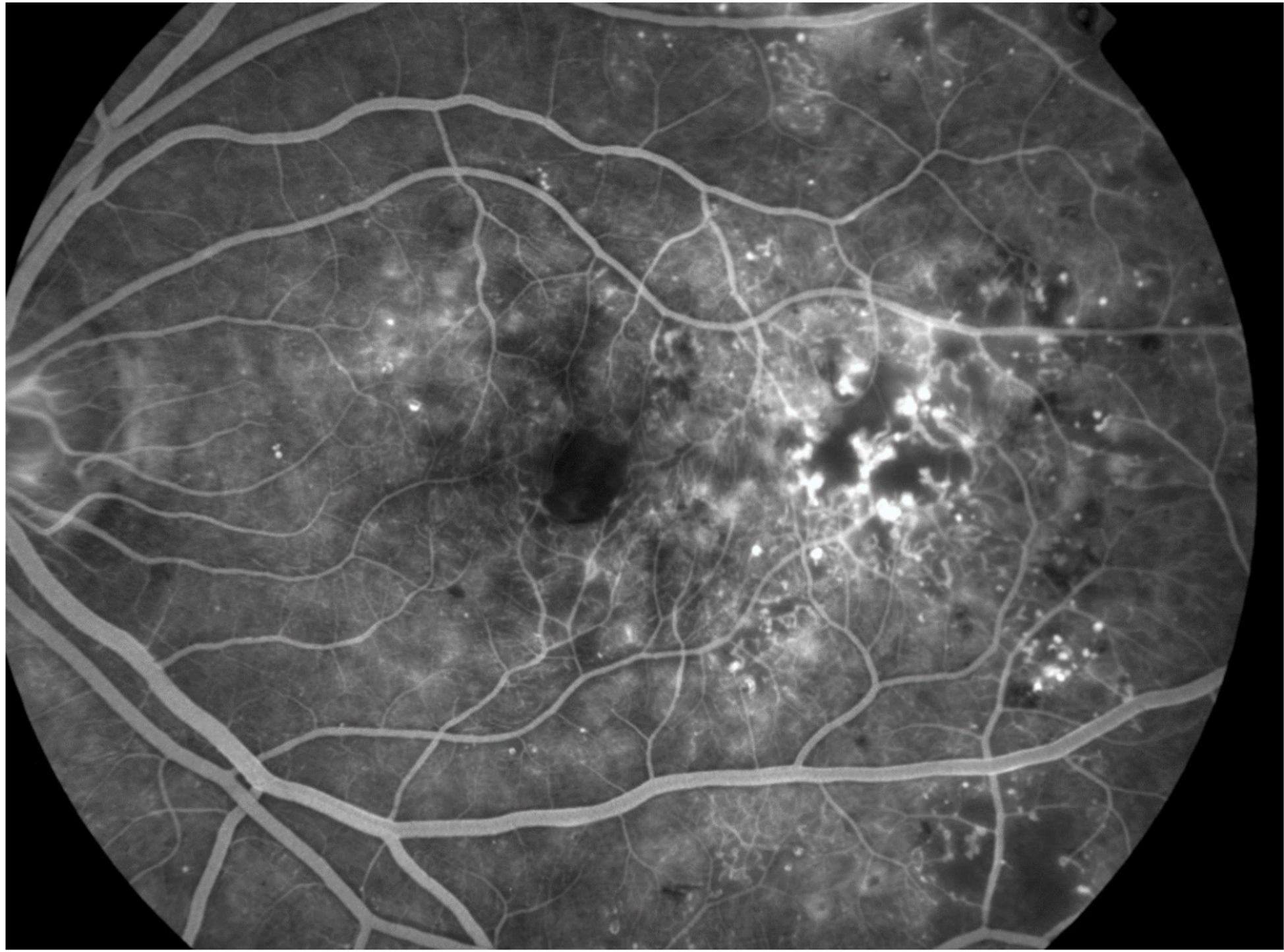
556 μm

Retina Thickness [μm]





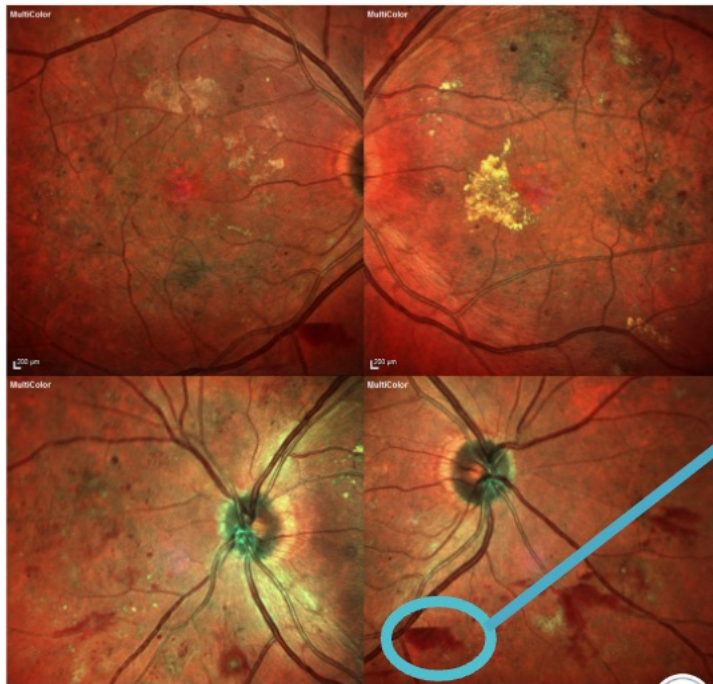




Multi-Colour Channel Imaging

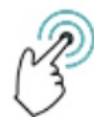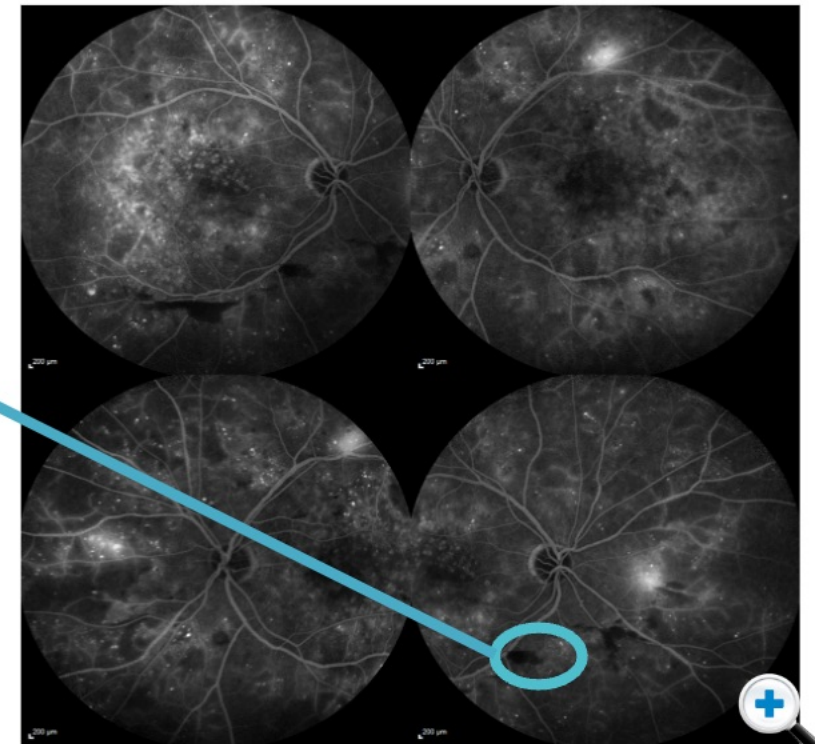
Our understanding of what happens at the retina is evolving, along with technology. Digital imaging and new processing algorithms provide new perspectives on what we can image/ see.

One example of this is the use of multi-colour channels with multiple lasers. We are still unsure of the correlates with traditional colour images. However, by judiciously using the multi-channel systems and corresponding FA, you can start to make correlations.

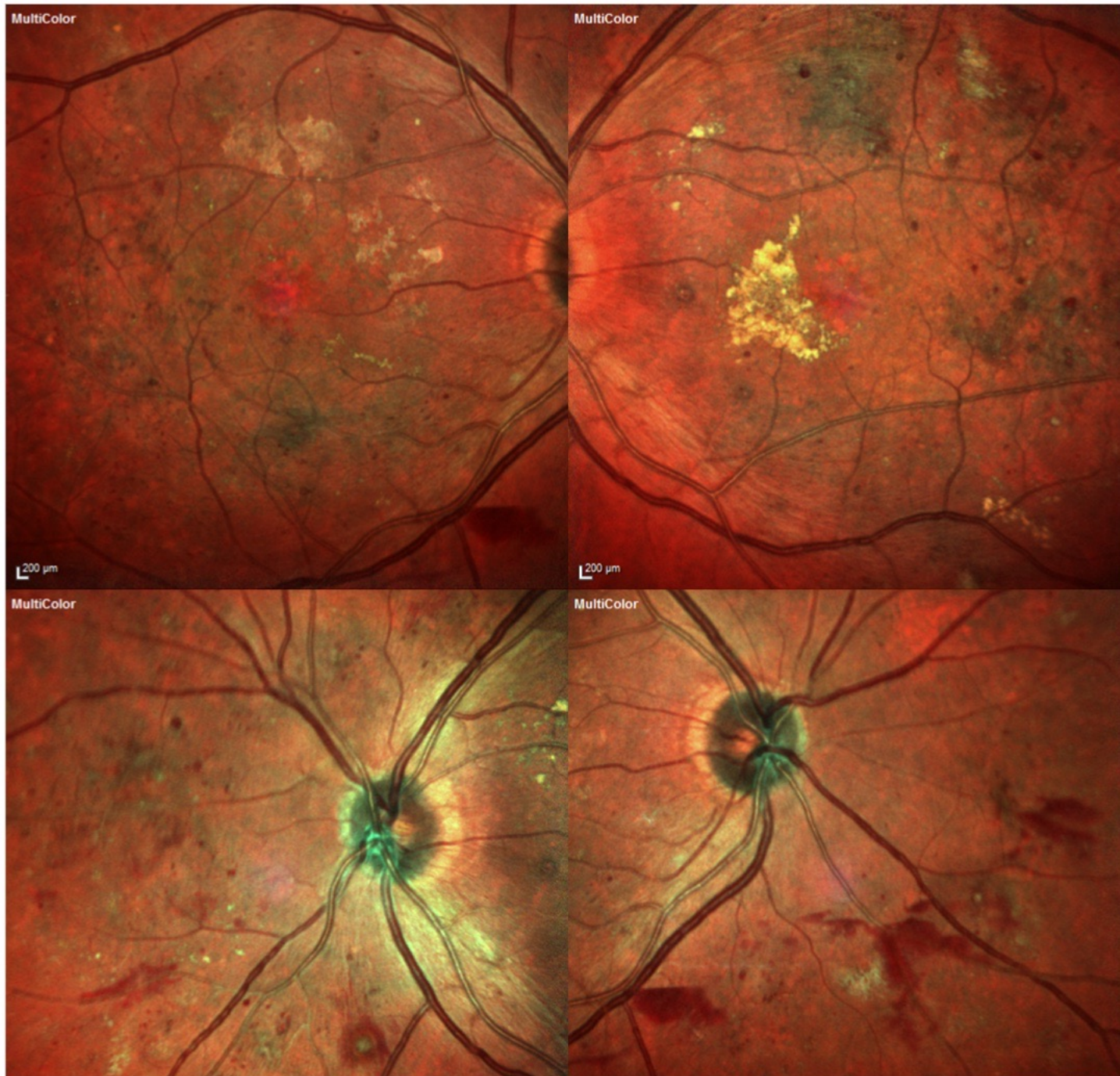


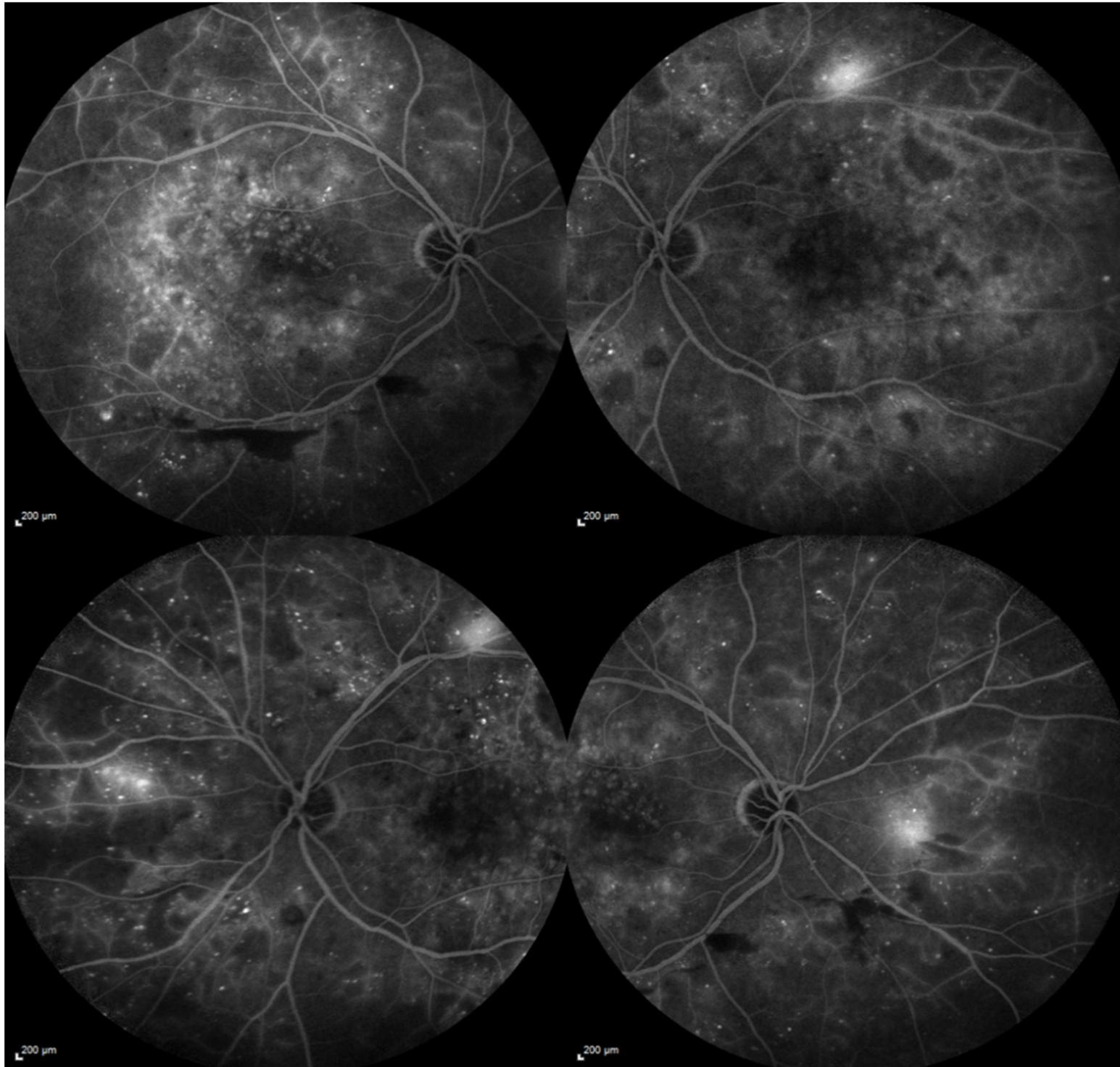
Here you see an area of pre-retinal haemorrhage, corresponding to an area of blockage (dark region) of the normal background fluorescence on FFA.

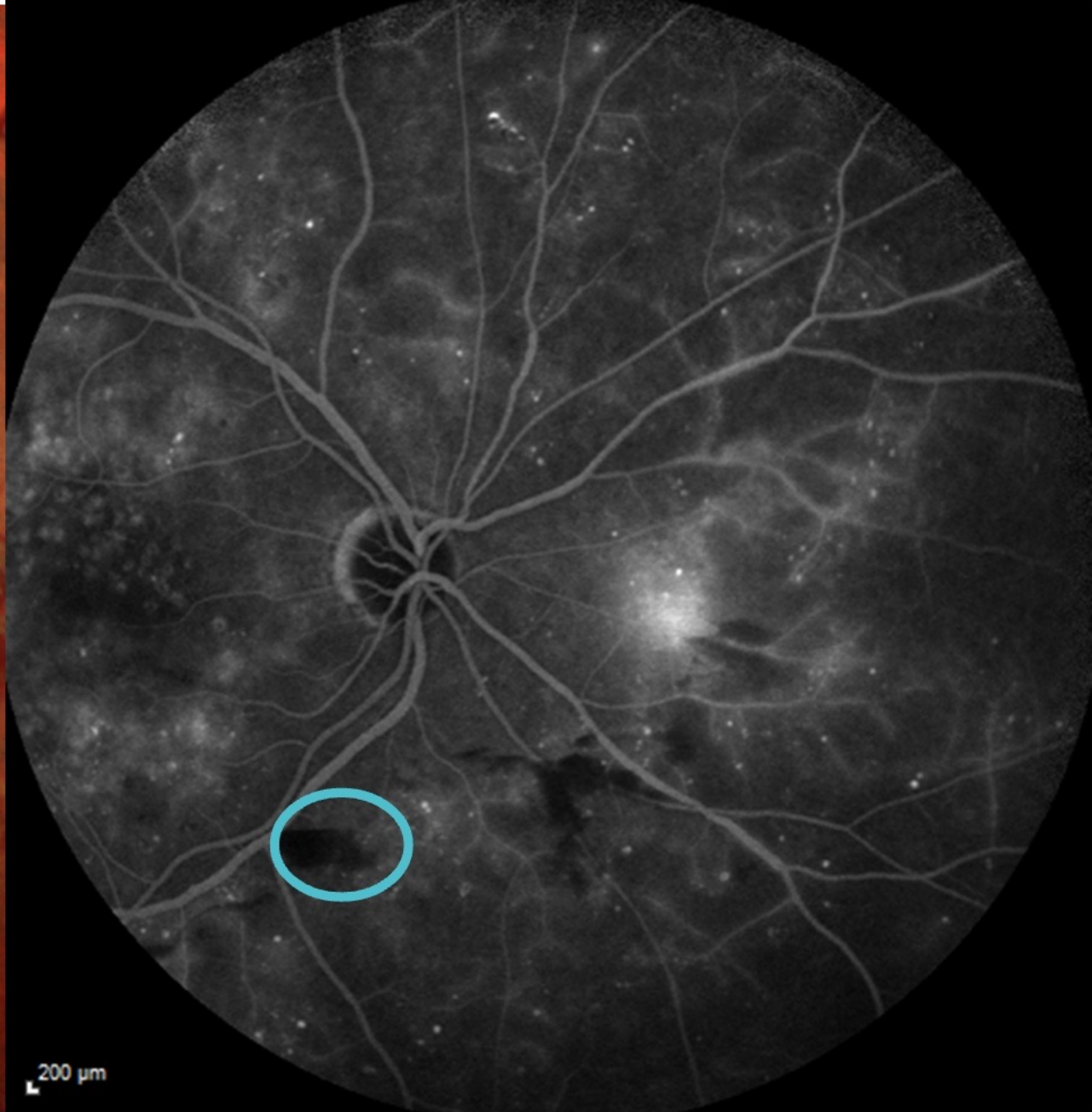
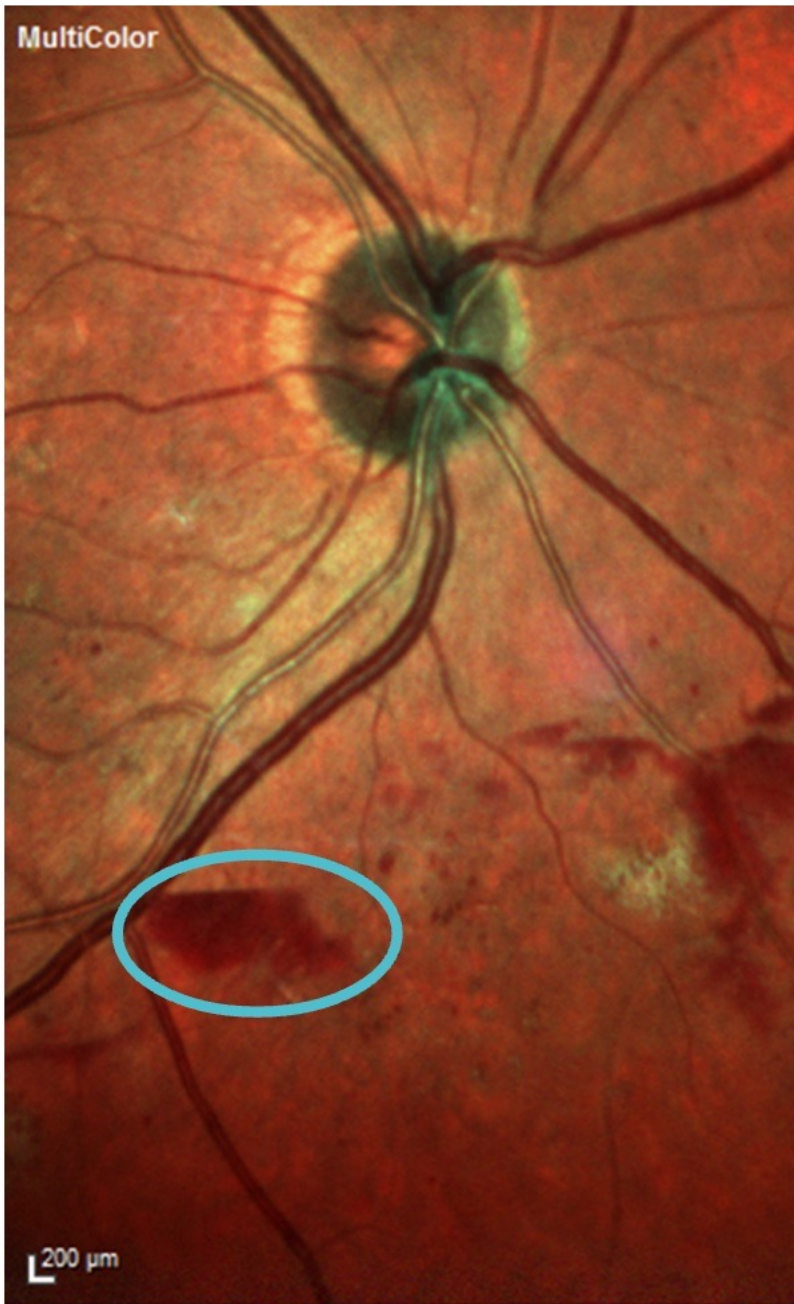(Click this box to compare these images directly)



Click images to enlarge





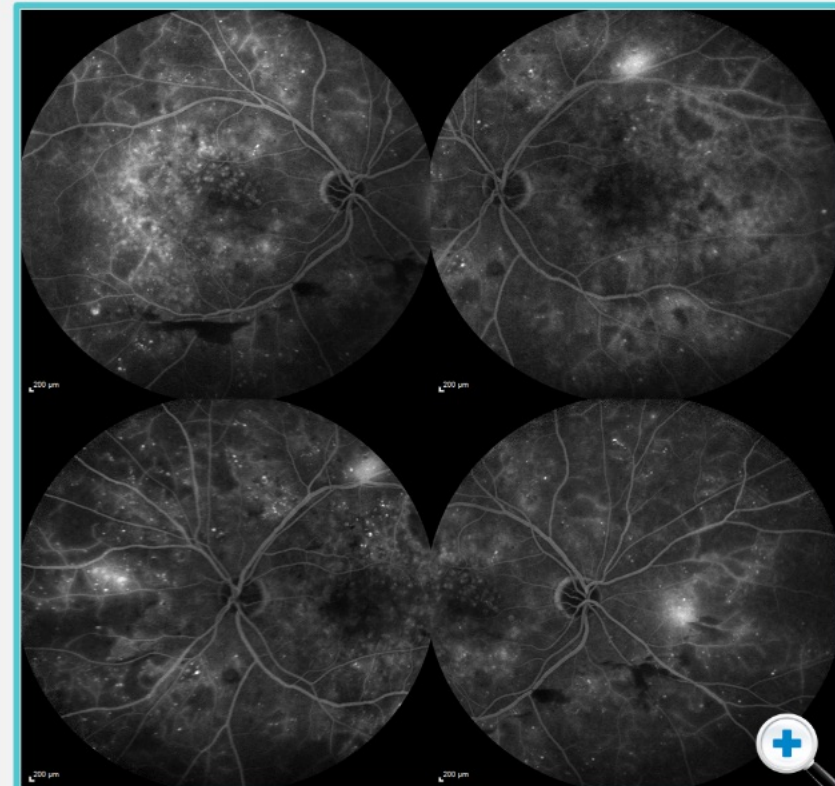
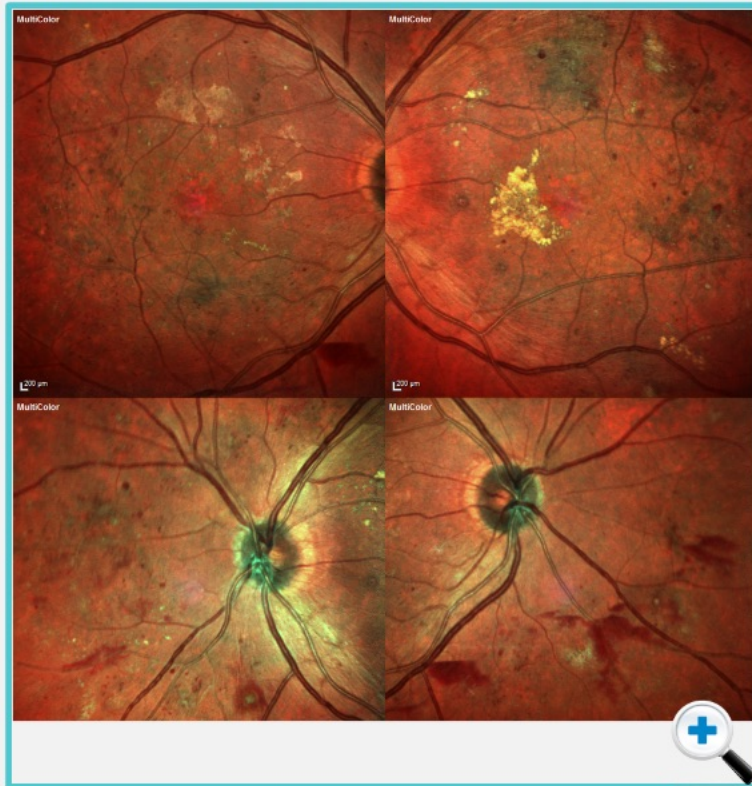


Following Treatment

These images are from the same individual seen in the previous screen. This patient underwent anti VEGF therapy.



Use the arrows to see how therapy for this patient can be followed and treatment response monitored.



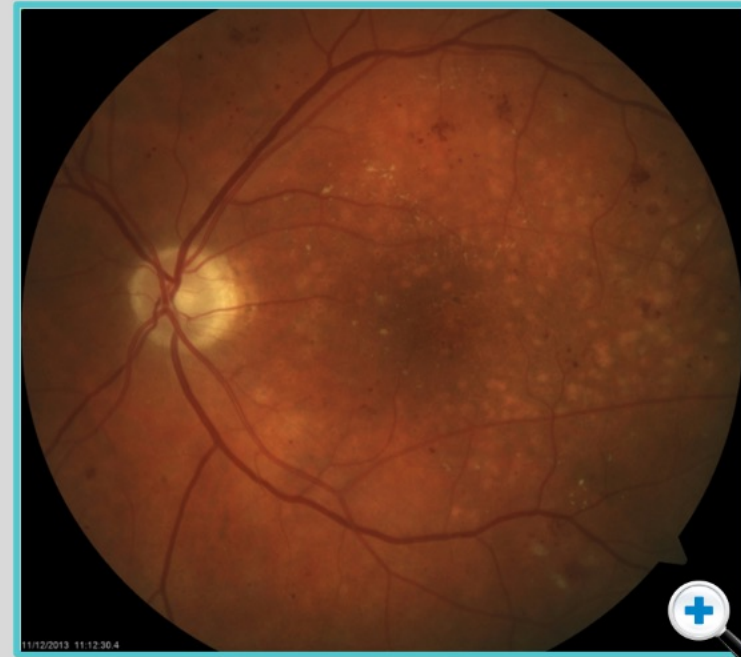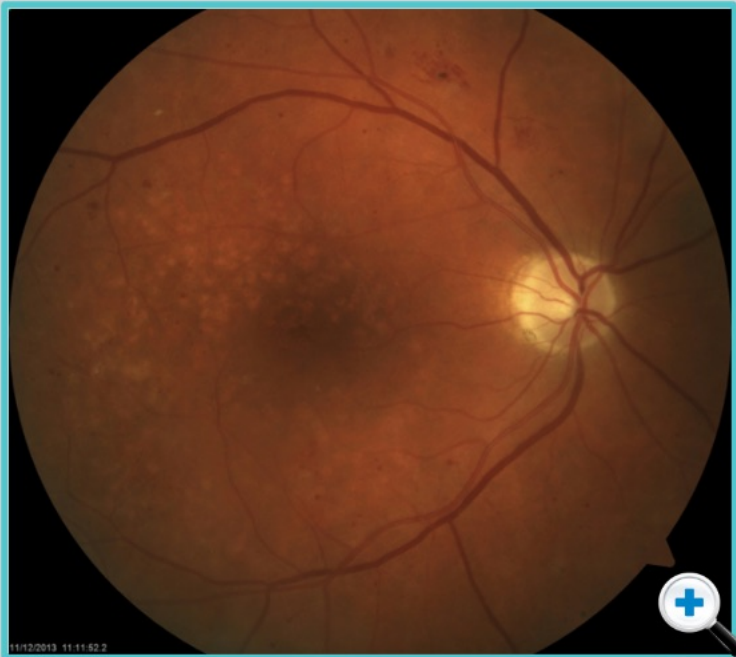Following Treatment

These images are from the same individual seen in the previous screen. This patient underwent anti VEGF therapy.



Use the arrows to see how therapy for this patient can be followed and treatment response monitored.

This is the patient after therapy. Even on **colour imaging** alone, it is clear the manifestations of retinopathy have reduced dramatically.



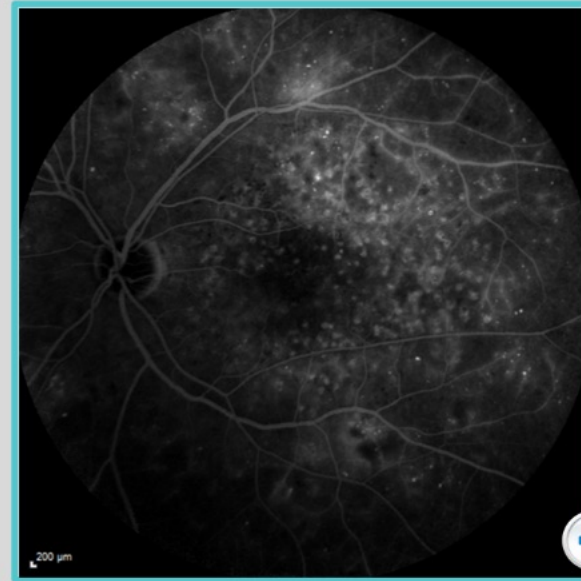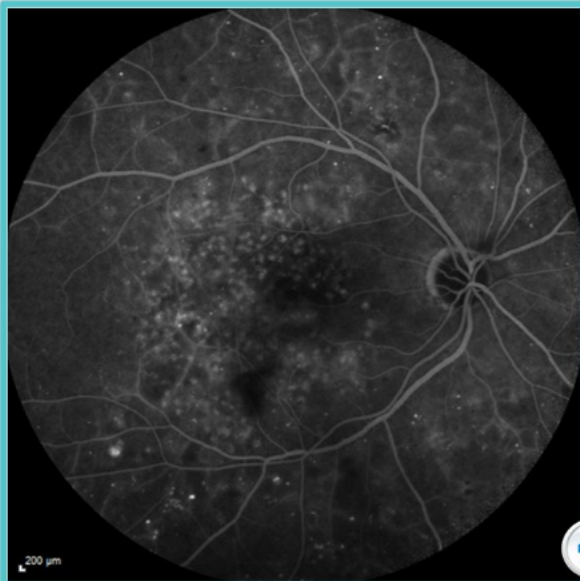Following Treatment

These images are from the same individual seen in the previous screen. This patient underwent anti VEGF therapy.



Use the arrows to see how therapy for this patient can be followed and treatment response monitored.

On FFA, there has been a marked improvement in the appearance of the retina due to disappearance of hemorrhages. However it is not possible to confirm if retinal perfusion has truly reduced .



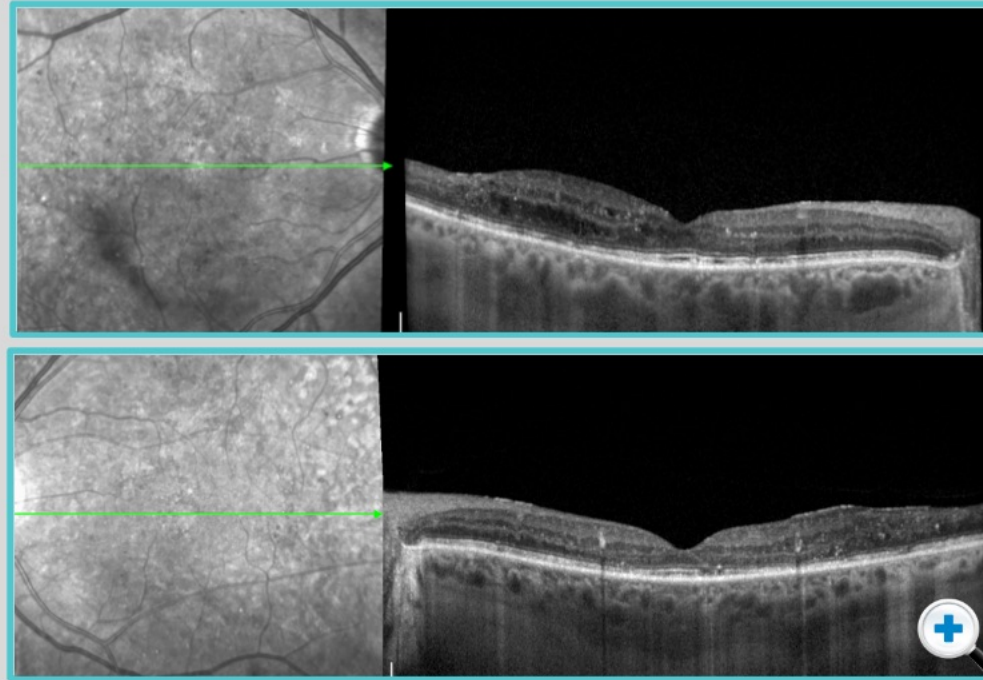
Following Treatment

These images are from the same individual seen in the previous screen. This patient underwent anti VEGF therapy.



Use the arrows to see how therapy for this patient can be followed and treatment response monitored.

OCT shows dramatic improvement in retinal architecture.



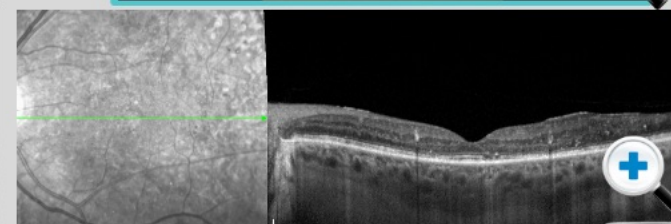
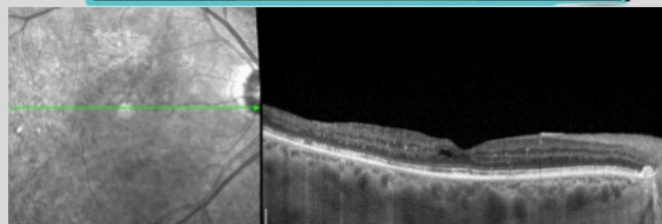
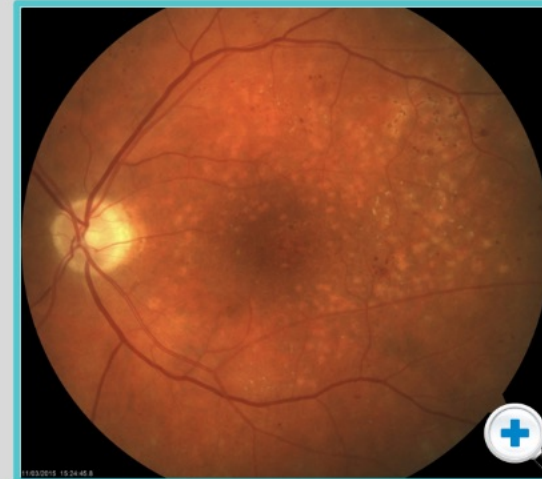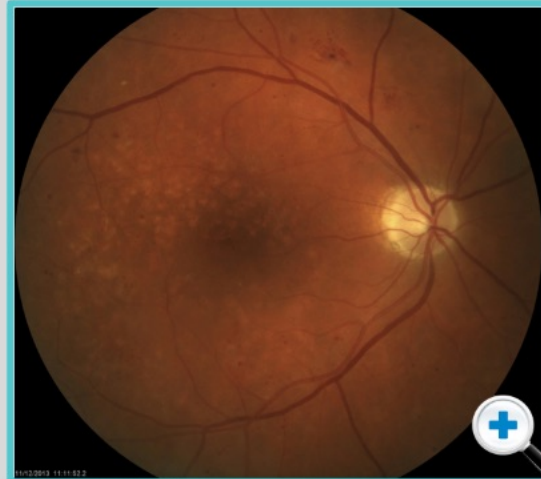
Following Treatment

These images are from the same individual seen in the previous screen. This patient underwent anti VEGF therapy.



Use the arrows to see how therapy for this patient can be followed and treatment response monitored.

This is the **eye 1 year after therapy.**



OCT Angiography

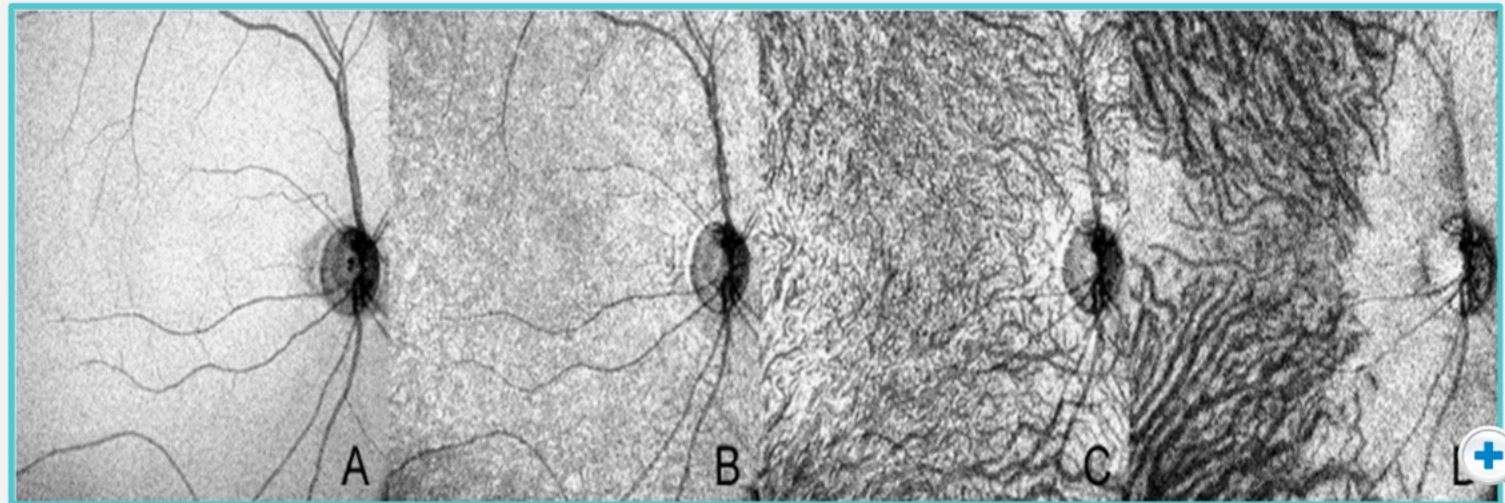
OCT angiography is a new development in imaging the pathophysiology of diabetic retinopathy and diabetic macular edema.

This method shows us the different layers.

*Images are courtesy Nadia Waheed,
New England Eye Centre, Boston.*

This example shows a **normal** eye of a 50 year-old patient.

The images show the surface features of the different layers (i.e. each layer is displayed as a slab)



Normal Choroid of 50 Year Old



Use the arrows to scroll through examples of OCT angiography

OCT Angiography

OCT angiography is a new development in imaging the pathophysiology of diabetic retinopathy and diabetic macular edema.

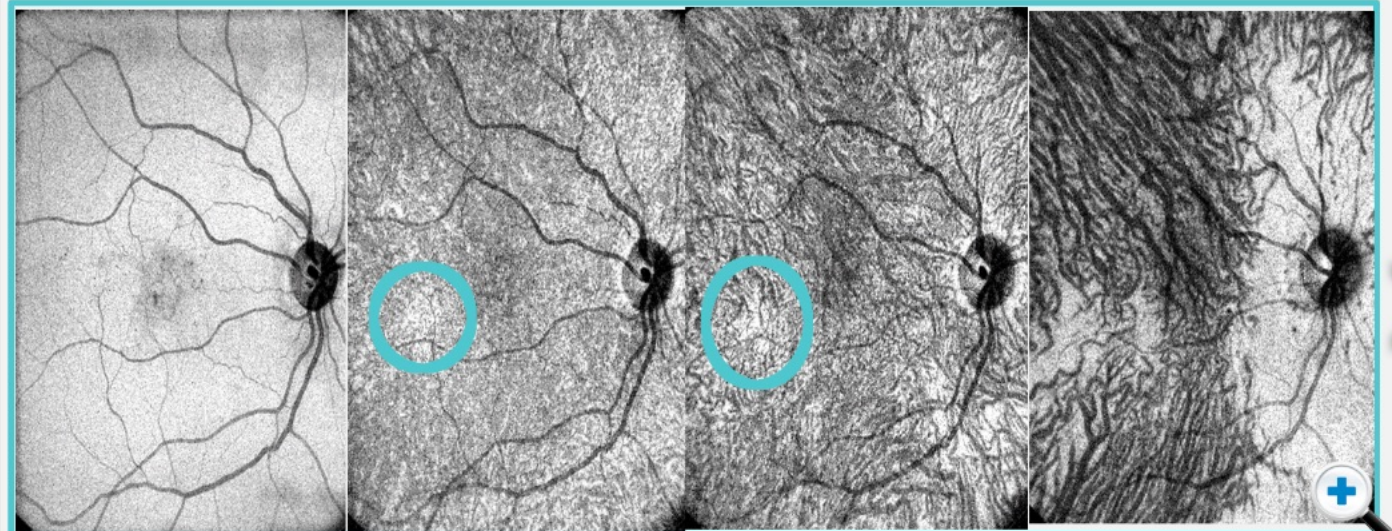
This method shows us the different layers.

*Images are courtesy Nadia Waheed,
New England Eye Centre, Boston.*

This is a case where there is **no diabetic retinopathy, but mild diabetic macular edema.**

There are interesting observations (circled), but we are unsure of their significance as yet.

Abnormalities appear in the density of the different layers of vasculature in the macula.



No DR, Mild DME (Click to compare with normal)



Use the arrows to scroll through examples of OCT angiography

OCT Angiography

OCT angiography is a new development in imaging the pathophysiology of diabetic retinopathy and diabetic macular edema.

This method shows us the different layers.


*Images are courtesy Nadia Waheed,
New England Eye Centre, Boston.*

This is an example of **severe DME**.

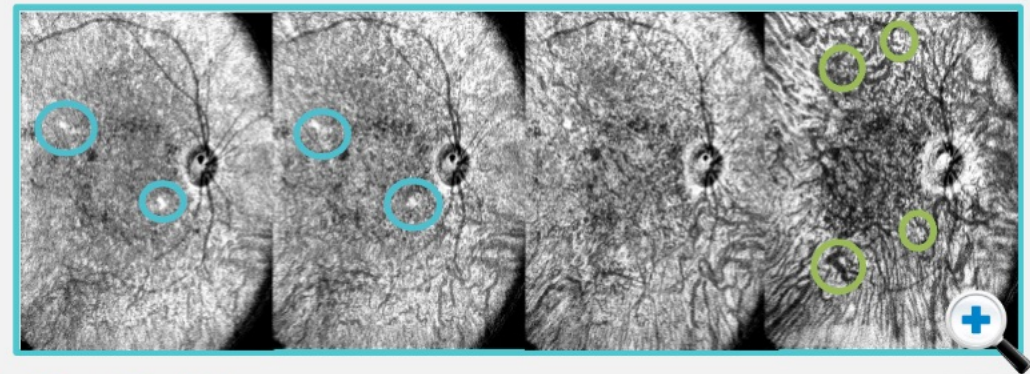
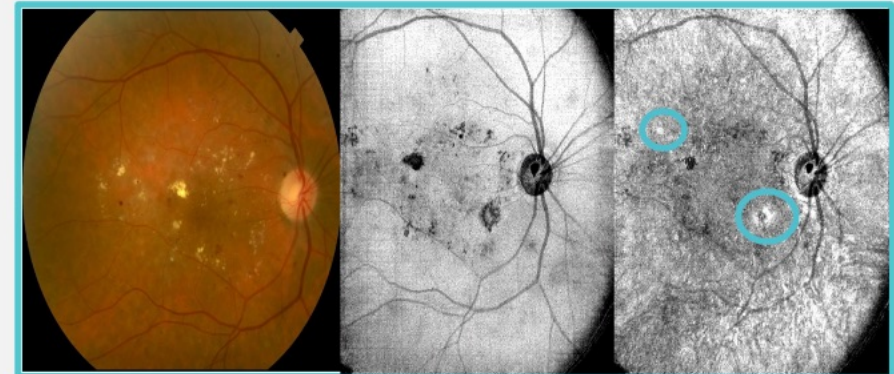
There are more intense changes in the multiple layers of retinal vasculature as we move from the inner retina, through the outer retina and into the choroid.

Click to zoom the images and see:

- Capillary dropout
- Focal dilation and narrowing
- Vascular tortuosity

 *Focal dilation and narrowing*

 *Capillary dropout*



Use the arrows to scroll through examples of OCT angiography

OCT Angiography

OCT angiography is a new development in imaging the pathophysiology of diabetic retinopathy and diabetic macular edema.

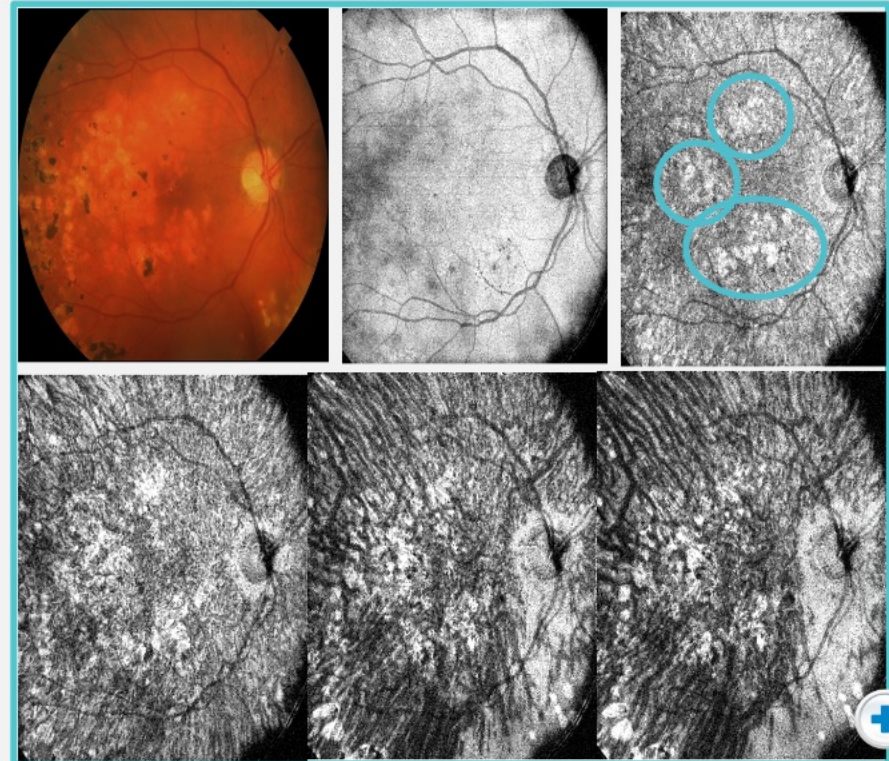
This method shows us the different layers.

*Images are courtesy Nadia Waheed,
New England Eye Centre, Boston.*

This is an example of **non proliferative diabetic retinopathy**.

You can see capillary dropout and several areas of focal dilation, narrowing, and other vascular abnormalities.

 *Capillary dropout*



Use the arrows to scroll through examples of OCT angiography

OCT Angiography

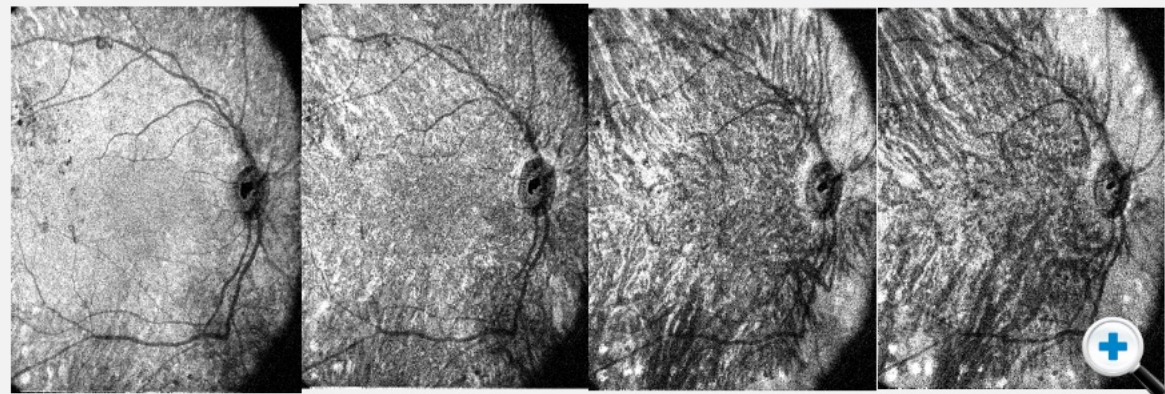
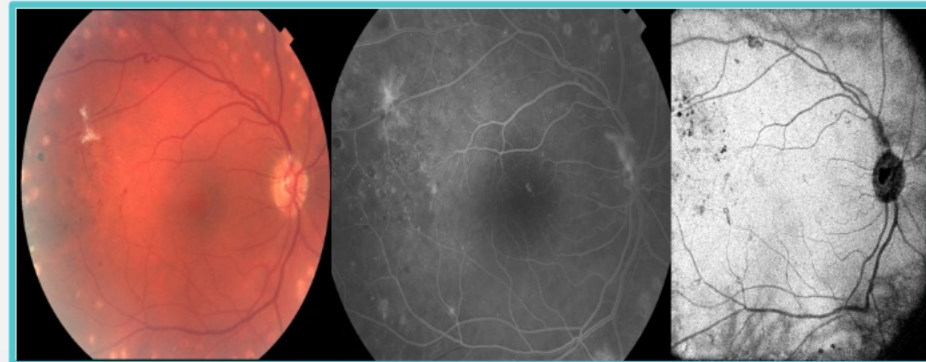
OCT angiography is a new development in imaging the pathophysiology of diabetic retinopathy and diabetic macular edema.

This method shows us the different layers.

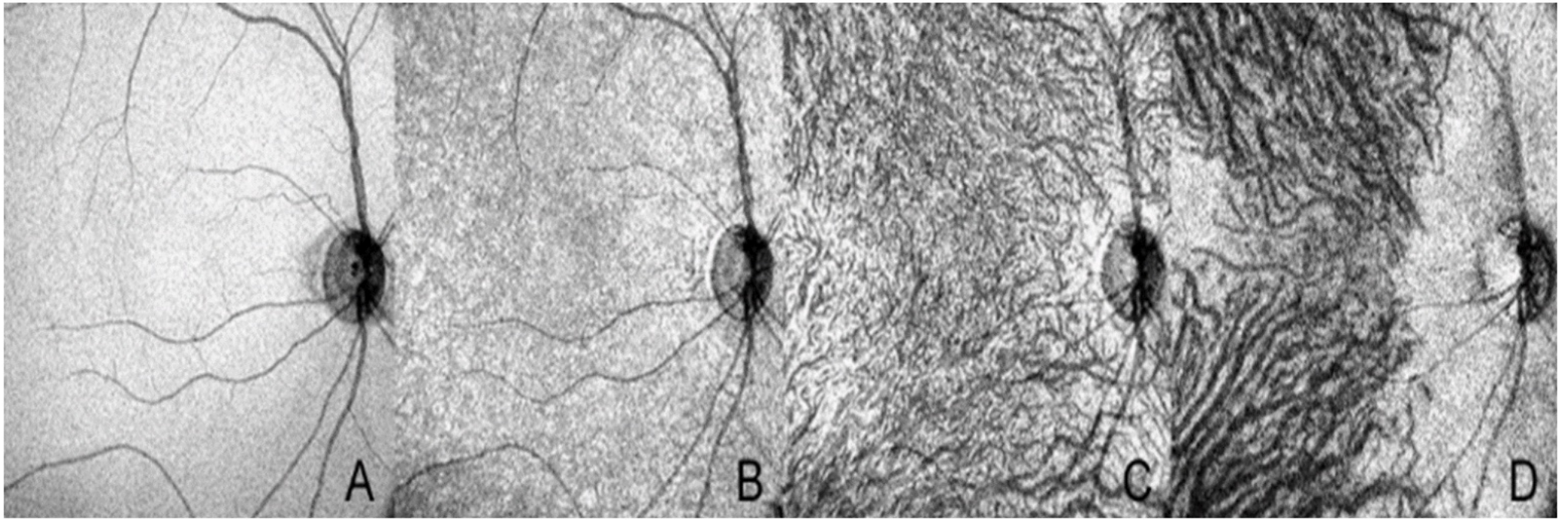
*Images are courtesy Nadia Waheed,
New England Eye Centre, Boston.*

This is an example of **proliferative diabetic retinopathy**, without macular edema.

Again, one sees various structural abnormalities, becoming apparent as the different layers of the retinal vasculature are segmented.

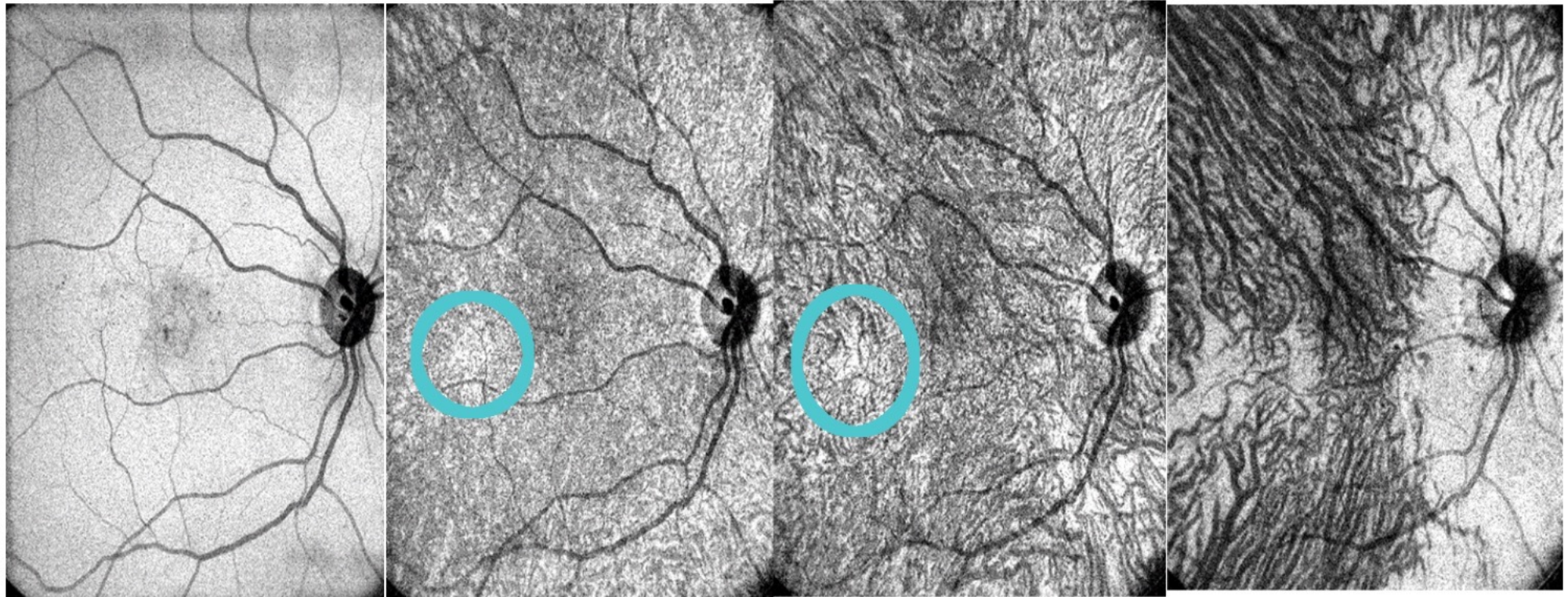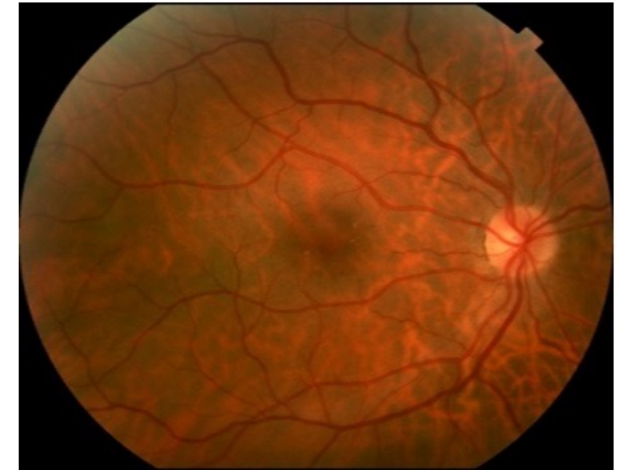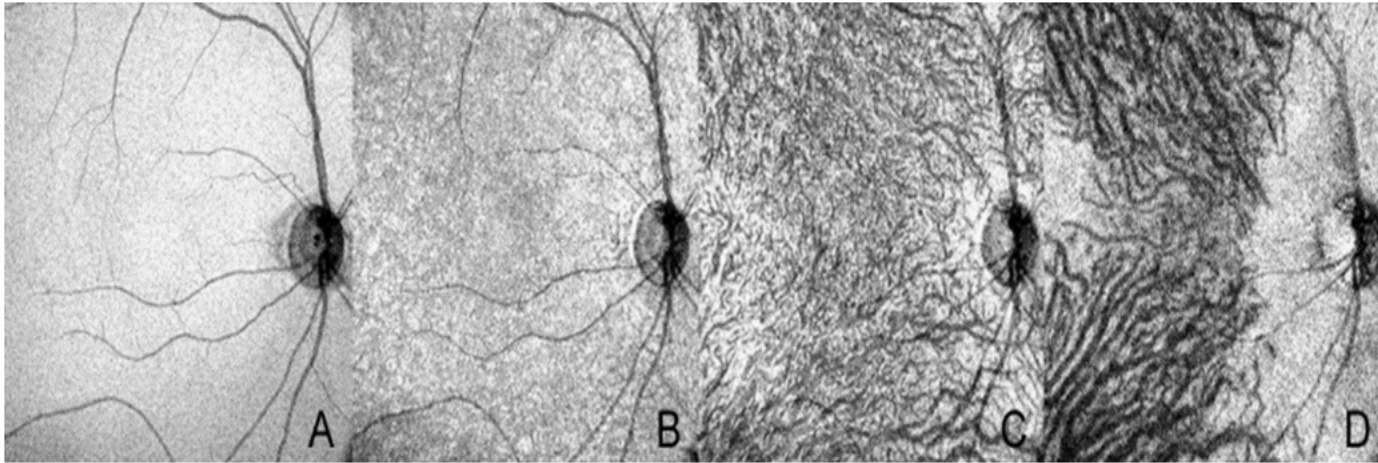


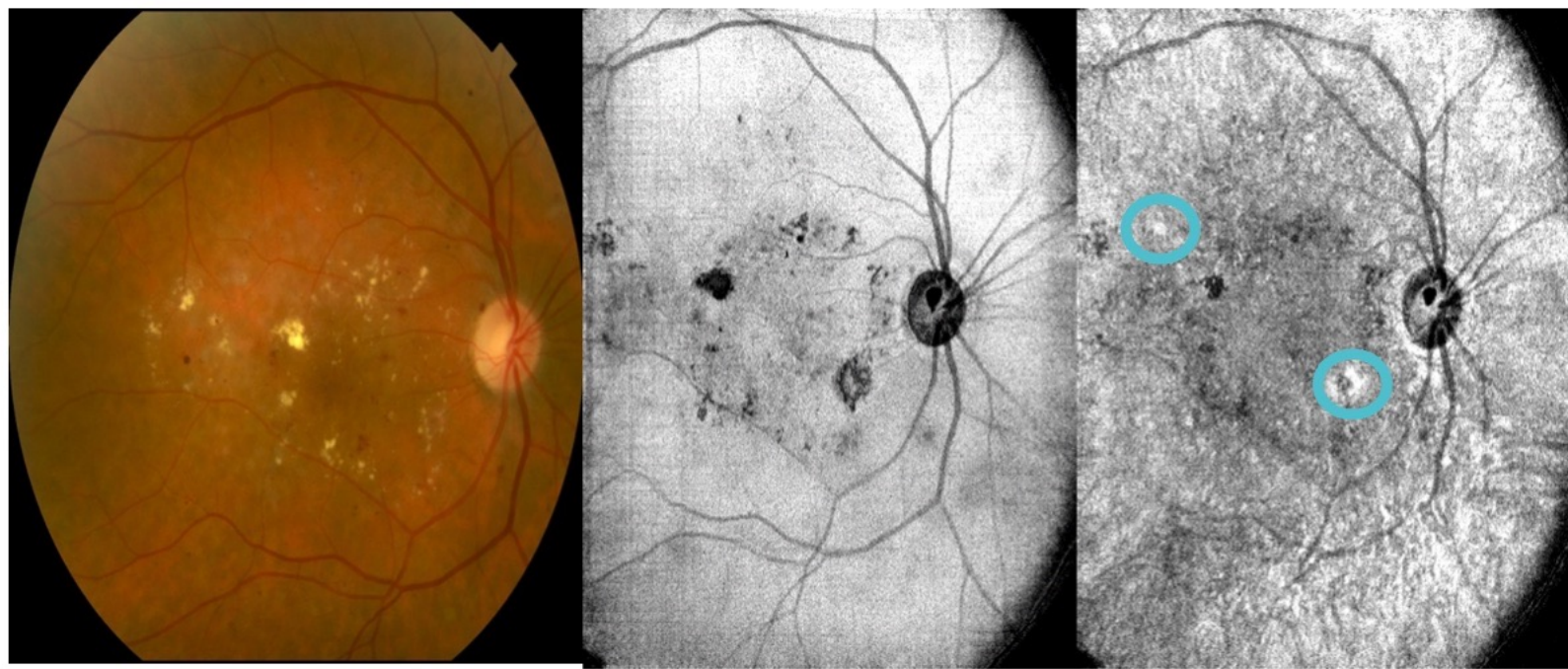
Use the arrows to scroll through examples of OCT angiography





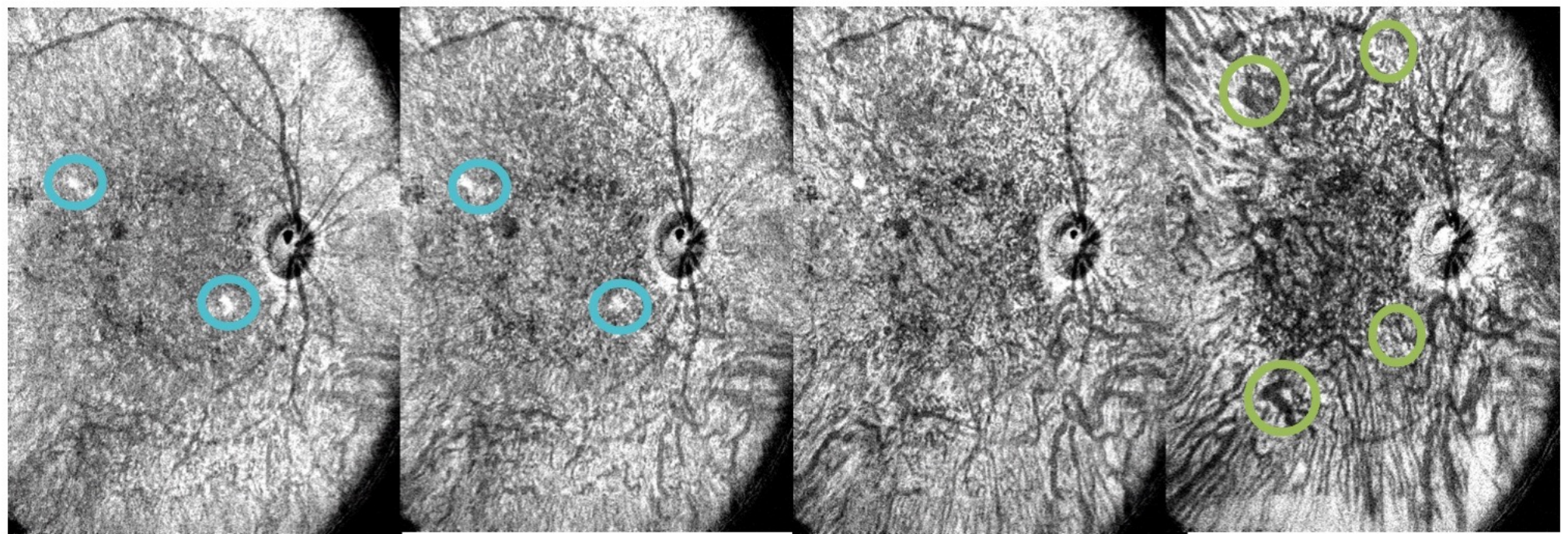
No DR, Mild DME (Compare with Normal, Top image)



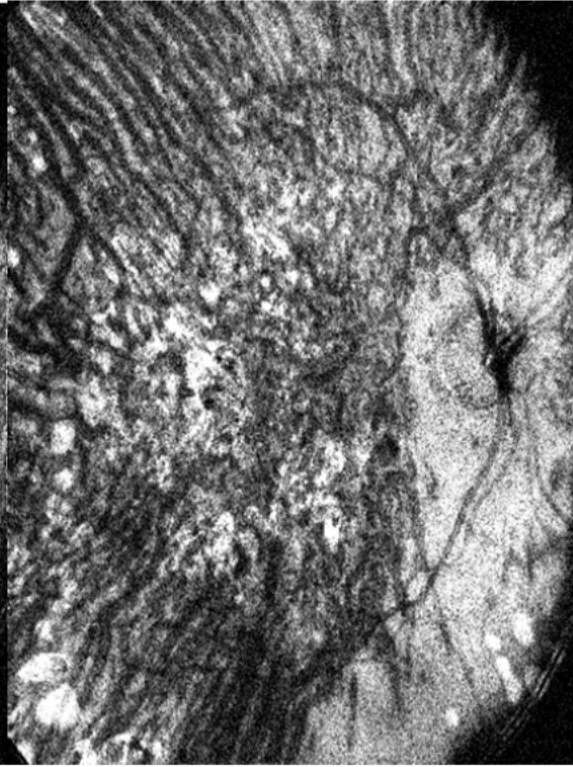
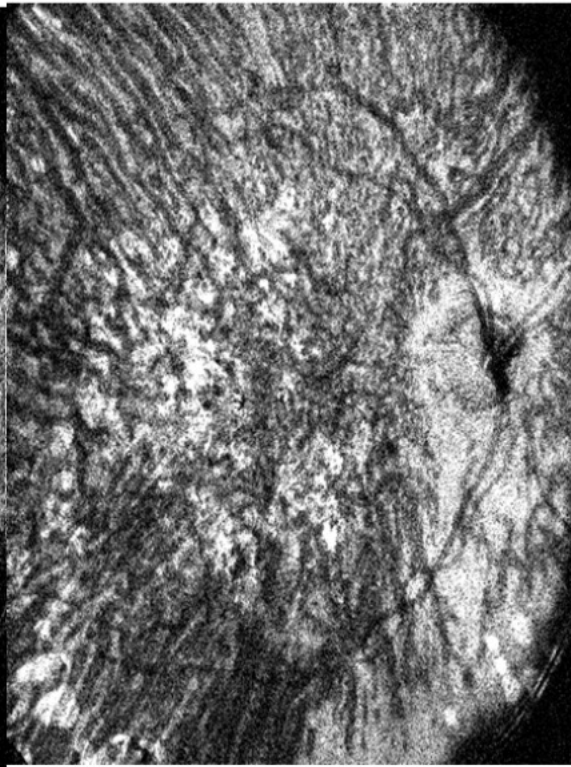
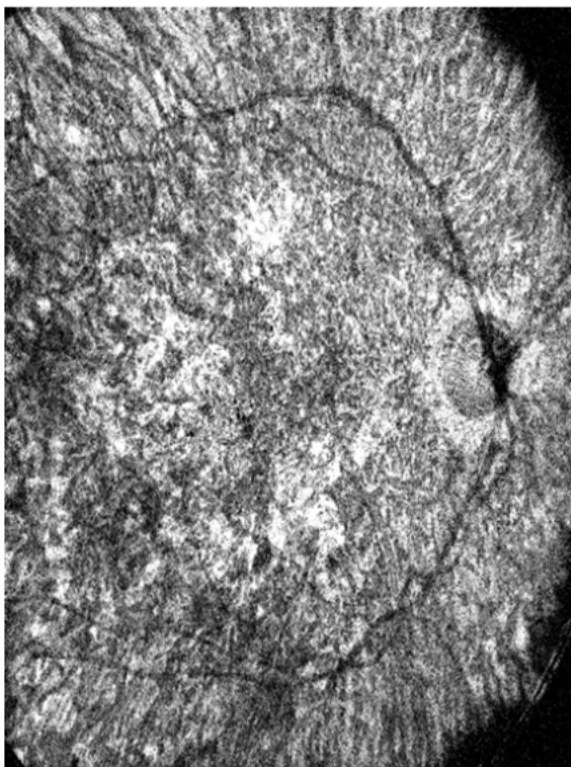
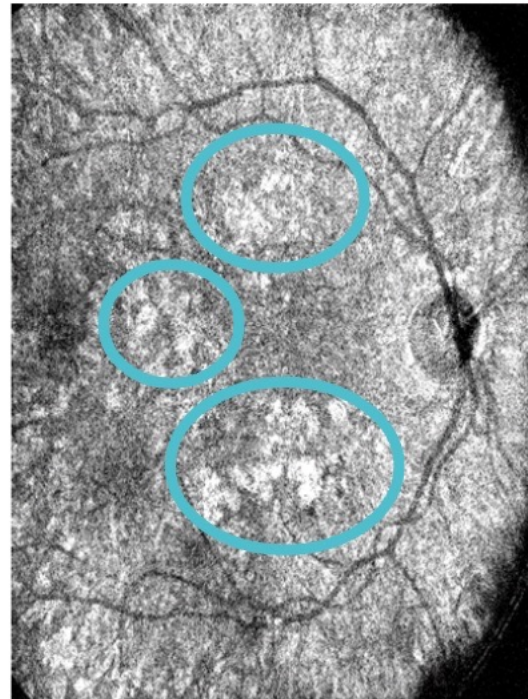
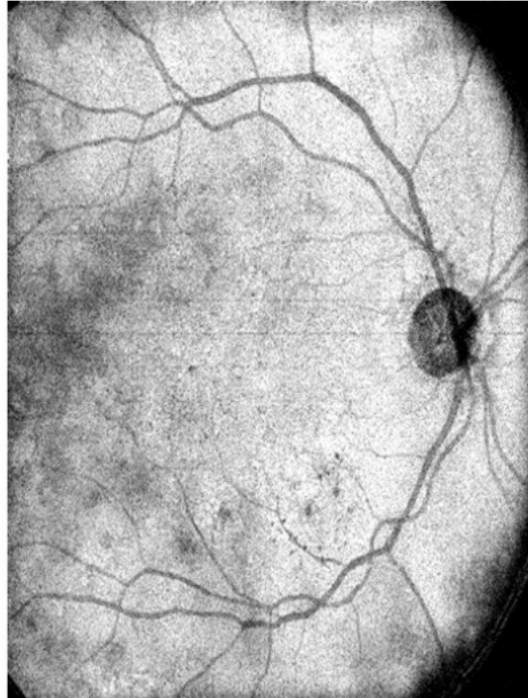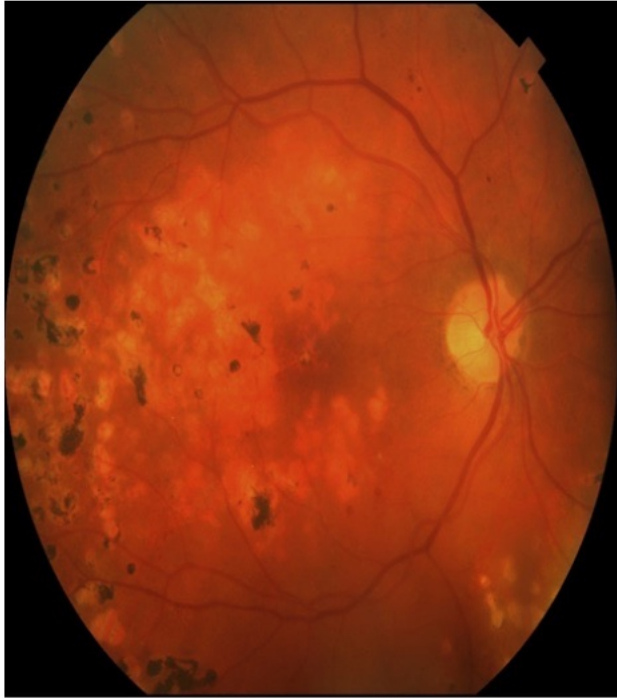


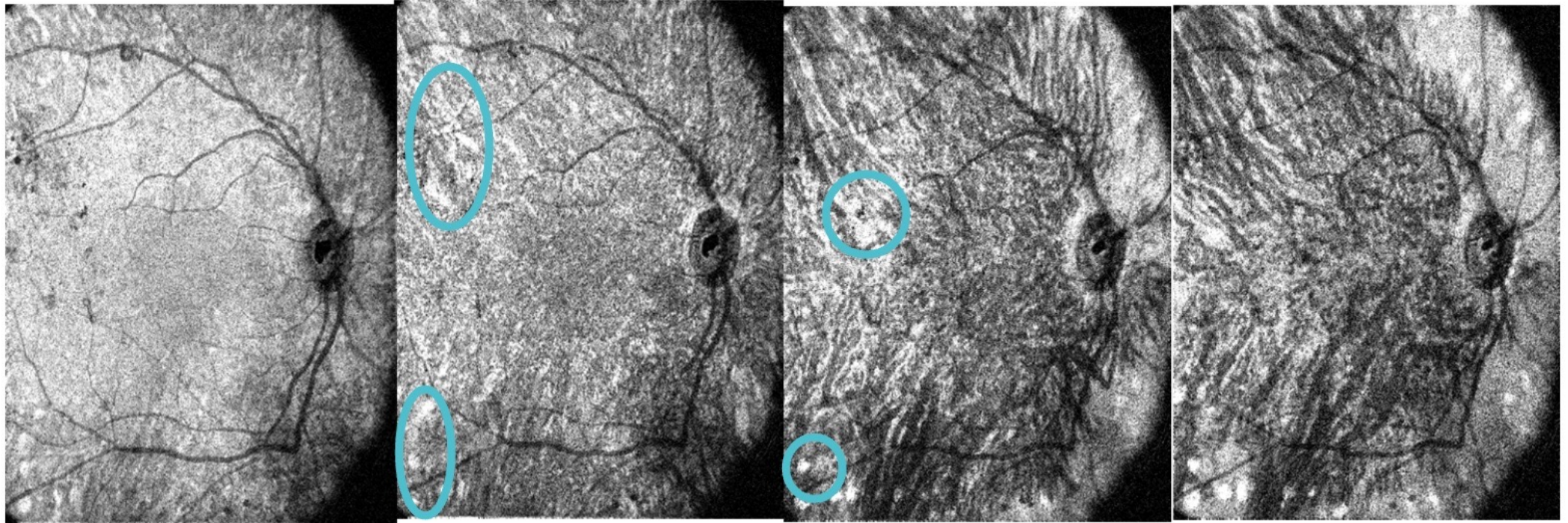
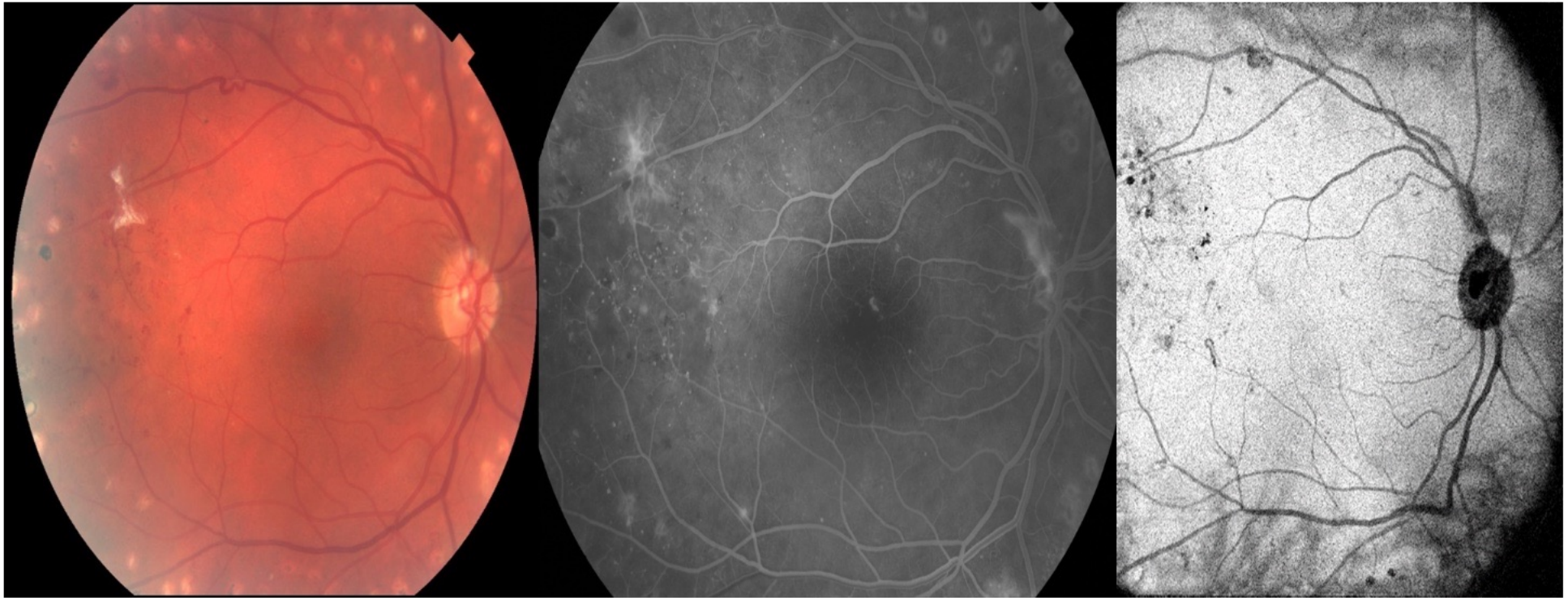
○ Capillary dropout

Focal dilation and narrowing ○



Capillary dropout





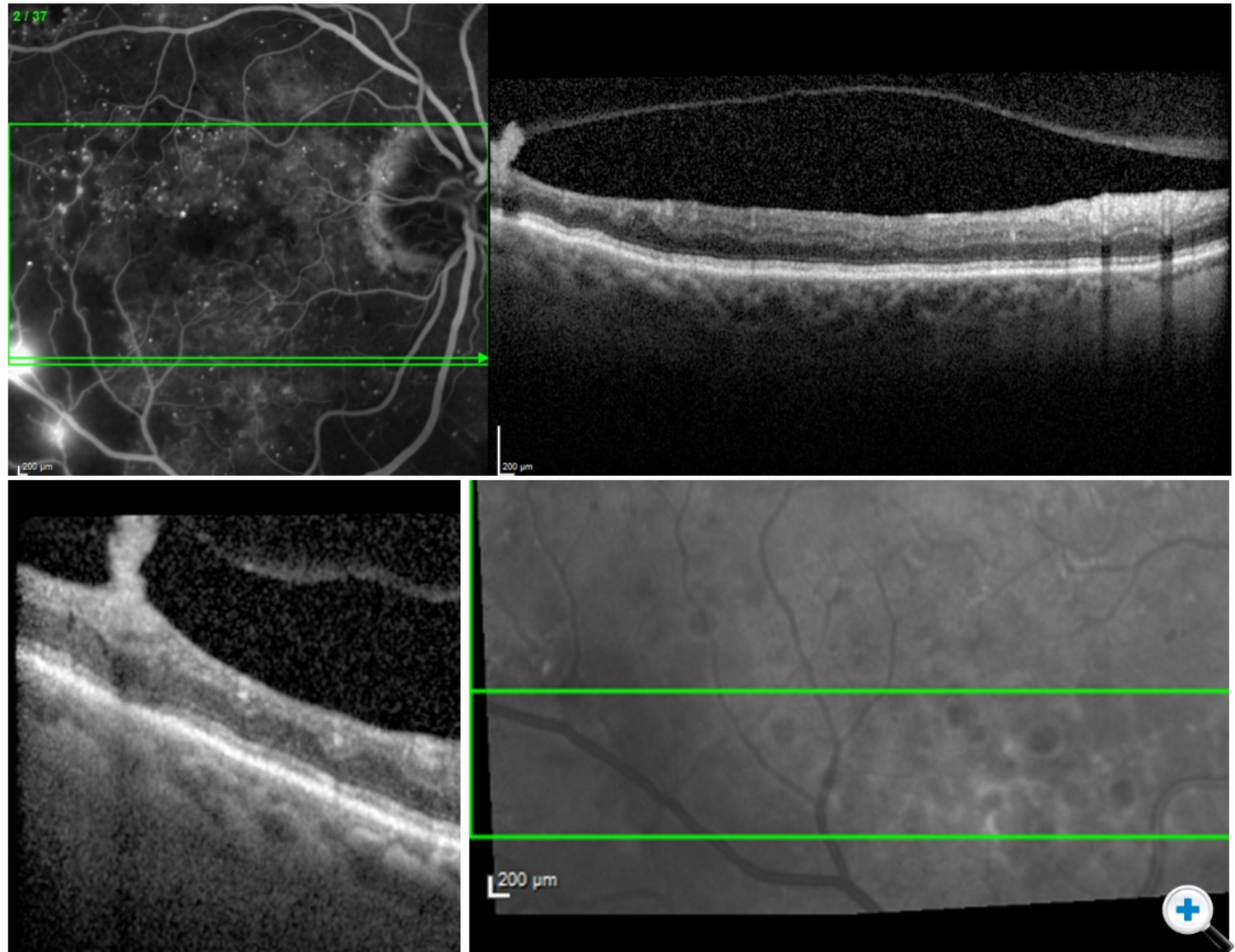
Combining Imaging

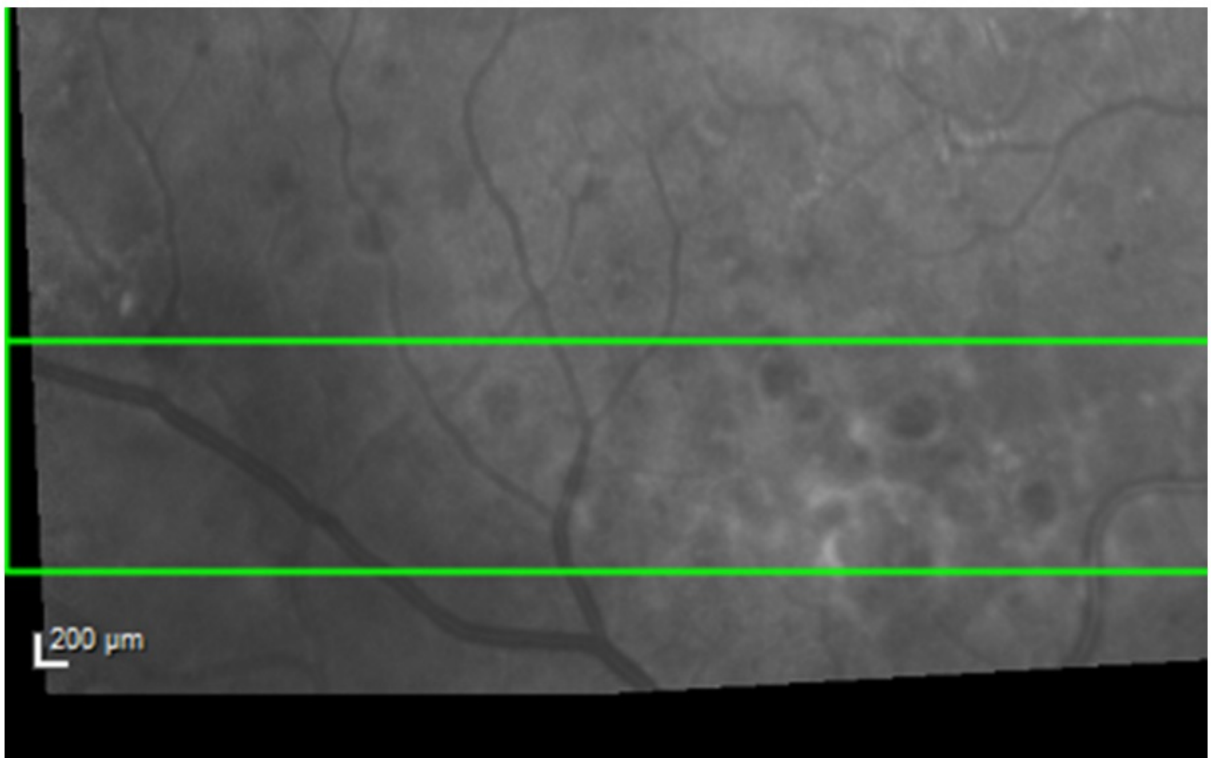
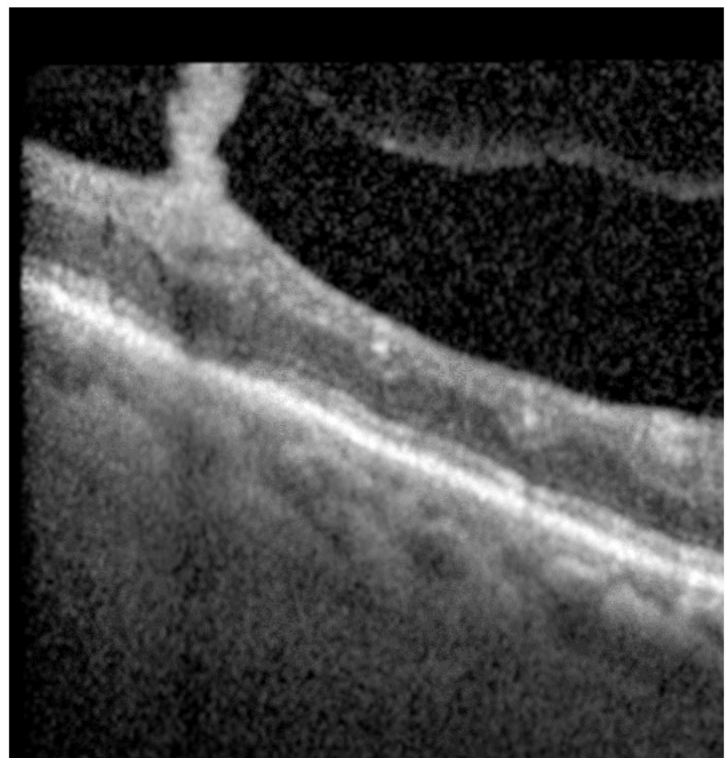
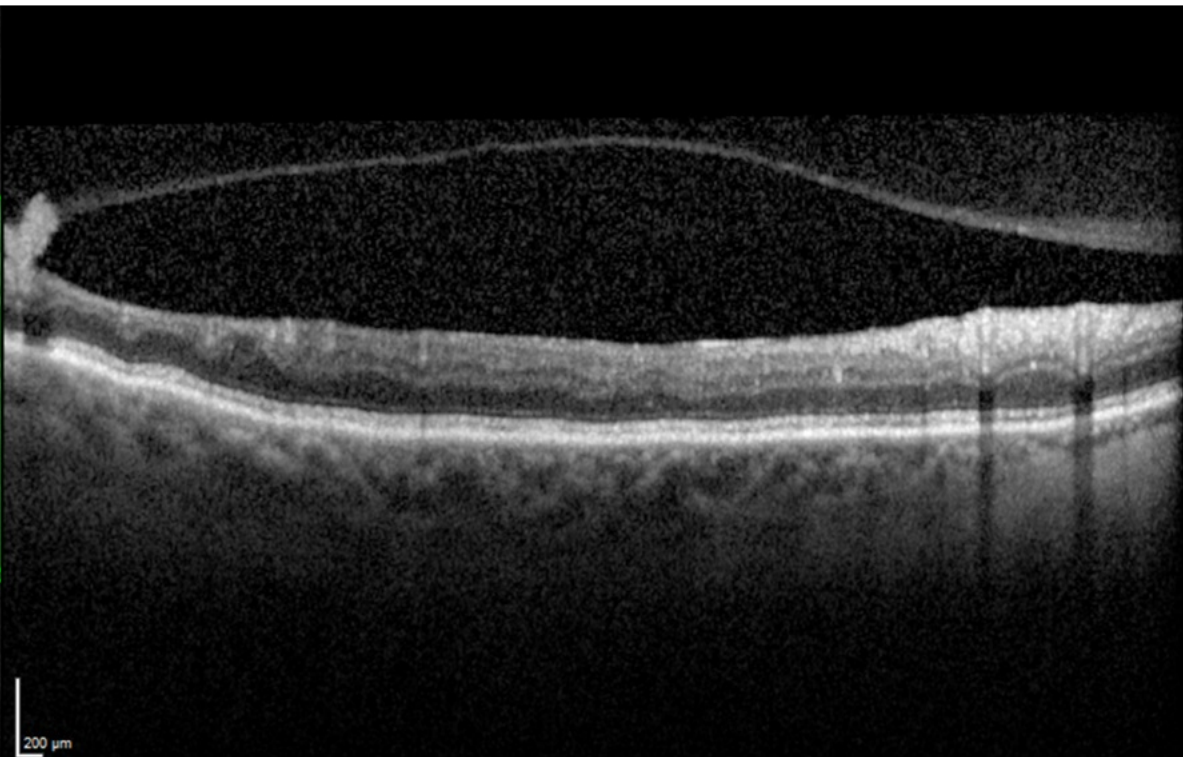
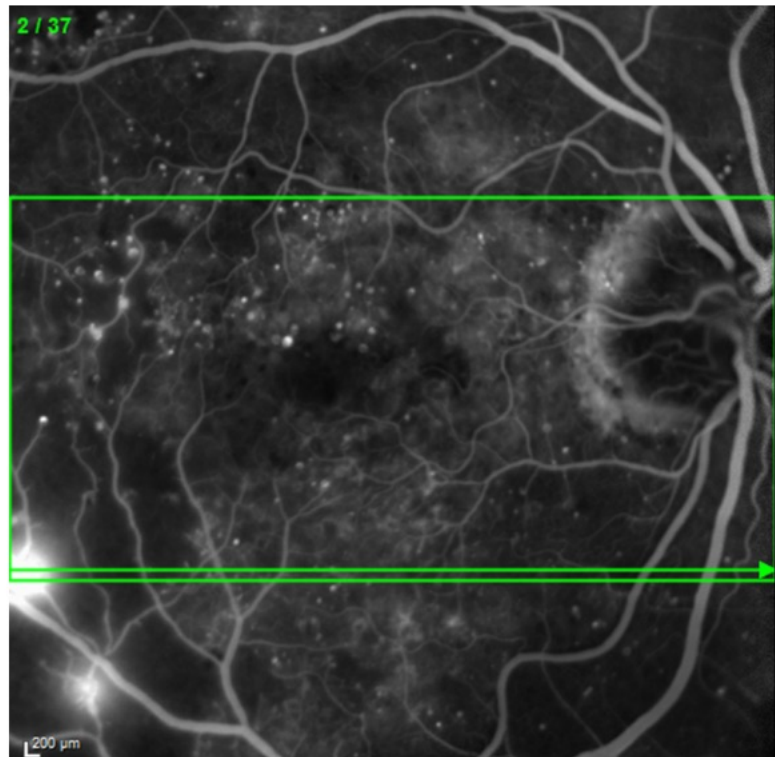
Combining imaging is a very useful application.

For example, a fluorescein angiogram might show what could be new vessels, or intense IRMA leakage.

Taking an OCT scan through the area, one can see new vessels proliferating.

Thus, multimodal imaging, combining information from fluorescein angiography and OCT provides a great deal more information about what is occurring.

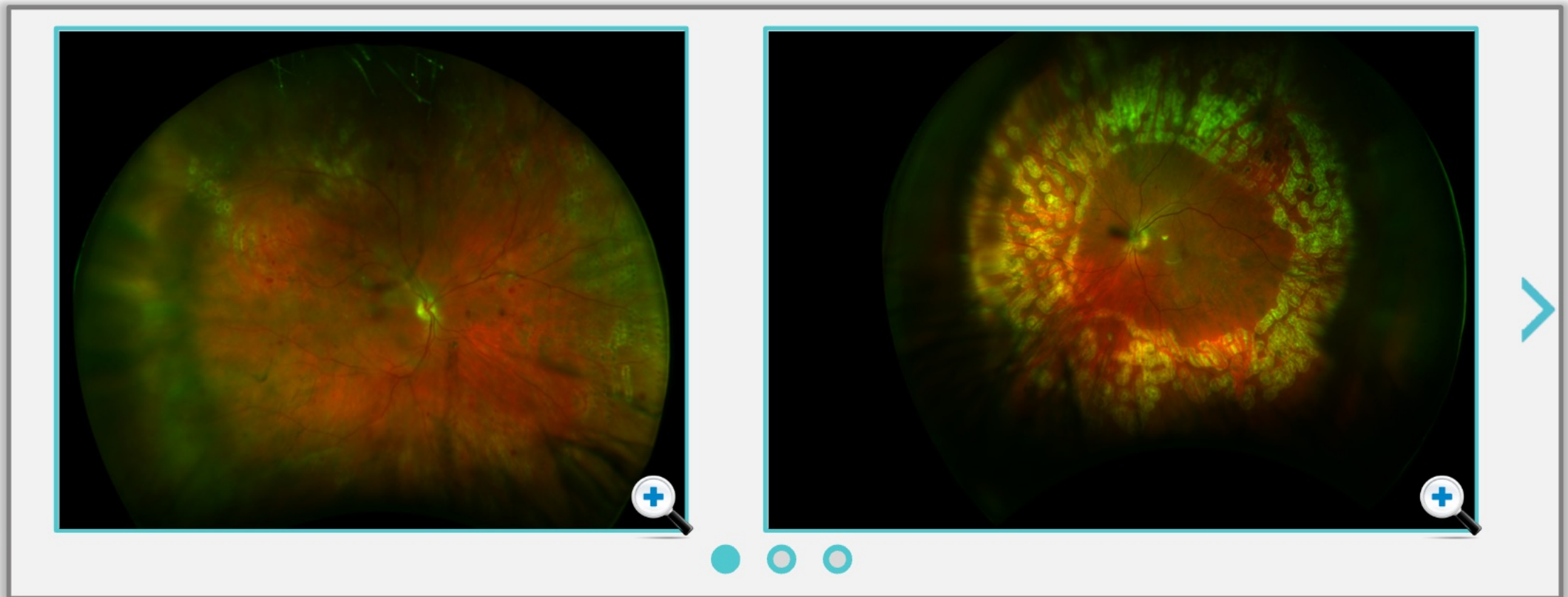




Ultra-Widefield Imaging

Another new development in imaging the pathophysiology of diabetic eye disease is ultra-widefield imaging.

The key benefit with ultra-widefield imaging is in screening patients. Especially **in rapid, high-throughput clinics**, it can be difficult to photograph and review images.

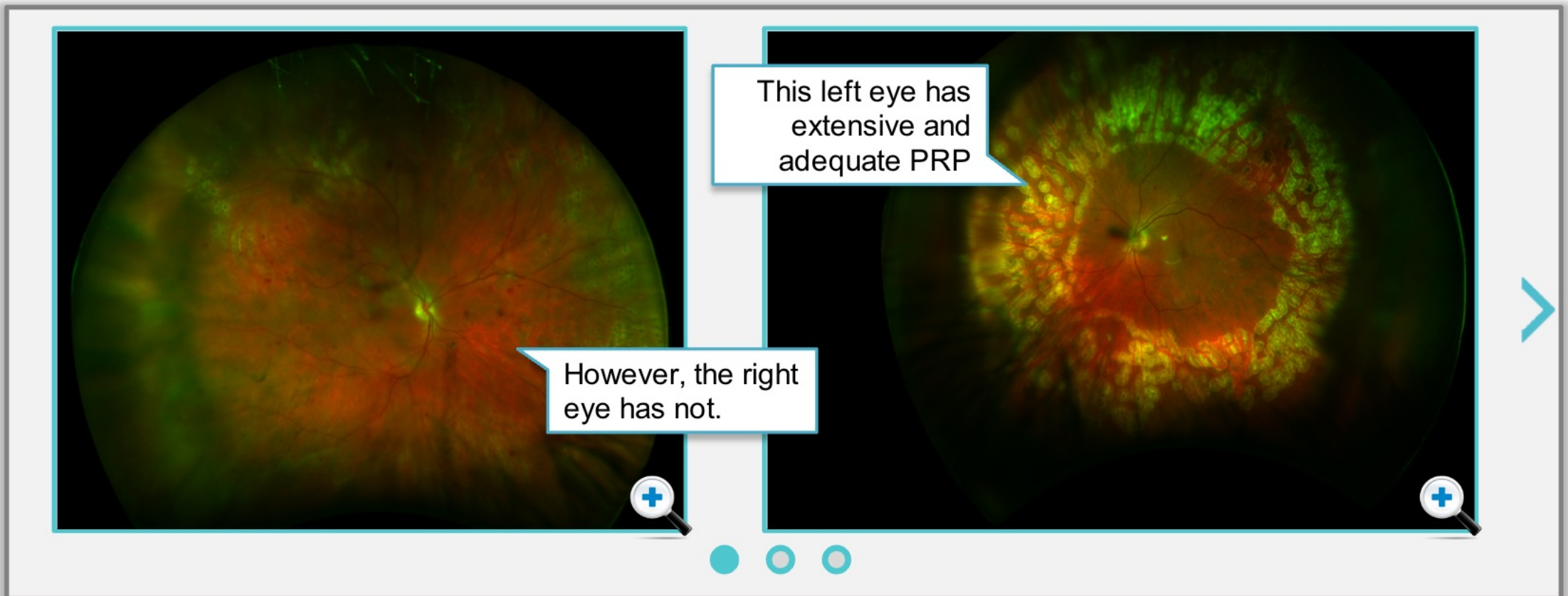


Ultra-Widefield Imaging

Another new development in imaging the pathophysiology of diabetic eye disease is ultra-widefield imaging.

The key benefit with ultra-widefield imaging is in screening patients. Especially **in rapid, high-throughput clinics**, it can be difficult to photograph and review images.

However, with ultra-widefield imaging can help you **view the retina and make decisions more quickly**.





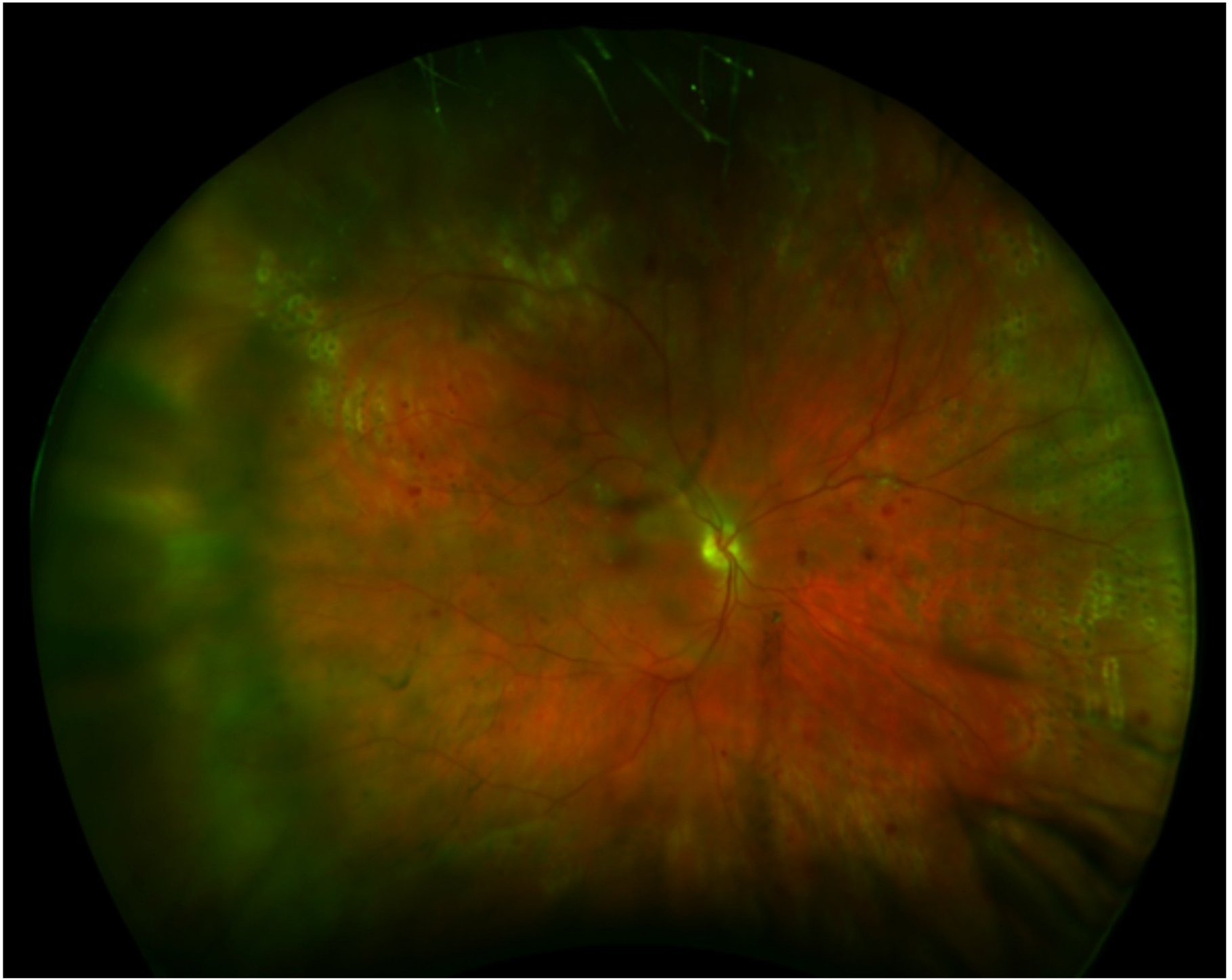
U

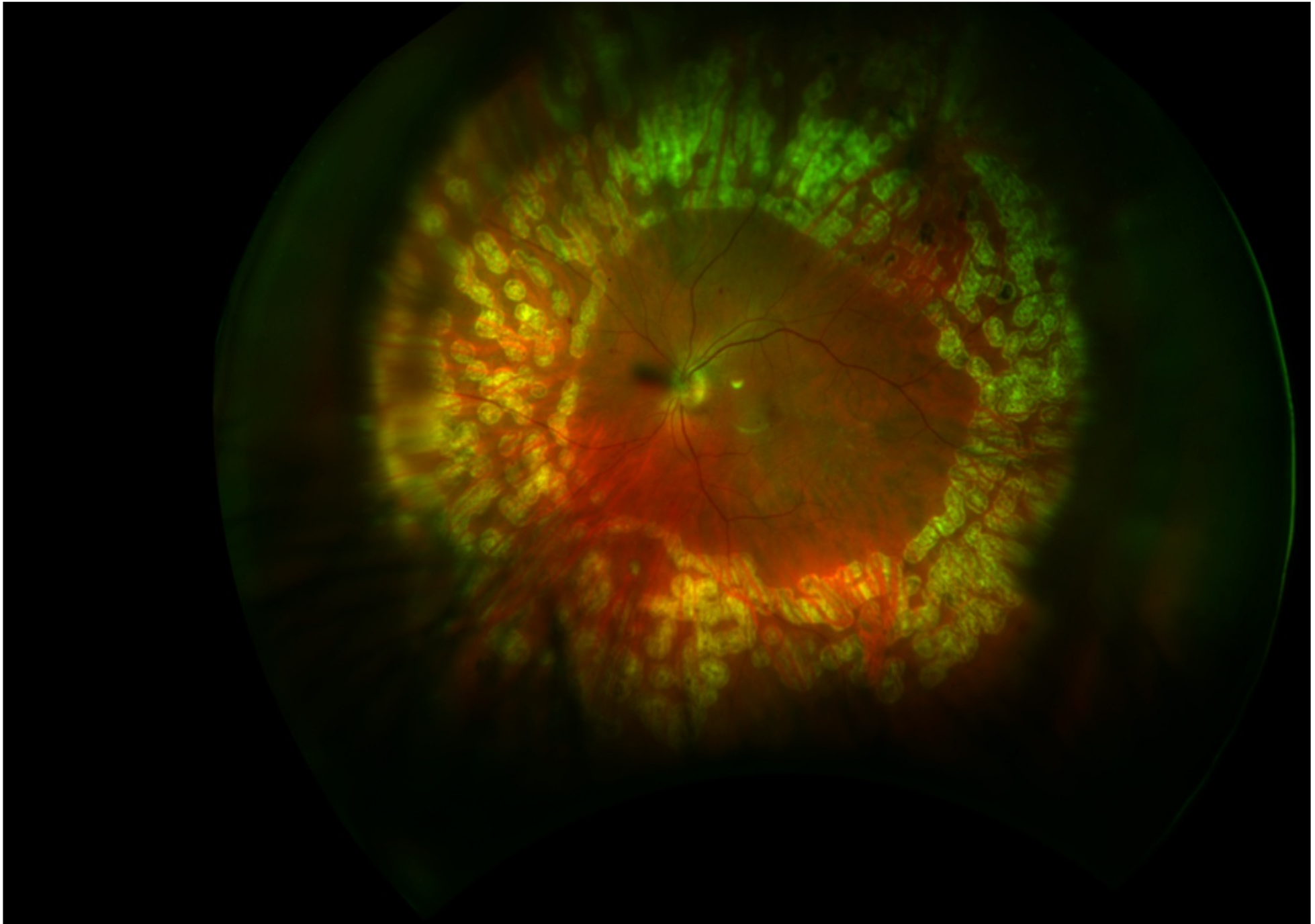
An

Th

it c

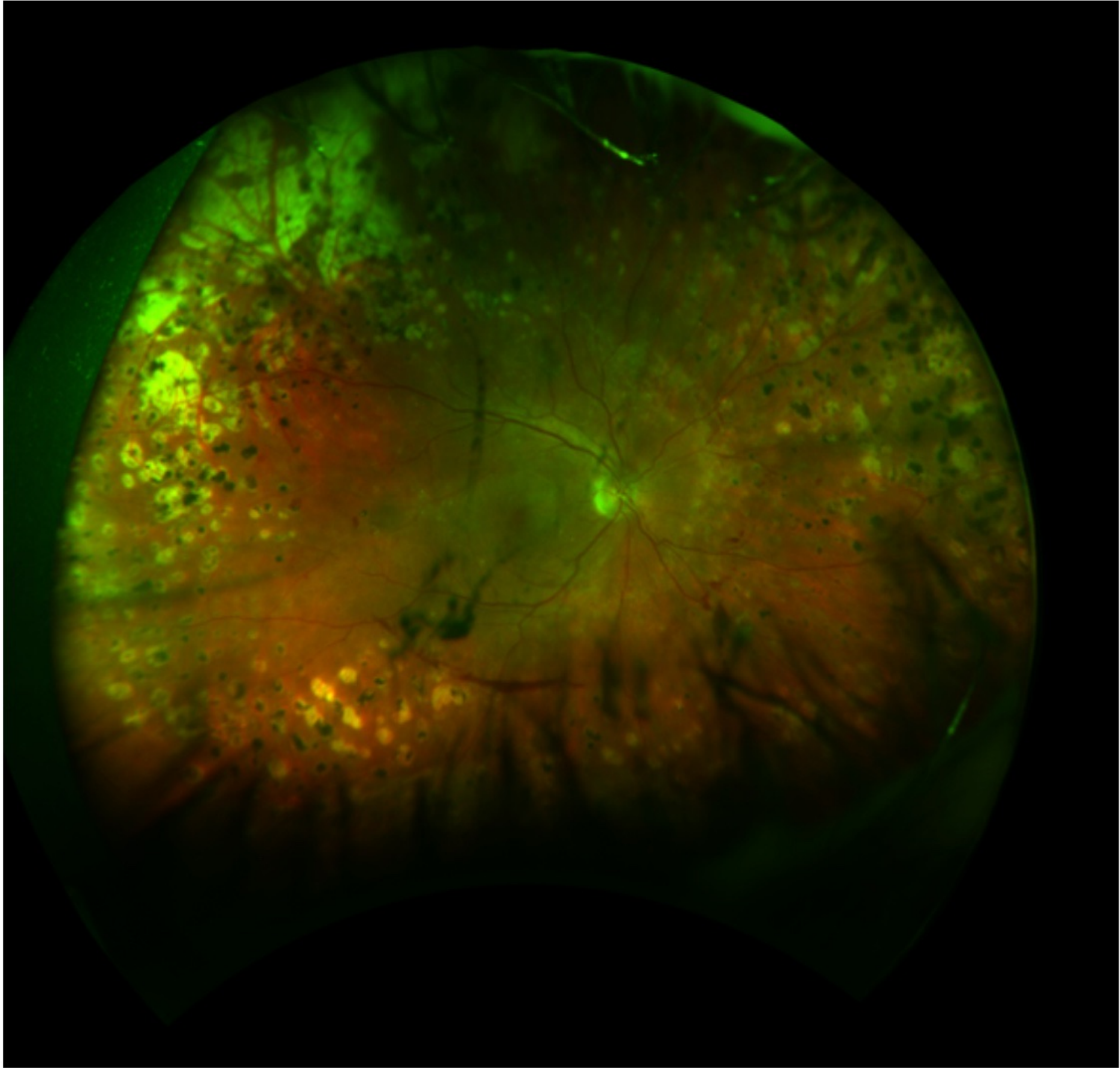
Ho





This left eye has extensive and adequate PRP





U

An

Th

it c

Ho

ine



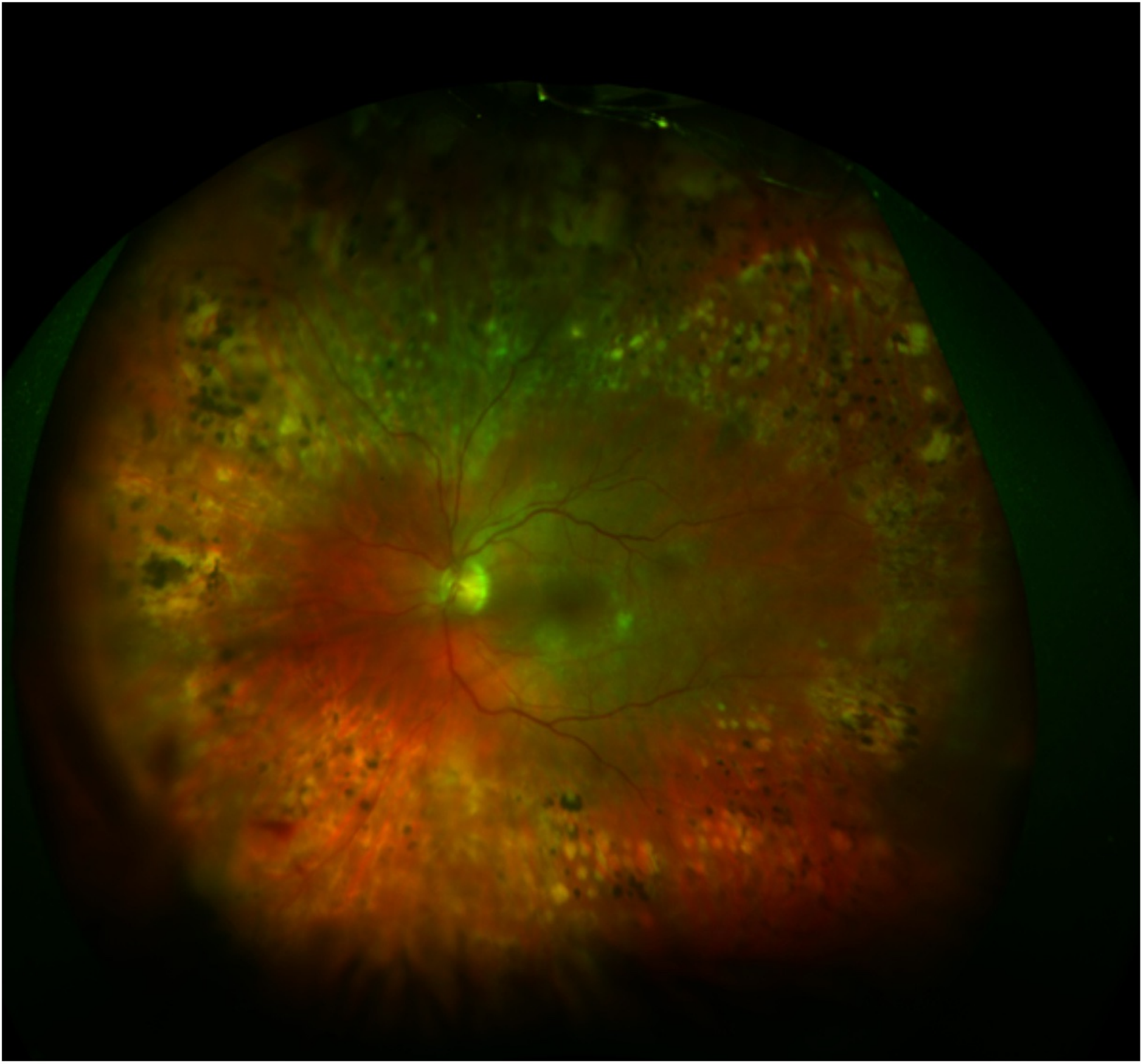


U

An

Th
it c

Ho





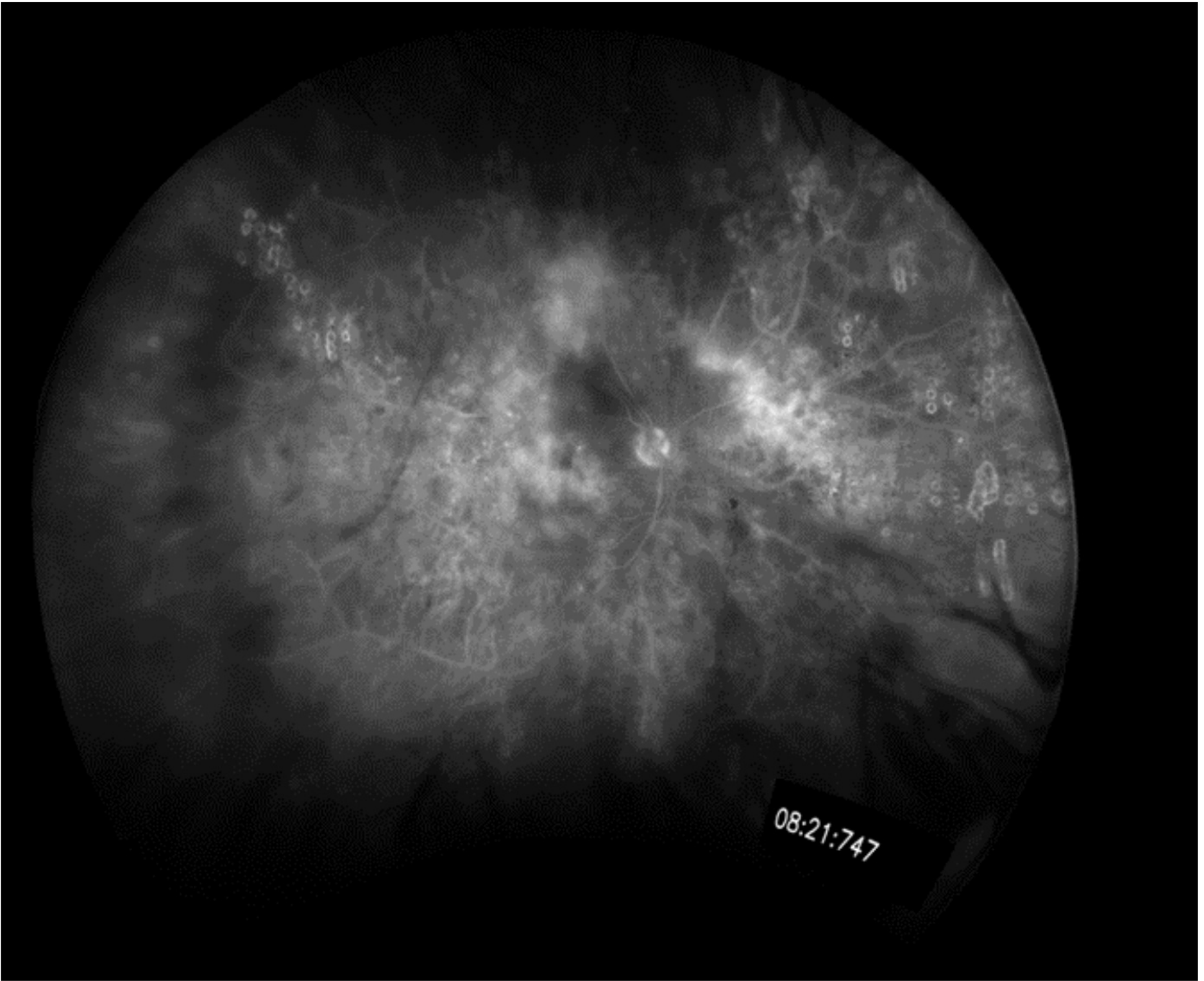
U

An

Th

it c

Ho



08:21:747



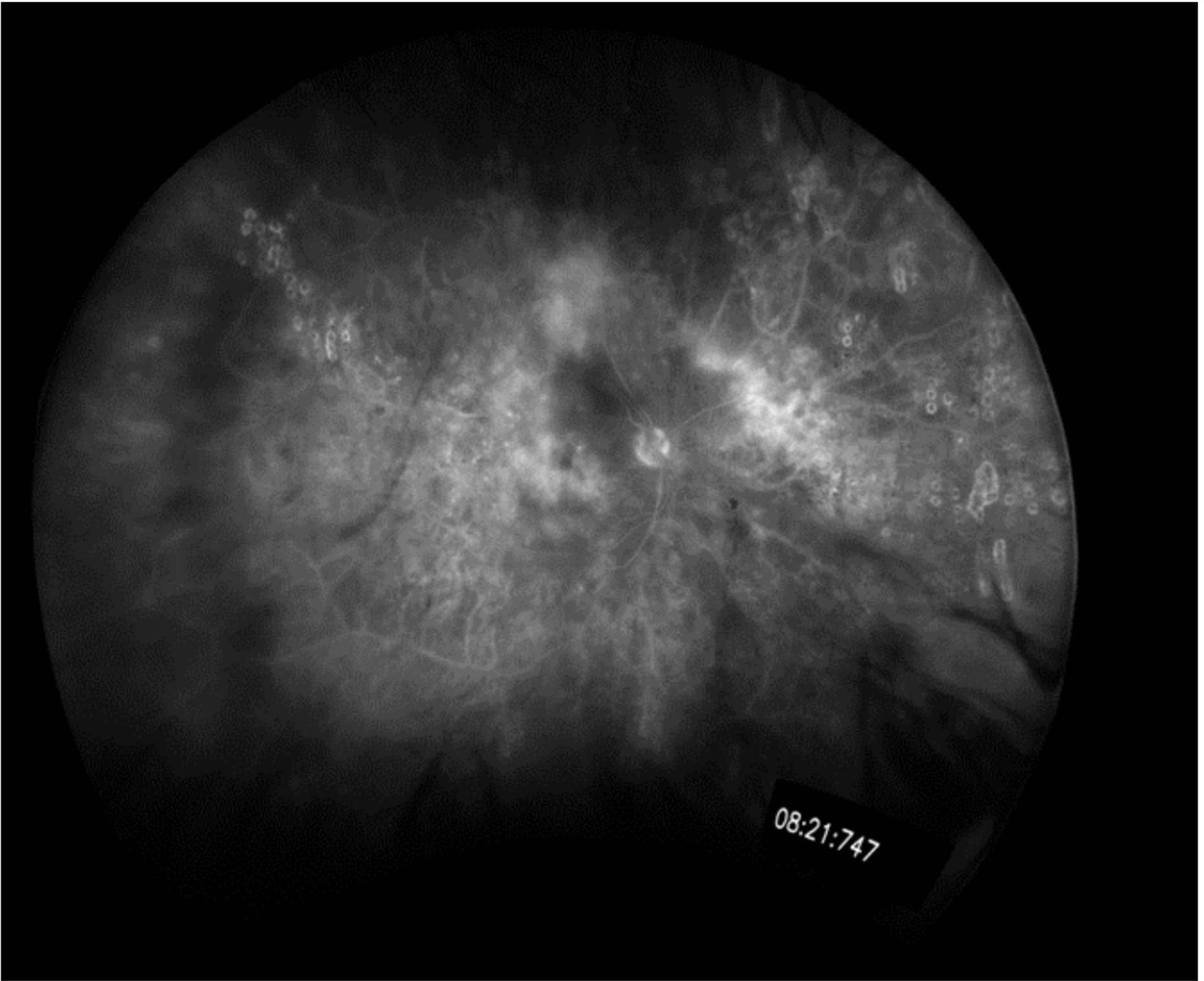
U

An

Th

it c

Ho



08:21:747



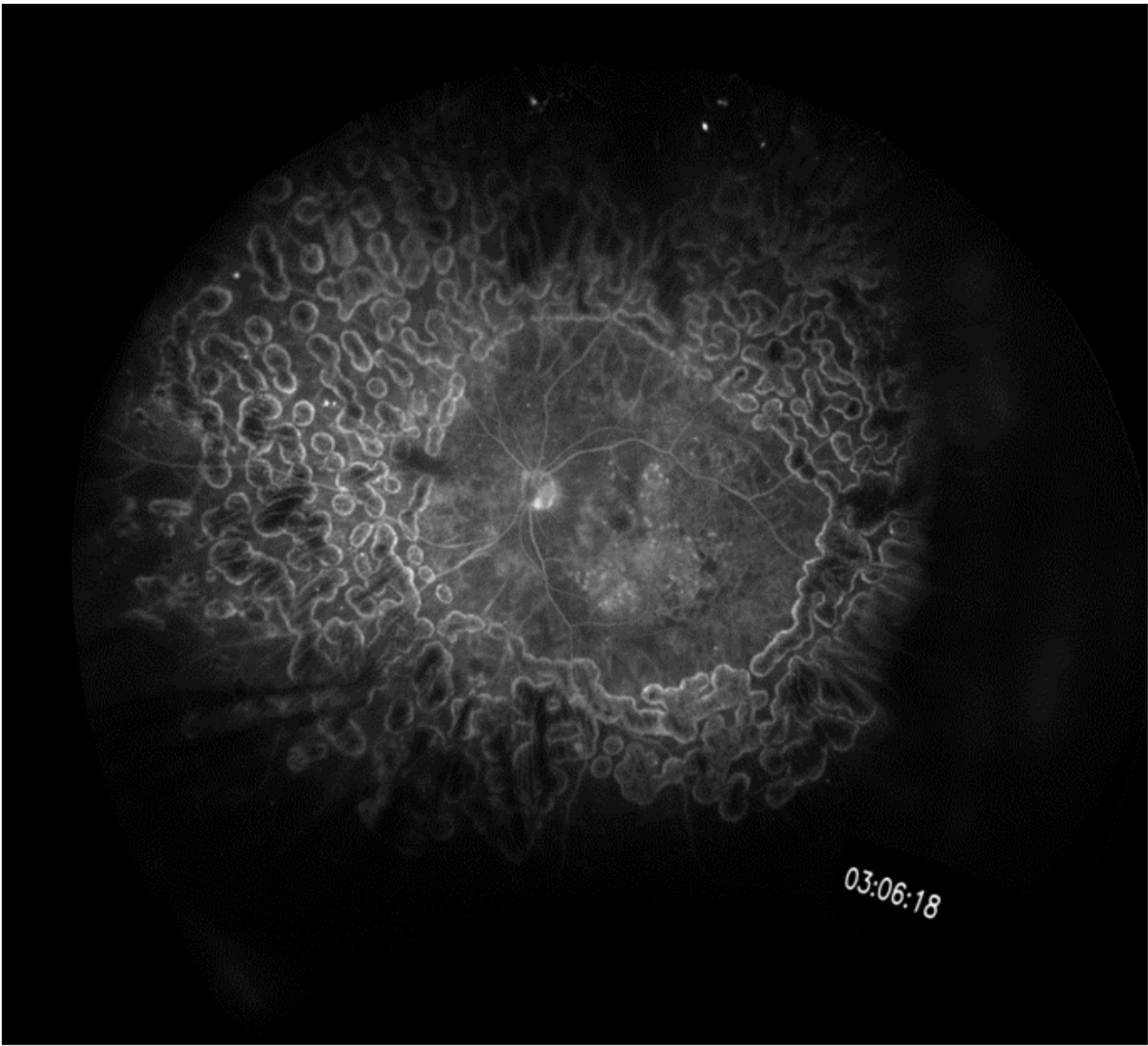
U

An

Th

it c

Ho



03:06:18

Imaging Pathophysiology of DR: Quick Quiz

Next, you'll be asked a series of questions about imaging the pathophysiology of diabetic retinopathy.

Don't worry, your answers are not used for assessment. They are intended simply to help you better understand how much you have learned.

After the quiz, you'll get a chance to review your answers, and some advice based on your attempt.



Click the Next button to continue.

Summary

Colour fundus imaging has been used to develop practical, structured, graded classification systems to:

- Demonstrate the features of diabetic eye disease
- Identify the stages of the disease, based on the presence and quantity of these features
- Quantify risk of diabetic macular edema developing, based on the severity of diabetic retinopathy

These methods are good for diagnosis and risk assessment of disease progression. However, using multimodal imaging has allowed us to view the pathophysiology of the disease:

Fluorescein angiography shows us vasculature changes

- Changes in vascular caliber
- Areas of capillary dropout
- Areas of non-perfusion
- Microaneurysms, lighting up the out-pouchings
- Intraretinal microvascular abnormalities (IRMA)
- Areas of new vessel formation and shunt vessel formation

OCT shows us 2-dimensional architecture of the retina

- Exudates
- Haemorrhages
- Edema
- Microaneurysms
- Deposits
- Outer retinal layers/ structure
- Inner retina
- Inner/ outer retina junction
- Thickness maps

Comparing images from multiple sources (colour fundus, FA, OCT) helps to provide greater information about the manifestations seen.

Further new imaging technologies (multi-colour channel imaging, ultra-widefield) will offer more information in ways that are more efficient.