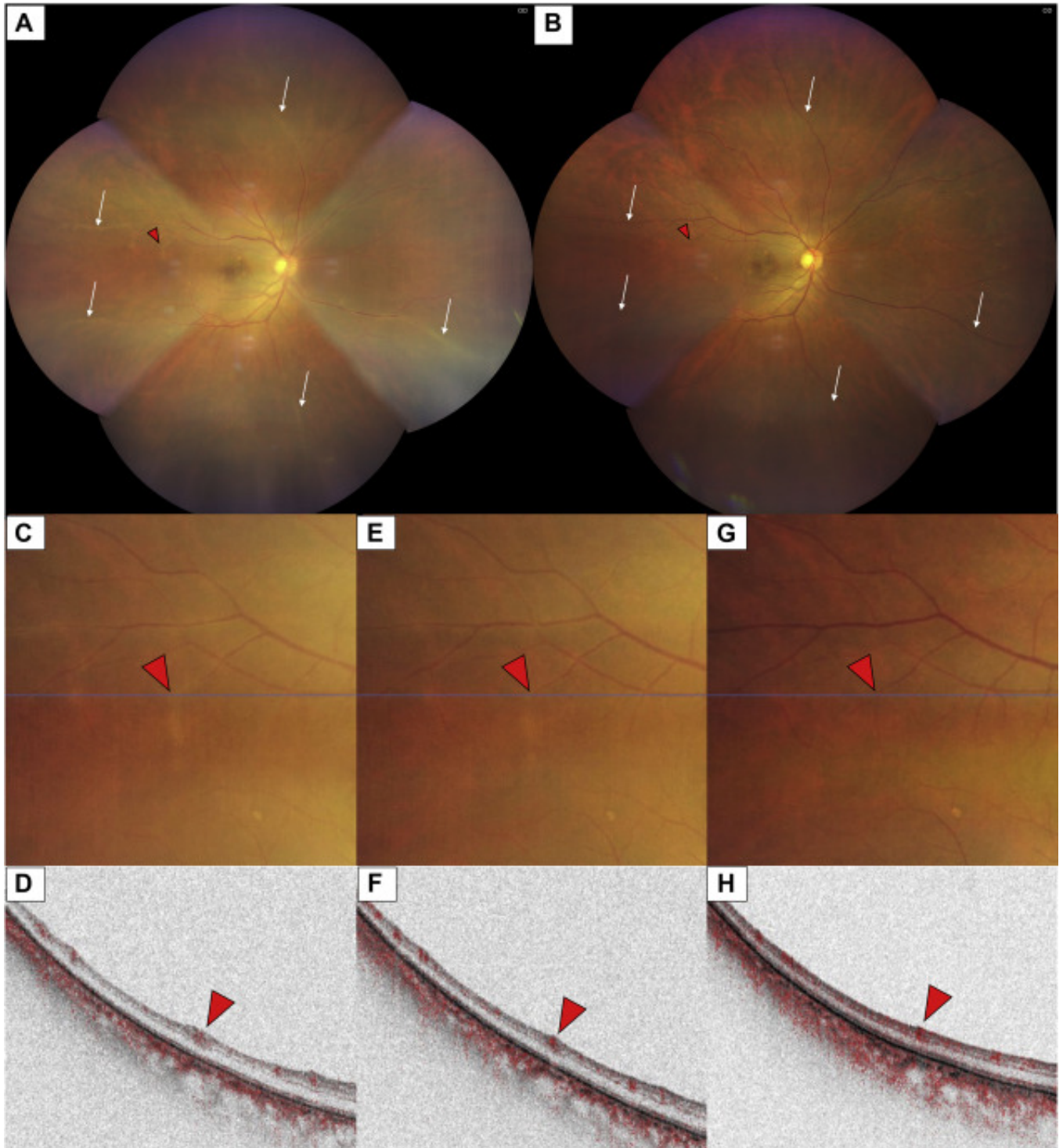


Early Recovery from Vasculitis after Brolucizumab with Prompt Steroid Treatment



A 72-year-old man with 20/30 vision in the right eye who received an intravitreal injection of brolucizumab for refractory polypoidal choroidal vasculopathy noted sudden vision deterioration to 20/200 at 10 days.

Fundus examination revealed disseminated retinal vasculitis (arrows) with vitreous haze (**A**) that resolved after sub-Tenon injection of triamcinolone acetonide (20 mg) and oral prednisolone (30 mg/day) (**B**). Rapid resolution of perivenous whitening and recovery of the flow signals (arrowheads) on B-scan OCT angiography was demonstrated before treatment (**C, D**), on day 1 after treatment (**E, F**), and at 1 month after treatment (**G, H**). Vision recovered quickly to 20/50 on day 1, and 20/30 at 1 month.

Article info

Copyright

© 2021 by the American Academy of Ophthalmology