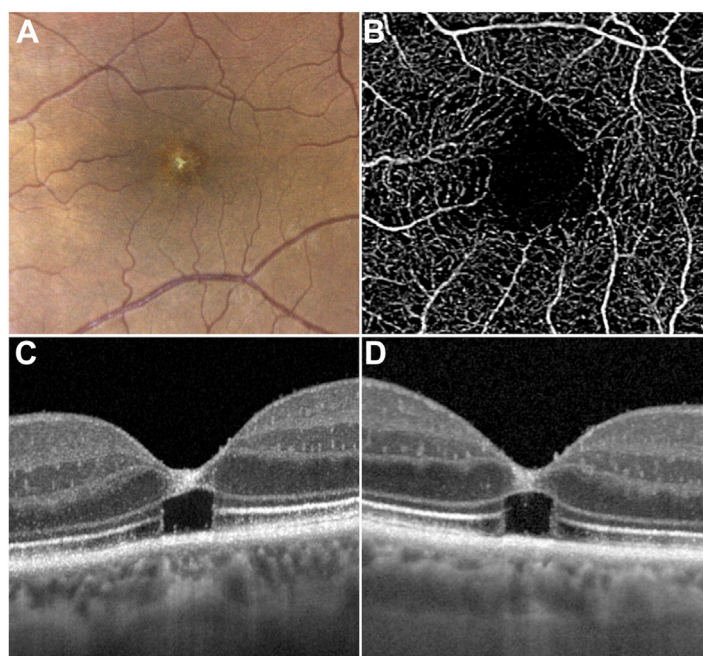


23. Jessen NA, Munk AS, Lundgaard I, Nedergaard M. The glymphatic system: a beginner's guide. *Neurochem Res.* 2015;40:2583–2599.
24. Rofagha S, Bhisitkul RB, Boyer DS, et al. Seven-year outcomes in ranibizumab-treated patients in ANCHOR, MARINA, and HORIZON: a multicenter cohort study (SEVEN-UP). *Ophthalmology.* 2013;120:2292–2299.
25. Martin DF, Shaffer J, Ying GS, et al. Five-year outcomes with anti-vascular endothelial growth factor treatment of neovascular age-related macular degeneration: the Comparison of Age-Related Macular Degeneration Treatments Trials. *Ophthalmology.* 2016;123:1751–1761.
26. Arrigo A, Romano F, Aragona E, et al. Optical coherence tomography angiography can categorize different subgroups of choroidal neovascularization secondary to age-related macular degeneration. *Retina.* 2020;40:2263–2269.
27. Arrigo A, Aragona E, Di Nunzio C, et al. Quantitative optical coherence tomography angiography parameters in type 1 macular neovascularization secondary to age-related macular degeneration. *Transl Vis Sci Technol.* 2020;9:48. <https://doi.org/10.1167/tvst.9.9.48>.
28. Arrigo A, Aragona E, Bordato A, et al. Morphological and functional relationship between OCTA and FA/ICGA quantitative features in AMD-related macular neovascularization. *Front Med (Lausanne).* 2021;8:758668. <https://doi.org/10.3389/fmed.2021.758668>.
29. Arrigo A, Aragona E, Bordato A, et al. High reflectivity and low reflectivity properties on OCTA influence the detection of macular neovascularization in AMD. *Front Phys.* 2021;9. <https://doi.org/10.3389/fphy.2021.694035>.
30. Chakravarthy U, Havilio M, Syntosi A, et al. Impact of macular fluid volume fluctuations on visual acuity during anti-VEGF therapy in eyes with nAMD. *Eye (Lond).* 2021;35:2983–2990.

Pictures & Perspectives



Tamoxifen Retinopathy on High-Resolution OCT

A woman in her 80s noted gradually reduced central vision bilaterally. Her medical history included breast cancer managed with 2 cycles of tamoxifen (20 mg/day) spanning 8 years. She denied activities associated with photic maculopathy or the use of inhaled nitrites. Genetic screening for retinal dystrophies was negative. Clinical findings were symmetric with central pigmentary alterations (A, left eye). Foveal vascular structure imaged with OCT angiography showed no evidence of macular telangiectasia (B, left eye). High-resolution OCT (C, left eye; D, right eye) demonstrated cavitory loss of cone inner and outer segments with overlying hyperreflectivity. (Magnified version of Figure A-D is available online at www.ophtalmologyretina.org).

JACQUES BIJON, MD^{1,2}

GREGORY STEIN, MD³

K. BAILEY FREUND, MD^{1,2}

¹Vitreous Retina Macula Consultants of New York, New York, New York; ²Department of Ophthalmology, New York University Grossman School of Medicine, New York, New York; ³Department of Ophthalmology, Columbia University Medical Center, New York, New York