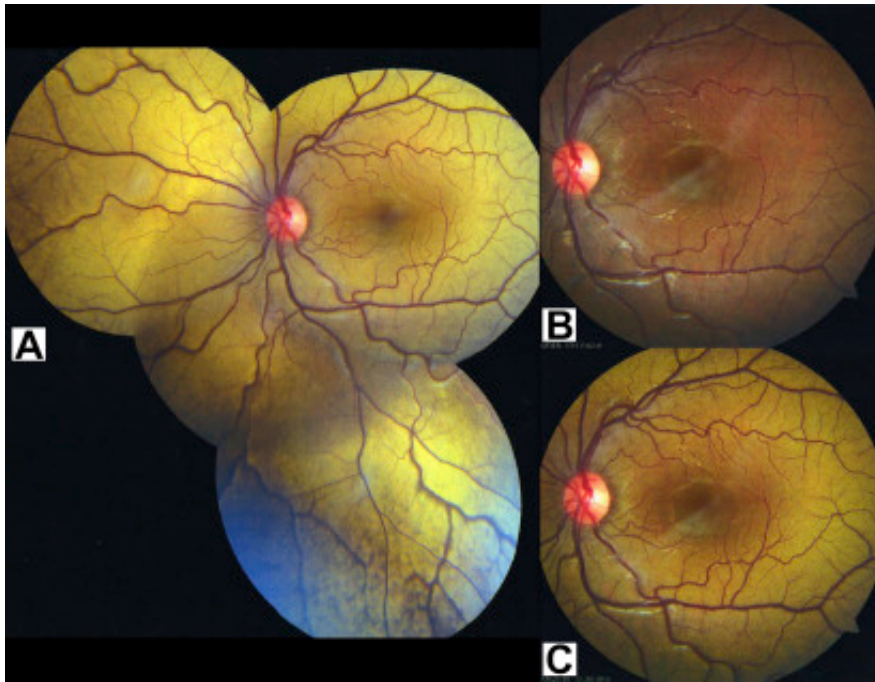


Oguchi Disease: The Chameleon in the Retina



A 5-year-old girl demonstrated defective dim light vision at presentation. Although had no significant family or systemic history, she had normal day light vision. **A**, On fundus examination, both eyes showed a distinct bright golden sheen. **B**, After prolonged overnight dark adaptation, the color of the fundus normalized and the sheen disappeared completely. **C**, On further light adaptation of 30 minutes, both retina remarkably reverted to their original state with a bright golden reflex. This patient was diagnosed to have Oguchi disease because of the presence of the Mizuo–Nakamura phenomenon.