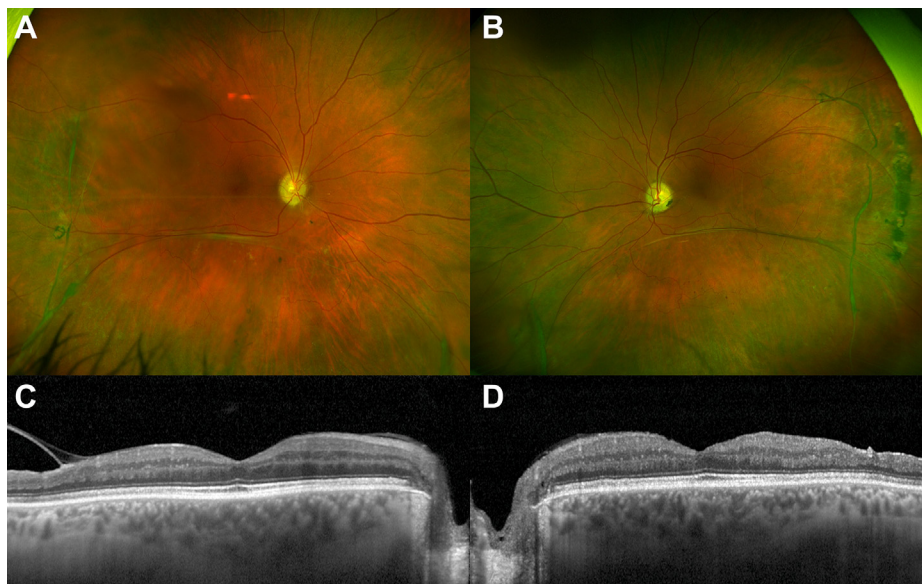


38. Rush R, Sheth S, Surka S, et al. Postoperative perfluoro-n-octane tamponade for primary retinal detachment repair. *Retina*. 2012;32:1114–1120.
39. Bilgin AB, Dogan ME, Aysun B, Apaydin KC. Pars plana vitrectomy with or without intraoperative 360° peripheral endolaser for rhegmatogenous retinal detachment treatment. *Int Ophthalmol*. 2019;39:1687–1694.
40. Dirani A, Antaki F, Rhéaume MA, et al. 360-degree intraoperative laser retinopexy for the prevention of retinal detachment in patients treated with primary pars plana vitrectomy. *Graefes Arch Clin Exp Ophthalmol*. 2020;258:249–256.
41. Farahvash A, Popovic MM, Eshtiaghi A, et al. Combined versus sequential phacoemulsification and pars plana vitrectomy: a meta-analysis. *Ophthalmol Retina*. 2021;5:1125–1138.
42. Braithwaite T, Calvert M, Gray A, et al. The use of patient-reported outcome research in modern ophthalmology: impact on clinical trials and routine clinical practice. *Patient Relat Outcome Meas*. 2019;10:9–24.
43. Potic J, Bergin C, Giacuzzo C, et al. Application of modified NEI VFQ-25 after retinal detachment to vision-related quality of life. *Retina*. 2021;41:653.
44. Abdelkader AME, Abouelkheir HY. Supine positioning after vitrectomy for rhegmatogenous retinal detachments with inferior retinal breaks. *Int J Retina Vitreous*. 2020;6:41.
45. Page MJ, McKenzie JE, Bossuyt PM, et al. The PRISMA 2020 statement: an updated guideline for reporting systematic reviews. *BMJ*. 2021;372. <https://doi.org/10.1136/bmj.n71>. PMID: 33782057; PMCID: PMC8005924.
46. Azuara-Blanco A, Carlisle A, O'Donnell M, et al. Design and conduct of randomized clinical trials evaluating surgical innovations in ophthalmology: A systematic review. *Am J Ophthalmol*. 2023;248:164–175.

Pictures & Perspectives



X-linked Retinoschisis with Near-Normal Macular Structure and Function

A 52-year-old man with 20/25 visual acuity in both eyes presented with extensive peripheral retinoschisis (A, B). Macular OCT imaging showed no obvious alterations that would usually allow the diagnosis of X-linked retinoschisis (XLRS); subtle alterations included slightly irregular foveal contour of the left macula and mild retinal thinning temporally in both eyes (C, D). Dark-adapted maximum responses on full-field electroretinography were electronegative. Genetic analysis identified the pathogenic variant c.304C>T, p.(Arg102Trp) in the *retinoschisin/RS1* gene, which was also present in his brother who presented with macular changes typical for XLRS. Senile, degenerative retinoschisis is a possible misdiagnosis in patients with XLRS with normal macula. (Magnified version of Figure A–D is available online at www.ophtalmologyretina.org).

PETER KIRALY, MD¹

M. DOMINIK FISCHER, MD, DPHIL^{1,2,3}

PETER CHARBEL ISSA, MD, DPHIL^{1,2}

¹Oxford Eye Hospital, Oxford University Hospitals NHS Foundation Trust, Oxford, United Kingdom; ²Nuffield Laboratory of Ophthalmology, Nuffield Department of Clinical Neurosciences, University of Oxford, Oxford, United Kingdom; ³Centre for Ophthalmology, University Hospital Tübingen, Tübingen, Germany