

Focal scleral nodule

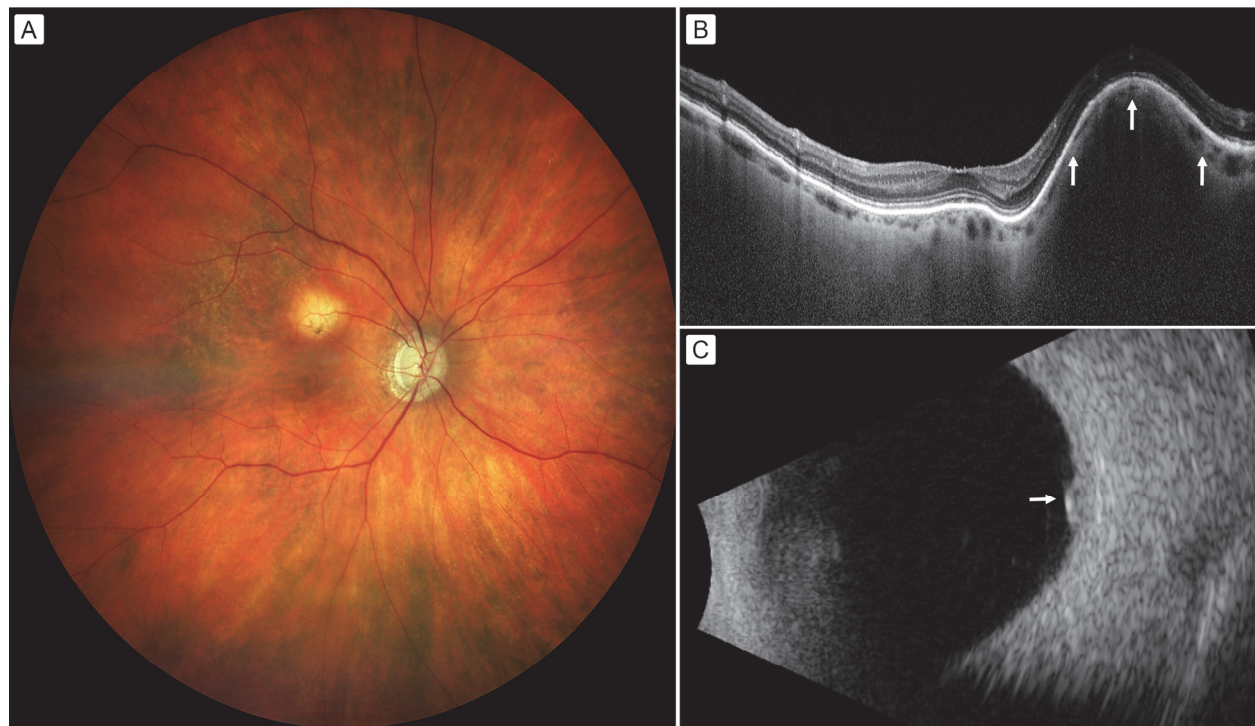
June 28, 2022

DJO vol. 28, no. 2

Nicholas E. Kalafatis, MD, Ocular Oncology Service, Wills Eye Hospital, Thomas Jefferson University, Philadelphia, Pennsylvania

Andrea Laiton, MD, Ocular Oncology Service, Wills Eye Hospital, Thomas Jefferson University, Philadelphia, Pennsylvania

[Carol L. Shields](#), MD, Ocular Oncology Service, Wills Eye Hospital, Thomas Jefferson University, Philadelphia, Pennsylvania



DJO Digital Journal of Ophthalmology
www.djo.harvard.edu

A 91-year-old white woman with a history of glaucoma presented at Wills Eye Hospital with blurred vision in the right eye and visual acuity of 20/25. On fundus examination of the right eye (A), there was a deep, yellow mass with overlying retinal pigment epithelial loss, measuring 2 mm in basal diameter and 2 mm in thickness, and located 1 mm superior to the foveola. Optical coherence tomography localized the mass within the sclera as a focal scleral nodule, with draping and slight thinning of the overlying choroid (B, arrows). Ultrasonography showed a hyperechoic, dense mass arising from the sclera and confirmed the thickness to be 2 mm (C). Observation was advised, and 6-month follow-up showed the findings to be stable. These lesions may appear similar to malignant ocular tumors; however, they arise from the sclera and remain unchanged.

Support provided in part by the Eye Tumor Research Foundation, Philadelphia, PA (CLS). The funders had no role in the design and conduct of the study, in the collection, analysis and interpretation of the data, and in the preparation, review or approval of the manuscript.

Copyright ©2022. All rights reserved. Reproduction in whole or in part in any form or medium without expressed written permission of the Digital Journal of Ophthalmology is prohibited.