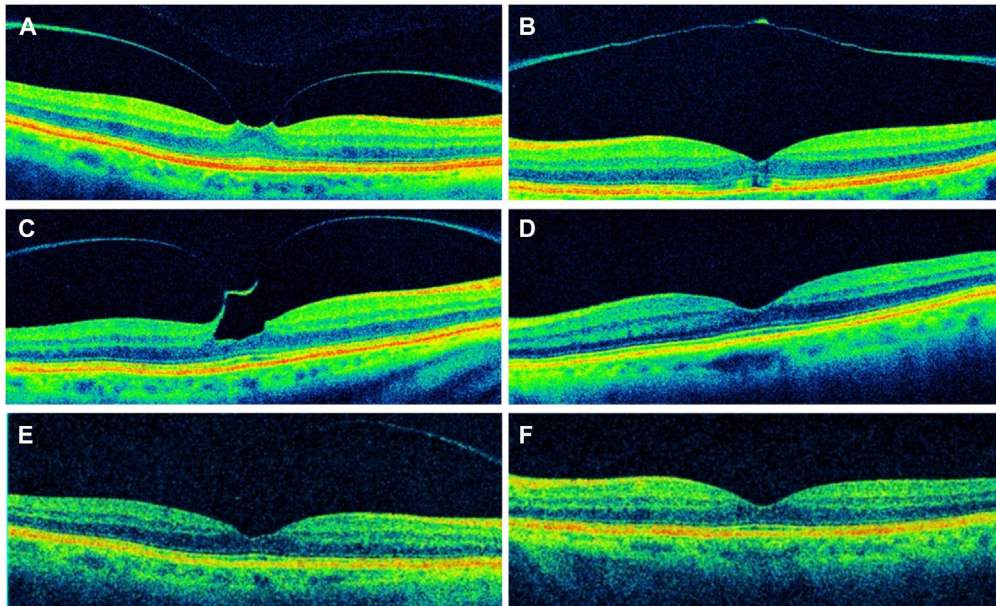


28. Eye trauma: initial care (CPG ID:03). https://jts.amedd.army.mil/assets/docs/cpgs/Eye_Trauma_Initial_Care_01_Jun_2021_ID03.pdf; 2021. Accessed June 1, 2022.
29. Dhillon A, Ahmad MSZ, Breeze J, Blanch RJ. Prolonged deployed hospital care in the management of military eye injuries. *Eye (Lond)*. 2020;34:2106–2111.
30. Peleja MB, da Cunha FBS, Peleja MB, Rohr JTD. Epidemiology and prognosis factors in open globe injuries in the Federal District of Brazil. *BMC Ophthalmol*. 2022;22:111. <https://doi.org/10.1186/s12886-021-02183-z>.
31. Blanch RJ, Bishop J, Javidi H, Murray PI. Effect of time to primary repair on final visual outcome after open globe injury. *Br J Ophthalmol*. 2019;103:1491–1494.

Pictures & Perspectives



Bilateral Spontaneous Release of Vitreomacular Traction

A 78-year-old woman presented with blurry vision. Spectral-domain OCT (Cirrus 5000) showed vitreomacular traction (VMT) in the right eye (OD) (A) with visual acuity (VA) of 20/20 and released VMT with partial thickness macular hole in the left eye (OS) (B, VA of 20/40). Observation was elected. Thirty-one months later, OCT showed progressive VMT in the OD (C, VA of 20/20), and reconstitution of the retinal layers in the OS (D, VA of 20/30). Last follow up 12 months later showed VMT release in the OD (E, VA of 20/25), and stable findings in the OS (F, VA of 20/30). (Magnified version of Figure A-F is available online at www.ophtalmologyretina.org).

PATRICK C. STAROPOLI, MD

HARRY W. FLYNN, JR., MD

Department of Ophthalmology, Bascom Palmer Eye Institute, University of Miami, Miami, Florida
