

HYPERACUTE PSEUDOPHAKIC MACULAR EDEMA VANISHING WITHIN 72 HOURS: A CASE SERIES

Tommaso Mori, MD, Francesco Cutrupi, MD, Pier Luigi Surico, MD, Roberto Sgrulletta, MD, Antonio Di Zazzo, MD, Marco Coassin, MD, PhD

Purpose: To report three cases of massive pseudophakic macular edema occurring the day after uneventful cataract surgery and resolving in 24 to 72 hours.

Methods: Observational case series.

Results: A 68-year-old woman affected by systemic lupus erythematosus and antiphospholipid syndrome displayed massive macular edema on optical coherence tomography scan one day after uneventful cataract surgery. Routine postoperative topical eye drops (chloramphenicol/betamethasone 4 times a day and bromfenac 2 times a day) were continued without additional medications. Three days later, optical coherence tomography showed a completely recovered, normal fovea. Two similar cases were documented. A 73-year-old man and a 53-year-old man underwent cataract surgery and started the mentioned topical postoperative therapy. Severe macular edema was diagnosed the day after surgery and resolved in 24 and 48 hours, respectively.

Conclusion: Massive macular edema may occur immediately after uncomplicated cataract and then disappear within 1 to 3 days, without invasive therapies. This is a very significant event that may follow cataract surgery, and that was previously unreported.

RETINAL CASES & BRIEF REPORTS 18:94–97, 2024

From the Ophthalmology, University Campus Bio-Medico of Rome, Rome, Italy.

Pseudophakic cystoid macular edema (PCME), also known as Irvine–Gass syndrome, is recognized as one of the most common causes of poor visual outcome after cataract surgery.¹ Pseudophakic cystoid macular edema is defined as a retinal thickening of the macula because of the alteration of the normal blood–retinal barrier, with perifoveal retinal capillary leakage and storage of fluid primarily in the outer plexiform layer.² Nowadays, optical coherence tomography (OCT) is considered the most sensitive method to detect and monitor CME, playing a key role in its diagnosis and follow-up.³ Clinically significant PCME imparting patient’s vision is found in 1% to 2% of patients, with its peak 6 weeks after surgery.⁴

Resolution of the macular edema occurs within 3 months to 4 months.⁵ Steroidal and nonsteroidal anti-inflammatory drugs have been proposed for the prevention or the treatment of PCME.⁶ Several factors and mechanisms may be involved in the pathogenesis of PCME, including the release of mediators of inflammation after cataract surgery, such as prostaglandins, arachidonic acid, cytokines, and vascular endothelial growth factor, with the disruption of the blood–retinal barrier, leading to increased vascular permeability resulting in macular edema.^{7–9}

We herein report three cases of severe PCME occurring one day after uneventful cataract surgery; all patients were routinely under treatment with topical antibiotic, steroidal and nonsteroidal anti-inflammatory drug eye drops; PCME resolved within 72 hours without additional treatment in all three cases.

Case 1

A 63-year-old woman underwent cataract surgery in the right eye. Medical history was remarkable for systemic lupus erythematosus and antiphospholipid syndrome with a noncontributory ocular history.

None of the authors has any financial/conflicting interests to disclose.

Reprint requests: Marco Coassin, MD, PhD, University Campus Bio-Medico, Via A. del Portillo, 200, Rome, Italy 00128; e-mail: m.coassin@policlinicocampus.it

Preoperatively, best-corrected visual acuity (BCVA) was 20/80 Snellen and no other conditions were present in the right eye. The uneventful surgery consisted in routine phacoemulsification throughout a 2.4-mm clear-corneal incision and implantation of a single-piece acrylic intraocular lens (IOL). The patient was discharged from the outpatient clinic and started on topical therapy the same afternoon after cataract surgery (chloramphenicol/betamethasone 4 times a day and bromfenac 2 times a day, eye drops).

The day after surgery, the patient returned to the clinic complaining of marked decrease in visual acuity in the operated eye. The BCVA in right eye was reduced to 20/400 Snellen. Slit-lamp examination showed mild corneal edema and IOL correctly positioned in the capsular bag. The IOP was within normal limits and indirect ophthalmoscopy was unremarkable. Optical coherence tomography scan showed severe pseudophakic macular edema (Figure 1A). Patient was instructed to continue chloramphenicol/betamethasone (4 times a day) and bromfenac (2 times a day) eye drops. Next day, the patient experienced subjective improvement of visual acuity. Two days after diagnosis of PCME, vision improved to 20/25 Snellen and a new OCT scan demonstrated a complete resolution of the macular edema (Fig. 1B). At last follow-up visit 3 weeks later, visual acuity was 20/20 Snellen and OCT confirmed the permanent resolution of PCME in the right eye.

This case was not isolated. Within two years, a similar pattern was observed in two other patients in our institution.

Case 2

A 73-year-old male patient underwent cataract surgery in the left eye. Medical history was unremarkable except for a benign prostate adenomyoma. Preoperatively, BCVA of the right eye was 20/63 Snellen and there was no sign of ocular inflammation at slit-lamp examination. Fundus examination showed no retinal diseases. The patient underwent regular cataract surgery. After 24 hours, the patient complained of significant visual impairment in the operated eye. BCVA decreased to 20/125 Snellen. Anterior segment examination was normal with the IOL correctly positioned within the capsular bag. The OCT scan showed severe PCME with subretinal and intraretinal fluid (Fig. 1C). Routine postoperative topical eye drops (chloramphenicol/betamethasone 4 times a day and bromfenac 2 times a day) were continued. The following day, BCVA improved to 20/25 Snellen and OCT macular scan showed a total disappearance of macular edema (Fig. 1D).

Case 3

The last case was reported in a 53-year-old healthy man who was scheduled for cataract surgery in the right eye on March 2021. Preoperative BCVA was 20/50 Snellen and IOP was within normal limits. Routine cataract surgery was performed without complications. The patient was discharged with the usual

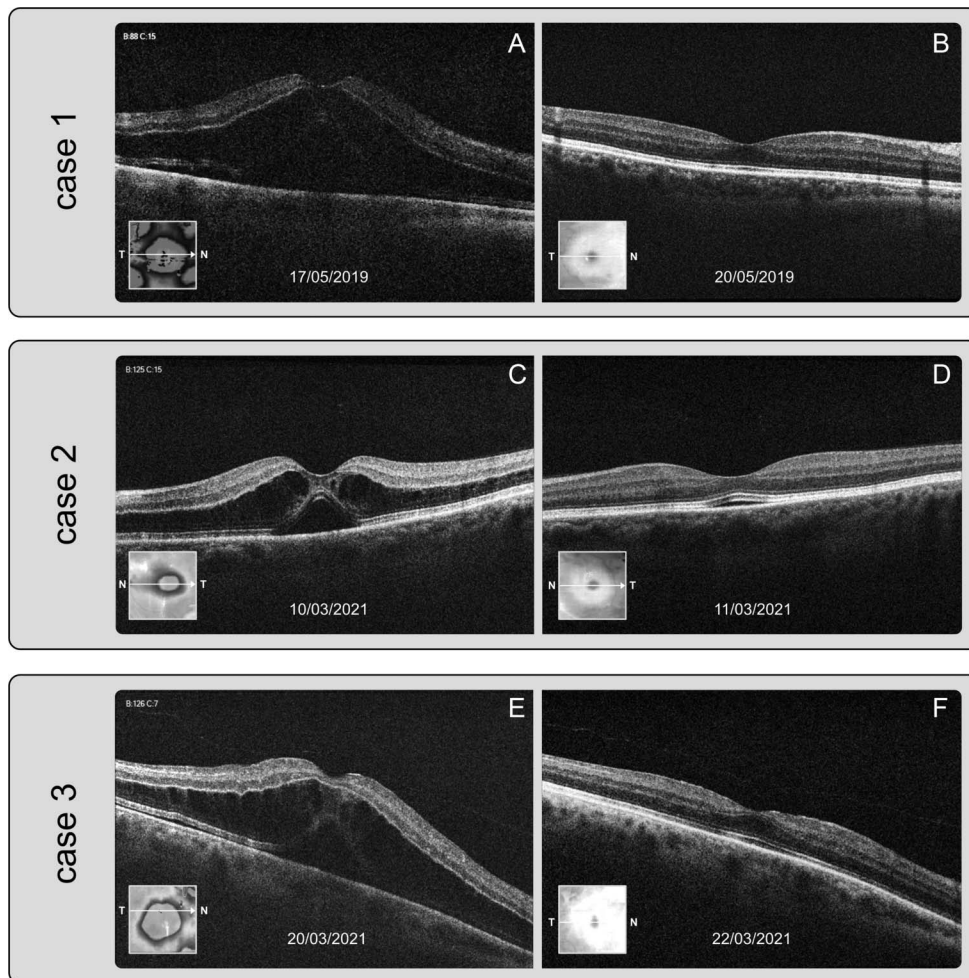


Fig. 1. Three cases of severe PCME occurring one day after uneventful cataract surgery and completely resolving within 72 hours. Optical coherence tomography scan of a 68-year-old woman, one day after routine cataract surgery showing massive PCME (A), and 72 hours later showing a completely recovered, normal fovea (B). Optical coherence tomography scan of a 73-year-old male patient, one day after uneventful cataract surgery showing subretinal and intraretinal fluid (C), and 24 hours later demonstrating a total disappearance of macular edema (D). Optical coherence tomography scan of the right retina of a 53-year-old man, one day after routine cataract surgery demonstrating macular edema (E), and 48 hours later displaying a complete resolution of the PCME (F).

postoperative eye drops (chloramphenicol/betamethasone 4 times a day and bromfenac 2 times a day). After 24 hours, the patient returned to our center complaining of blurred vision in the right eye. BCVA was 20/200 Snellen. Slit-lamp examination showed clear central cornea and IOL was well positioned in the capsular bag. OCT scan of the right retina demonstrated moderate macular edema (Fig. 1E). After 2 days, the patient reported subjective improvement of visual acuity. BCVA improved to 20/25 Snellen and OCT scan displayed a complete resolution of the intraretinal and subretinal fluid (Fig. 1F).

Discussion

The underlying causes of the formation of CME after cataract surgery are not fully understood. Various hypotheses have been proposed. Mechanical trauma from the surgery may promote the expression of cyclooxygenase, which triggers the synthesis of prostaglandins and other inflammatory mediators.¹⁰ These factors impair the blood–retinal barrier postoperatively, leading to increased permeability of perifoveal capillaries and fluid accumulation in the perifoveal retina.^{7–9}

Although the precise mechanisms characterizing the passage of fluid from the bloodstream to the outer plexiform layer are not known, it is believed that the time required for this mechanism to occur is in the order of weeks and months.^{4,5} In our series, the presence of PCME was documented by OCT the day after cataract surgery and macular edema disappeared within 72 hours in all three cases.

We are not able to explain the cause of the sudden genesis and resolution of PCMEs in our patients. In the case of the 63-year-old woman, lupus erythematosus and antiphospholipid syndrome might have had a role in promoting macular edema formation. The defective circulatory homeostasis could have played a role in the early breakdown of the blood–retinal barrier. However, the two other patients presented an unremarkable medical history. In particular, none of them was affected by diabetes.

Posterior hyaloid was completely detached from the retina only in the first case, but it was not in the other two eyes, as shown in Figure 1. All three patients presented moderate cataracts with 2+ nuclear sclerosis and no other ocular comorbidities. Intraocular inflammation and anterior chamber flare/cells were not remarkably increased the day after surgery in the three eyes.

In all three cases, phacoemulsification was performed throughout a 2.4-mm clear corneal incision (Constellation Vision System, Alcon) without complications, and a one-piece acrylic IOL was placed inside the capsular bag (AcrySof SA60AT, Alcon). Acetylcholine (10 mg/mL; Miochol-E, Bausch & Lomb, Rochester, NY) and cefuroxime (1 mg/0.1 mL; Apropam, Théa Pharma,

Clermont-Ferrand, France) were separately injected in the anterior chamber at the end of surgery.

It has been hypothesized that intraocular cefuroxime might induce postoperative macula edema. Of 13 patients receiving by mistake cefuroxime at high concentration (9 mg/0.1 mL), 6 patients developed postoperative macular edema.¹¹ Another recent article reported on CME after routine cataract surgery terminated with 3 mg to 7 mg of cefuroxime.¹² It is possible that cefuroxime toxicity could be the lead factor in our case series also, because of high concentration or excessive susceptibility to the medication. However, the commercial formulation of cefuroxime for intraocular use makes unlikely improper dilution (the content is in powder form in a 10-mL vial and should be reconstituted simply by addition of 5 mL of saline).

Preoperative topical therapy is not routinely prescribed in our hospital nor it was in these patients. Postoperative eye drops (chloramphenicol/betamethasone 4 times a day and bromfenac 2 times a day) were ordinarily started by all three patients in the afternoon immediately after cataract surgery and drops were continued after the discovery of macular edema. Eye drops seem not to have played a role in preventing the PCME—and therefore in treating it, especially because of the short course of treatment.

We can only speculate how a severe form of pseudophakic macular edema may occur hyperacutely after uncomplicated cataract surgery and then vanish within 1 to 3 days without need of invasive therapies. We believe this is a very significant event that may follow cataract surgery, that was previously unreported, and that may be severely underestimated.

Key words: case series, hyperacute onset, pseudophakic cystoid macular edema, uneventful cataract surgery.

References

1. Flach AJ. The incidence, pathogenesis and treatment of cystoid macular edema following cataract surgery. *Trans Am Ophthalmol Soc* 1998;96:557–634.
2. Neal RE, Bettelheim FA, Lin C, et al. Alterations in human vitreous humour following cataract extraction. *Exp Eye Res* 2005;80:337–347.
3. Wielders LHP, Schouten JSAG, Nuijts RMMA. Prevention of macular edema after cataract surgery. *Curr Opin Ophthalmol* 2018;29:48–53.
4. Henderson BA, Kim JY, Ament CS, et al. Clinical pseudophakic cystoid macular edema. Risk factors for development and duration after treatment. *J Cataract Refract Surg* 2007;33:1550–1558.
5. Bradford JD, Wilkinson CP, Bradford RH. Cystoid macular edema following extracapsular cataract extraction and posterior chamber intraocular lens implantation. *Retina* 1988;8:161–164.

6. Wielders LHP, Schouten JSAG, Winkens B, et al. European multicenter trial of the prevention of cystoid macular edema after cataract surgery in nondiabetics: ESCRS PREMEDI study report 1. *J Cataract Refract Surg* 2018;44:429–439.
7. Augustin A, Loewenstein A, Kuppermann BD. Macular edema. General pathophysiology. *Dev Ophthalmol* 2010;47:10–26.
8. Miyake K. Prevention of cystoid macular edema after lens extraction by topical indomethacin (I). A preliminary report. *Albrecht von Graefes Archiv für klinische und experimentelle Ophthalmologie* Albrecht von Graefe's archive for clinical and experimental ophthalmology 1977;203:81–88.
9. Miyake K, Ibaraki N. Prostaglandins and cystoid macular edema. *Surv Ophthalmol*. 2002;47:S203–18.
10. Endo N, Kato S, Haruyama K, et al. Efficacy of bromfenac sodium ophthalmic solution in preventing cystoid macular oedema after cataract surgery in patients with diabetes. *Acta Ophthalmol* 2010;88:896–900.
11. Wong DC, Waxman MD, Herrinton LJ, Shorstein NH. Transient macular edema after intracameral injection of a moderately elevated dose of cefuroxime during phacoemulsification surgery. *JAMA Ophthalmol* 2015;133:1194–1197.
12. Spackman W, Raman V. Acute exudative serous macular detachment with intraretinal oedema following uncomplicated phacoemulsification cataract surgery. *BMJ Case Rep* 2022;15:e247772.