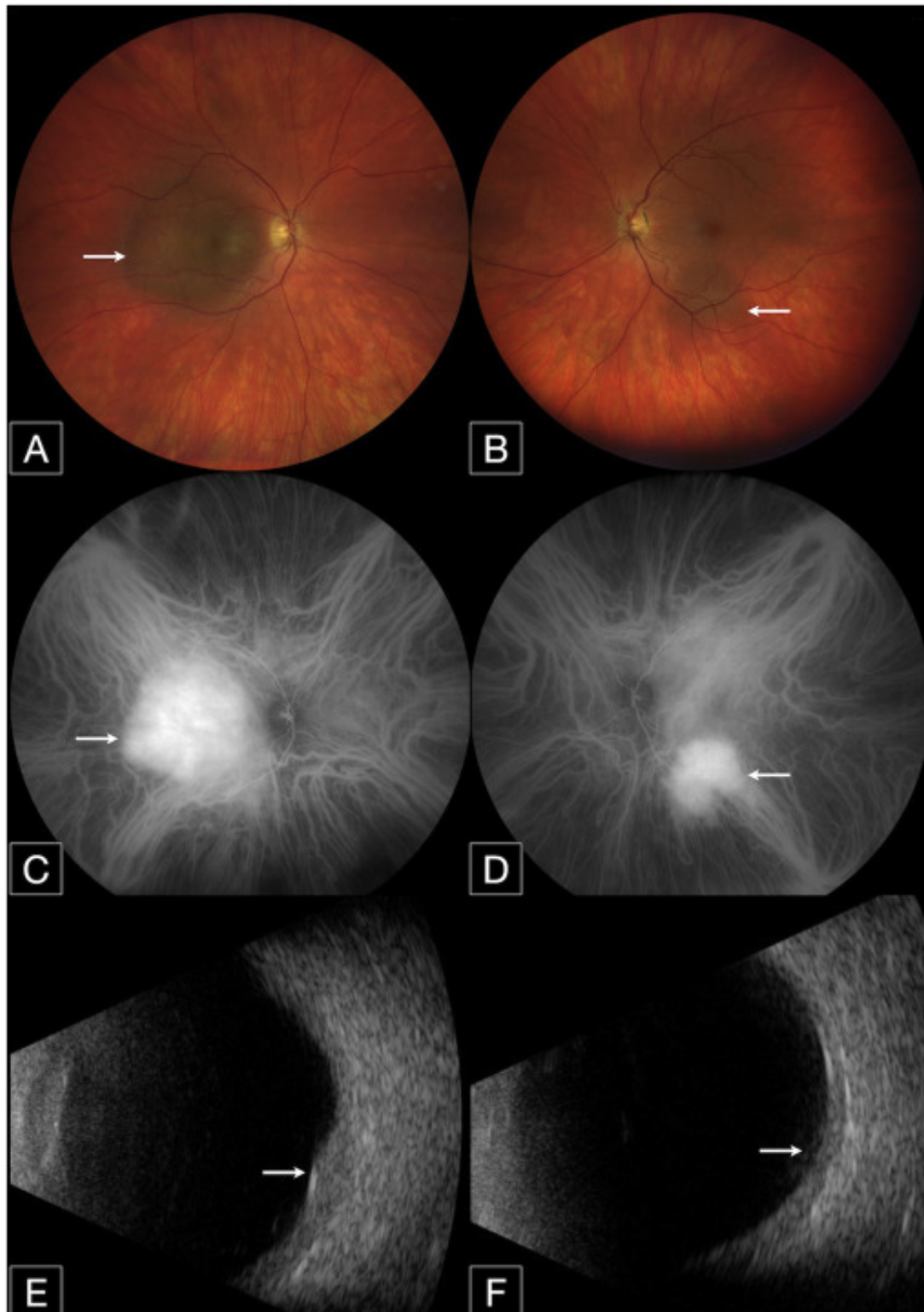
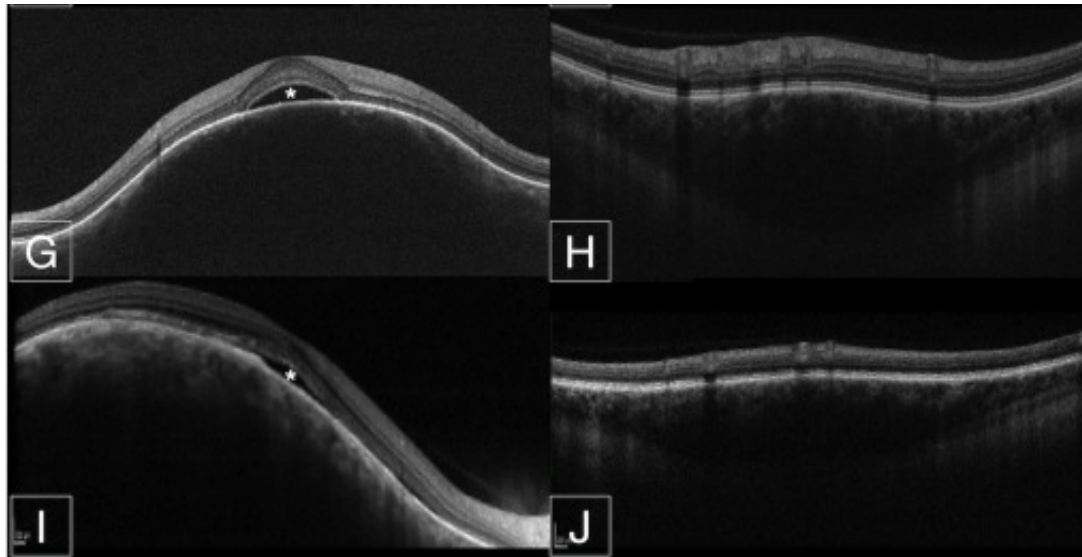


Bilateral circumscribed choroidal hemangiomas in 2 patients: a rare finding





Circumscribed choroidal hemangioma (CCH) is a benign vascular choroidal tumour that classically presents as a sporadic unilateral orange-coloured lesion that can be difficult to visualize on fundoscopy because the colour of the tumour often blends with the surrounding normal choroid. This tumour can be asymptomatic or present with symptoms of floaters, photopsia, or vision loss. Bilateral presentation is extremely rare, with only 2 cases reported in the literature. Herein we describe 2 additional cases of bilateral CCH and their management.

To read this article in full you will need to make a payment

References

1.

Shields CL
Honavar SG
Shields JA
Cater J
Demirci H.

Circumscribed choroidal hemangioma clinical