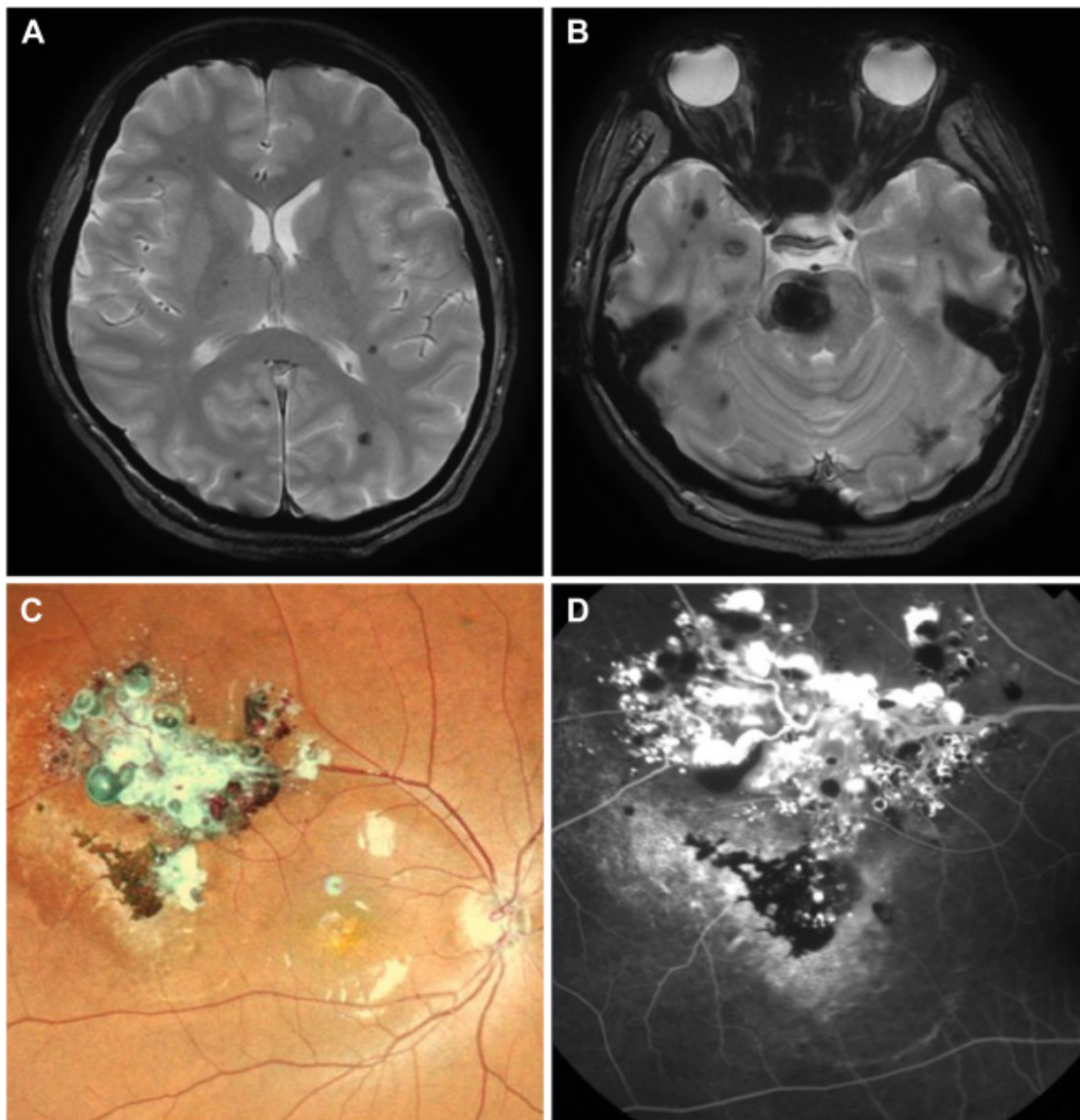


# Cavernous Hemangioma of the Retina and Brain



A 29-year-old woman presented with sudden onset of headache and paralysis of the left side. Magnetic resonance imaging showed multiple cerebral cavernous malformations and hemorrhage at the brainstem (**A**, **B**). Right fundus examination revealed grape-like hemorrhagic clusters (**C**), which had been

observed in this patient since age 9. Fundus fluorescein angiography showed plasma–erythrocytic separation in some aneurysms (**D**). Cavernous malformations are congenital vascular anomalies found in the central nervous system or in the retina. Approximately 14% of patients with retinal cavernous hemangiomas have cerebral cavernous malformations. Once retinal cavernous hemangiomas are diagnosed, cerebral vascular abnormalities should be excluded by imaging. (Magnified version of Figure **A-D** is available online at [www.aaojournal.org](http://www.aaojournal.org)).