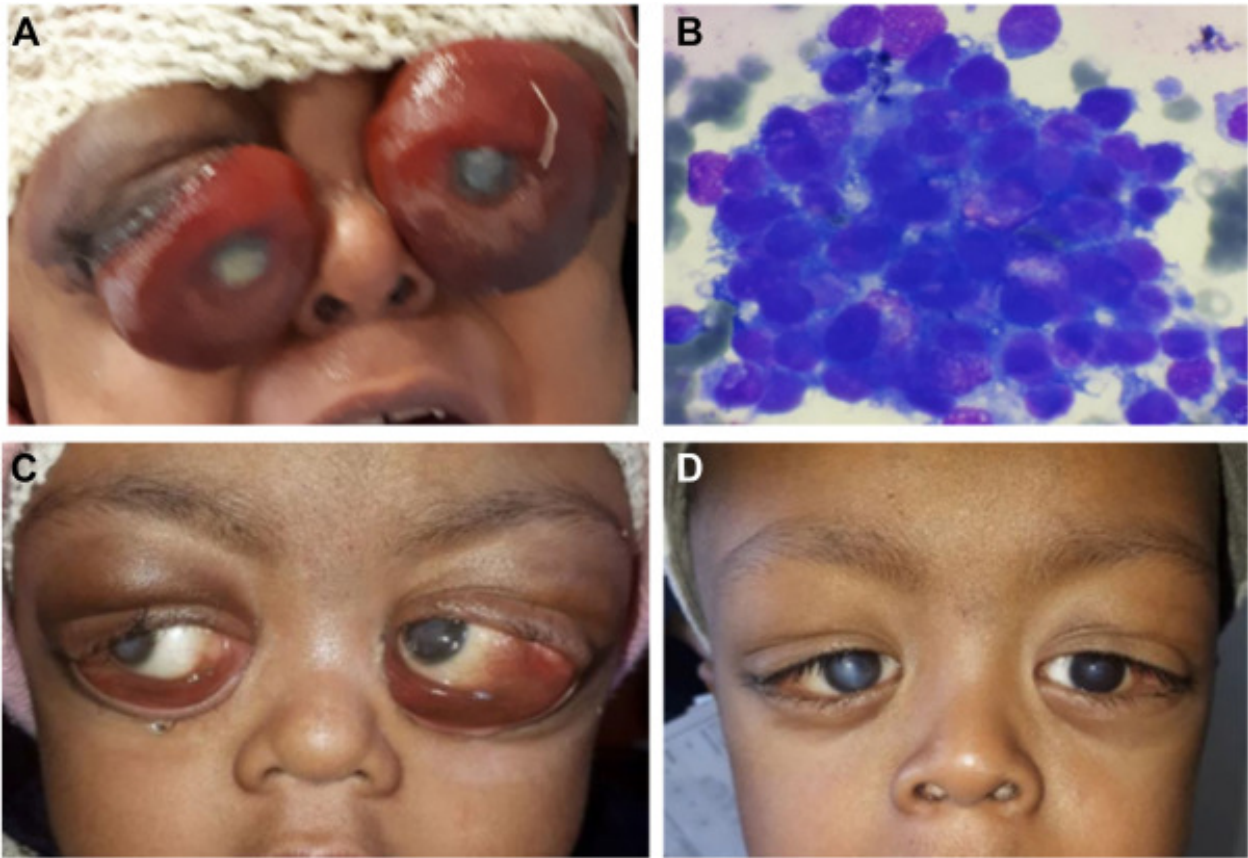


# Neglected Metastatic Neuroblastoma



A 5-year-old child was referred to our clinic with a history of neglected and untreated metastatic neuroblastoma. **A**, The child exhibited severe proptosis, severe chemosis, exposure keratopathy, corneal ulcers, limited extraocular movements, and decreased visual acuity in both eyes. **B**, Cerebrospinal fluid analysis showed a cluster of neuroblastoma cells. The child underwent transconjunctival orbital decompression surgery to alleviate proptosis and relieve pressure on the optic nerve. Additionally, intrathecal chemotherapy was administered to target central nervous system involvement. **C**, The child's response to treatment was remarkable, as the proptosis subsided, and extraocular movements returned to normal. Although corneal scarring remains (**D**), there has been an improvement in visual acuity. (Magnified version of Figure **A-D** is available online at

[www.aajournal.org](http://www.aajournal.org)).