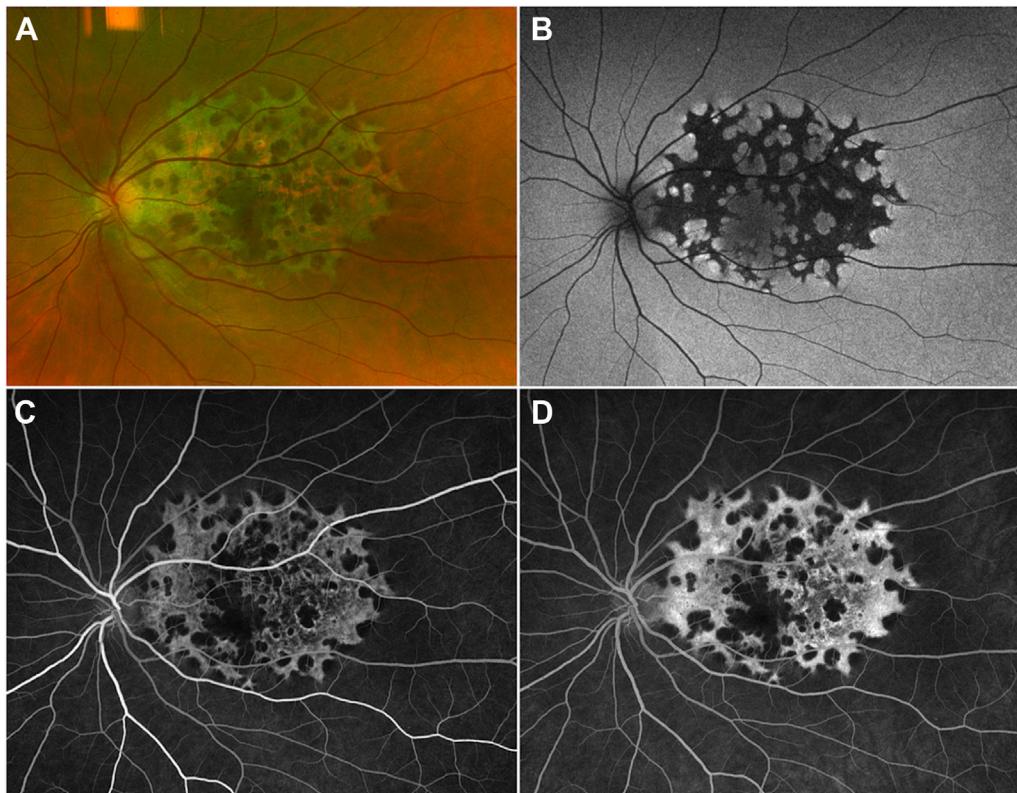


16. Paredes Mogica JA, De EJB. Pentosan polysulfate maculopathy: what urologists should know in 2020. *Urology*. 2021;147:109–118.
17. Hadad A, Helmy O, Leeman S, Schaal S. A novel multi-method image analysis to quantify pentosan polysulfate sodium retinal toxicity. *Ophthalmology*. 2020;127:429–431.
18. Marmor MF, Kellner U, Lai TY, et al. Recommendations on screening for chloroquine and hydroxychloroquine retinopathy (2016 Revision). *Ophthalmology*. 2016;123:1386–1394.
19. Yusuf IH, Foot B, Lotery AJ. The Royal College of Ophthalmologists recommendations on monitoring for hydroxychloroquine and chloroquine users in the United Kingdom (2020 revision): executive summary. *Eye (Lond)*. 2021;35:1532–1537.

Pictures & Perspectives



Unilateral Retinal Pigment Epithelium Dysgenesis

A 40-year-old otherwise healthy woman was referred for unilateral macular changes. She was asymptomatic and the visual acuity was 20/20 bilaterally. The left macula demonstrated extensive atrophy sparing the fovea, with a scalloped appearance and well demarcated edges (A). Fundus autofluorescence demonstrated distinct hypoautofluorescence with hyperautofluorescent margins (B). OCT showed areas of outer retinal and retinal pigment epithelial atrophy with otherwise normal retinal architecture and laminations. Fluorescein angiography demonstrated a window defect with no neovascularization or other vascular abnormalities (C, D). The right eye was within normal limits clinically and on multimodal imaging (Magnified version of Figure A-D is available online at www.ophtalmologyretina.org).

TED HAN, MD

MARK SEAMONE, MD, FRCSC

PARAMPAL S. GREWAL, MD, FRCSC

Department of Ophthalmology and Visual Sciences, University of Alberta, Edmonton, Canada