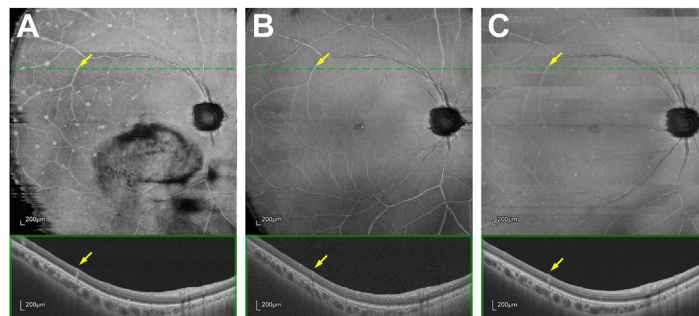


14. Dolz-Marco R, Phasukkijwatana N, Sarraf D, Freund KB. Regression of type 2 neovascularization into a type 1 pattern after intravitreal anti-vascular endothelial growth factor therapy for neovascular age-related macular degeneration. *Retina*. 2017;37:222–233.
15. Bailey C, Scott LJ, Rogers CA, et al. Intralesional macular atrophy in anti-vascular endothelial growth factor therapy for age-related macular degeneration in the IVAN trial. *Ophthalmology*. 2019;126:75–86.
16. Güne S, Abdelfattah NS, Karamat A, et al. Spectral-domain OCT-based prevalence and progression of macular atrophy in the HARBOR study for neovascular age-related macular degeneration. *Ophthalmology*. 2020;127:523–532.
17. Kumar JB, Stinnett S, Han JIL, Jaffe GJ. Correlation of sub-retinal hyperreflective material morphology and visual acuity in neovascular age-related macular degeneration. *Retina*. 2020;40:845–856.
18. Finn AP, Pistilli M, Tai V, et al. Localized optical coherence tomography precursors of macular atrophy and fibrotic scar in the Comparison of Age-related Macular Degeneration Treatments Trials. *Am J Ophthalmol*. 2021;223:338–347.
19. Chen L, Li M, Messinger JD, et al. Recognizing atrophy and mixed-type neovascularization in age-related macular degeneration via clinicopathologic correlation. *Transl Vis Sci Technol*. 2020;9:8. <https://doi.org/10.1167/tvst.9.8.8>.
20. Gibran SK, Sachdev A, Stappler T, et al. Histological findings of a choroidal neovascular membrane removed at the time of macular translocation in a patient previously treated with intravitreal bevacizumab treatment (Avastin). *Br J Ophthalmol*. 2007;91:602–604.
21. Schütze C, Wedl M, Baumann B, et al. Progression of retinal pigment epithelial atrophy in antiangiogenic therapy of neovascular age-related macular degeneration. *Am J Ophthalmol*. 2015;159:1100–1114.e1.
22. Heimes B, Farecki Jr M-L, Bartels S, et al. Retinal pigment epithelial tear and anti-vascular endothelial growth factor therapy in exudative age-related macular degeneration: clinical course and long-term prognosis. *Retina*. 2016;36:868–874.
23. Bachmeier I, Garcia Armendariz B, Yu S, et al. Fibrosis in neovascular age-related macular degeneration: a review of definitions based on clinical imaging. *Surv Ophthalmol*. 2023. <https://doi.org/10.1016/j.survophthal.2023.03.004>.
24. Jaffe GJ, Ying G-S, Toth CA, et al. Macular morphology and visual acuity in year five of the Comparison of Age-related Macular Degeneration Treatments Trials. *Ophthalmology*. 2019;126:252–260.

Pictures & Perspectives



Recurrence of Intraretinal Infiltration of Vitreoretinal Lymphoma

OCT angiography of a 53-year-old man with vitreoretinal lymphoma showed hyperreflective punctate lymphoma infiltration lesions distributed around retinal vessels on the en face image, which resemble flower buds on branches and are called perivascular flower-bud-like lesions for short. In cross-sectional OCT, perivascular flower-bud-like lesions appeared as full-thickness intraretinal lesions (A). After intravitreal methotrexate chemotherapy, partial remission was achieved (B). Due to progression to central nervous system disease, methotrexate-based systemic chemotherapy was initiated and ocular treatment was suspended. After 4 cycles of systemic chemotherapy, an early recurrence of perivascular flower-bud-like lesions was observed at a subsequent ophthalmic visit (C). (Magnified version of Figure A-C is available online at www.opthalmologyretina.org).

JUNXIANG GU, MD^{1,2,3}
 KAIYU ZHANG, BS⁴
 QING CHANG, MD, PHD^{1,2,3}

¹Department of Ophthalmology, Fudan University Eye and ENT Hospital, Fudan University, Shanghai, China; ²Shanghai Key Laboratory of Visual Impairment and Restoration, Fudan University Eye and ENT Hospital, Fudan University, Shanghai, China; ³NHC Key Laboratory of Myopia (Fudan University); Key Laboratory of Myopia, Chinese Academy of Medical Sciences, Shanghai, China; ⁴Shanghai Medical College, Fudan University, Shanghai, China