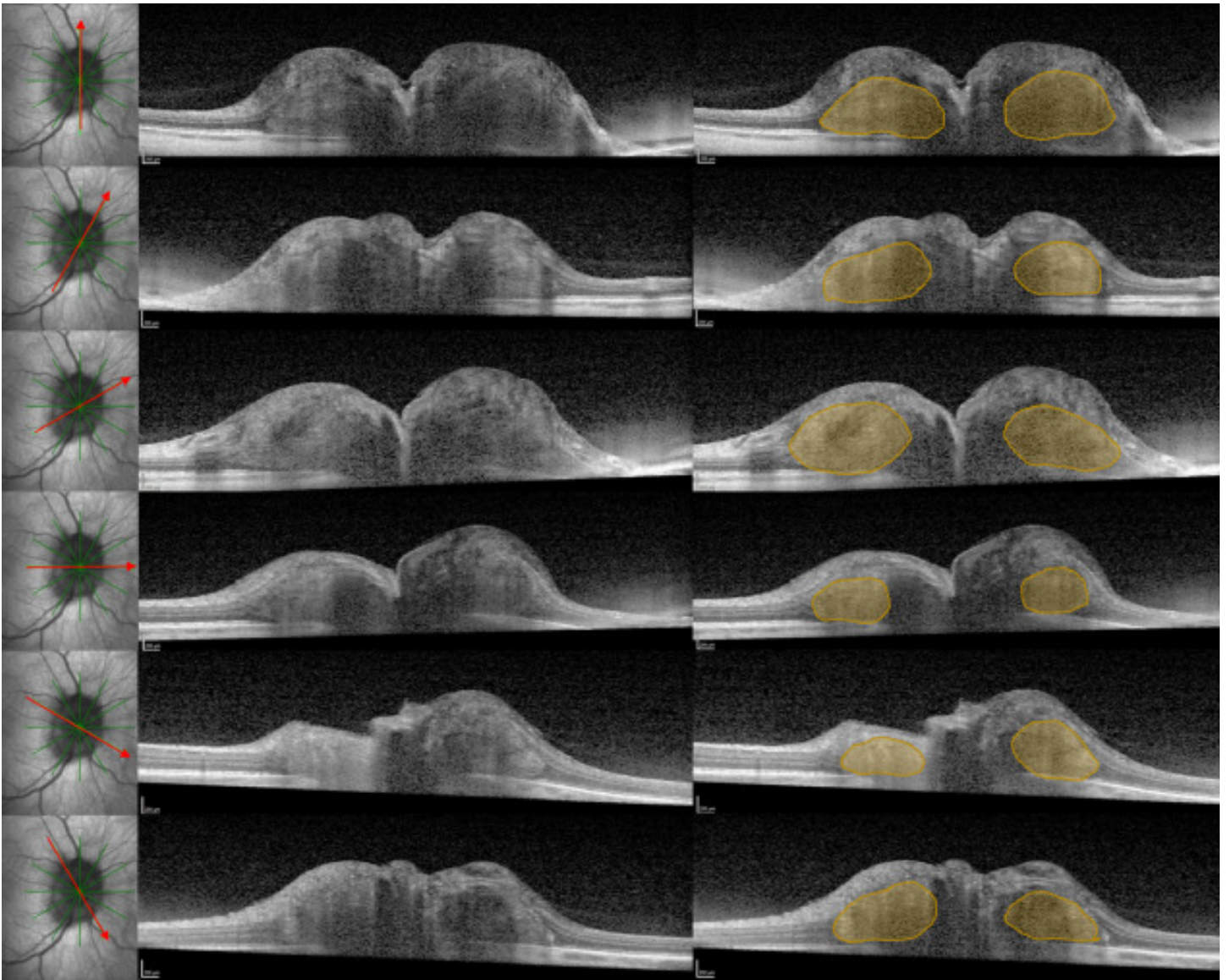


A 360-degree peripapillary hyper-reflective ovoid mass-like structure (PHOMS)

Search for articles by this author

Property	Value
Status	
Version	
Ad File	
Disable Ads Flag	
Environment	
Moat Init	
Moat Ready	
Contextual Ready	
Contextual URL	
Contextual Initial Segments	
Contextual Used Segments	
AdUnit	
SubAdUnit	
Custom Targeting	
Ad Events	
Invalid Ad Sizes	



- [J. Alexander Fraser, MD, FRCPC](#)

J. Alexander Fraser

Correspondence

Correspondence to: J. Alexander Fraser, MD, London Health Sciences Centre, University Hospital, Room B7-104, 339 Windermere Rd., London, Ont. N6A 5A5.

Affiliations

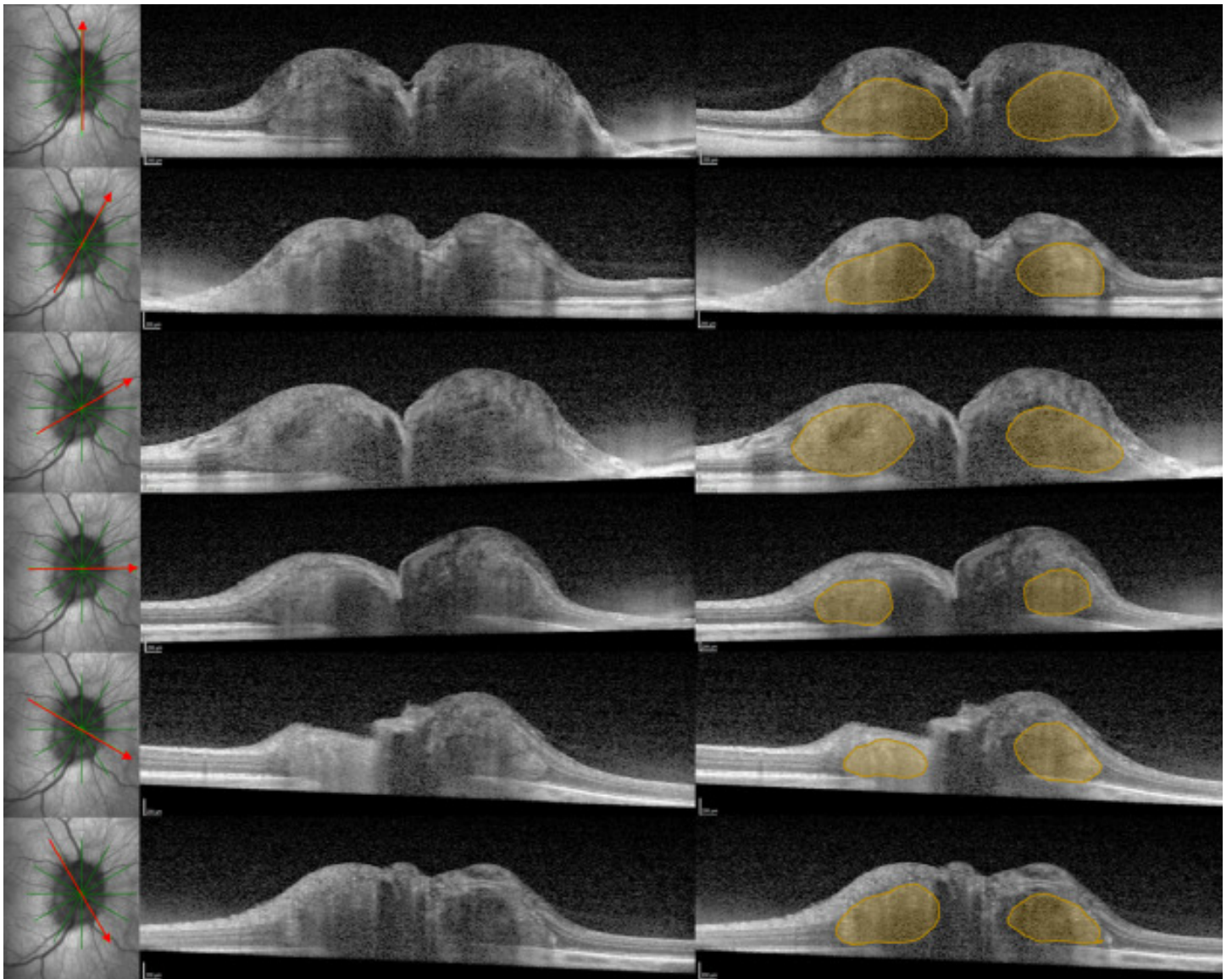
Department of Clinical Neurological Sciences, Western University, London, Ont.

Department of Ophthalmology, Western University, London, Ont.

- [Article info](#)

- [Related Articles](#)

A 31-year-old woman developed papilledema from idiopathic intracranial hypertension. Enhanced-depth imaging optical coherence tomography (EDI-OCT) excluded optic disc drusen (ODD) but was notable for a peripapillary hyper-reflective ovoid mass-like structure (PHOMS), contiguous 360 degrees around the optic disc, forming a 3-dimensional torus (i.e., donut) (Fig.) Radial sections through the right optic nerve head are shown in the left column; a PHOMS is seen at each of the twelve clock-hours of the peripapillary region in the middle column and duplicated and shaded yellow in the right column.



To read this article in full you will need to make a payment

Article info

Publication history

Published online: September 28, 2020

Accepted: September 1, 2020

Received in revised form: August 1, 2020

Received: July 7, 2020

Identification

DOI: <https://doi.org/10.1016/j.jcjo.2020.09.008>

Copyright

© 2020 Canadian Ophthalmological Society. Published by Elsevier Inc. All rights reserved.

ScienceDirect

[Access this article on ScienceDirect](#)

Related Articles