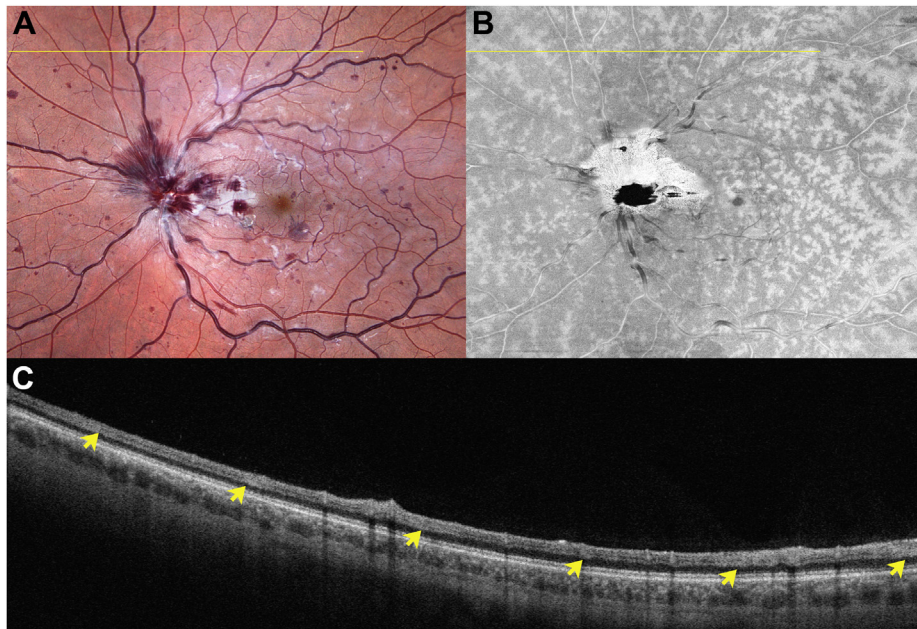


12. Leiba H, Oliver M, Pollack A. Prophylactic laser photocoagulation in Stickler syndrome. *Eye (Lond)*. 1996;10:701–708.
13. Carroll C, Papaioannou D, Rees A, Kaltenthaler E. The clinical effectiveness and safety of prophylactic retinal interventions to reduce the risk of retinal detachment and subsequent vision loss in adults and children with Stickler syndrome: a systematic review. iii–xiv *Health Technol Assess*. 2011;15:1–62.
14. Fincham GS, Paisea L, Carroll C, et al. Prevention of retinal detachment in Stickler syndrome: the Cambridge prophylactic cryotherapy protocol. *Ophthalmology*. 2014;121:1588–1597.
15. Coussa RG, Sears J, Traboulsi EI. Stickler syndrome: exploring prophylaxis for retinal detachment. *Curr Opin Ophthalmol*. 2019;30:306–313.
16. Khanna S, Rodriguez SH, Blair MA, et al. Laser prophylaxis in patients with Stickler syndrome. *Ophthalmol Retina*. 2022;6:263–267.
17. Morris RE, Parma ES, Robin NH, et al. Stickler syndrome (SS): laser prophylaxis for retinal detachment (modified Ora Secunda cerclage, OSC/SS). *Clin Ophthalmol*. 2021;15:19–29.
18. Ripandelli G, Rossi T, Pesci FR, et al. The prophylaxis of fellow-eye retinal detachment in Stickler syndrome. A retrospective series. *Retina*. 2022;42:250–255.
19. Al Taisan A, Magliyah M, Abouammoh M, et al. Posterior segment characterization in children with Pierson syndrome. *Ophthalmic Surg Lasers Imaging Retina*. 2020;51:618–627.
20. Sehgal P, Narang S, Chandra D. Rhegmatogenous retinal detachment with giant retinal tear in a child with Marfan's syndrome: a rare ocular emergency. *BMJ Case Rep*. 2021;14:e241354. <https://doi.org/10.1136/bcr-2020-241354>.
21. Dobrelova D, Karel I, Clupkova E. Retinal detachment in Marfan's syndrome. Characteristics and surgical results. *Retina*. 1997;17:390–396.

Pictures & Perspectives



Widefield Perivenular Inner Nuclear Layer Hyperreflectivity

A 31-year-old man presented with acute, painless visual loss in the left eye. (A) Ophthalmoscopy showed vascular changes compatible with central retinal vein occlusion. (B) *En face* swept-source OCT slab at the inner nuclear layer showed perivenular hyperreflectivity featuring a fern-like pattern at the macula and midperiphery. (C) A horizontal OCT scan through the midperiphery showed hyperreflective bands (arrows) at the inner nuclear layer level, an imaging signature of paracentral acute maculopathy. This observation suggests that the anatomic explanation for paracentral acute maculopathy is not necessarily from occlusion of the intermediate capillary plexus, which is absent in the midperipheral retina. (Magnified version of Figure A-C is available online at www.ophtalmologyretina.org).

MARIANA VAZ, MD¹
 DIOGO CABRAL, MD^{1,2}

¹Hospital Garcia de Orta, Almada, Portugal; ²iNOVA4Health, NOVA Medical School, Universidade NOVA de Lisboa, Lisbon, Portugal