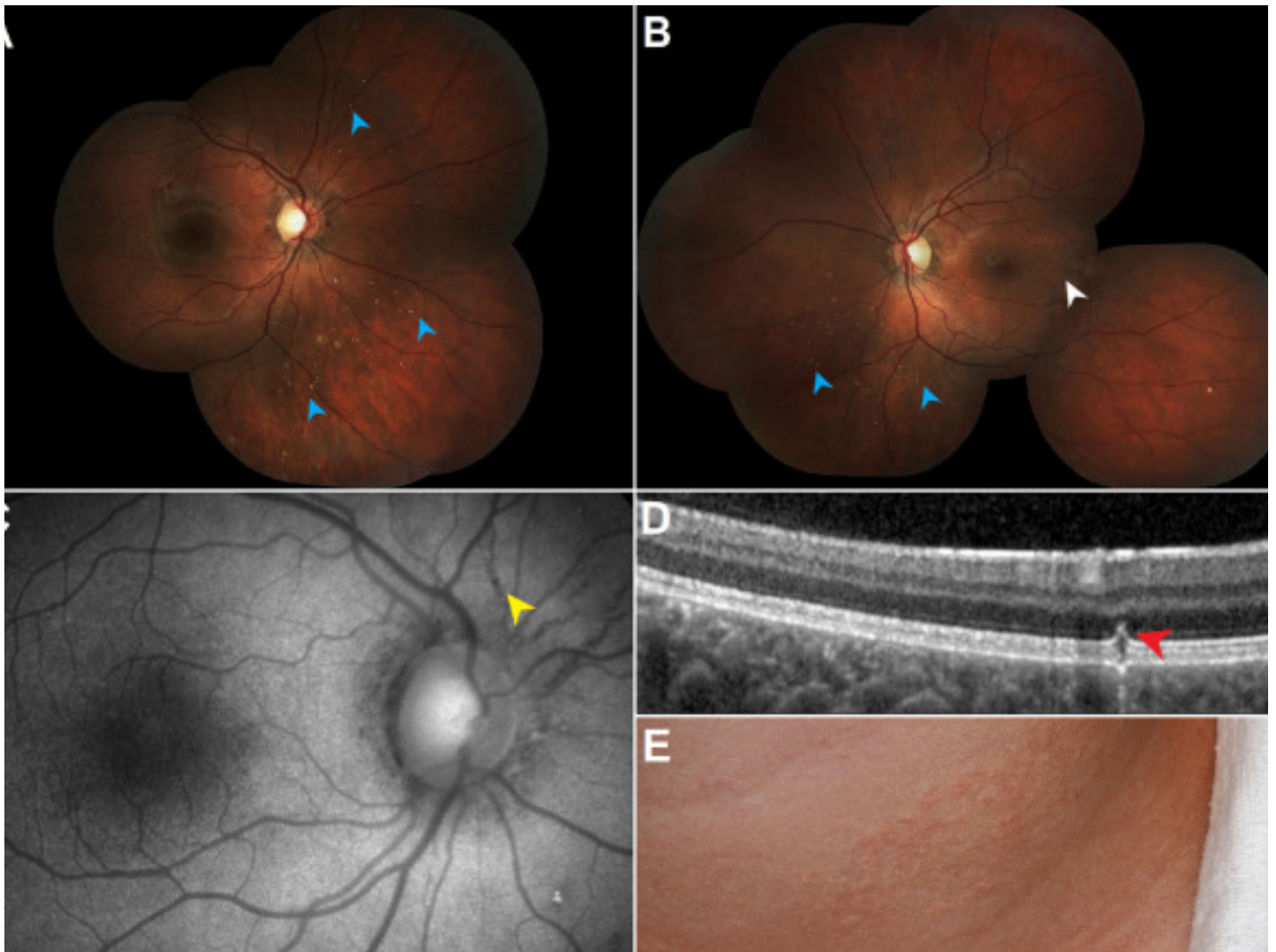


# Retinal crystalline lesions in pseudoxanthoma elasticum

Search for articles by this author



An 11-year-old healthy boy was evaluated for incidental retinal crystalline lesions. Visual acuity was 20/20 in both eyes. Fundus examination of the right (A) and left (B) eyes demonstrated multiple crystalline bodies (blue arrows) scattered throughout the midperipheral and peripheral retina, a peau d'orange pattern of retinal pigment epithelial (RPE), alterations in the temporal retina (white arrow), and angioid streaks (yellow arrow) around the optic nerve on fundus autofluorescence imaging (C). Optical coherence tomography (D) was performed through a retinal crystalline lesion, demonstrating a hyper-reflective

lesion (red arrow) in the outer retinal layers with alterations in the RPE/Bruch membrane complex. Given the constellation of ocular findings, a diagnosis of pseudoxanthoma elasticum (PXE) was suspected. A dermatologic examination was subsequently performed demonstrating yellowish papules around the neck in a cobblestone pattern (E). Genetic testing revealed homozygous pathogenic variants in the gene *ABCC6*, a mutation associated with PXE. Retinal crystalline lesions can be a remarkable ocular manifestation of PXE and may represent degenerated photoreceptors overlying an area of RPE/Bruch membrane disruption.

To read this article in full you will need to make a payment

## **Article info**

### **Publication history**

Published online: May 06, 2021

Accepted: April 7, 2021

Received in revised form: March 10, 2021

Received: December 13, 2020

### **Identification**

DOI: <https://doi.org/10.1016/j.jcjo.2021.04.001>

### **Copyright**

© 2021 Canadian Ophthalmological Society. Published by Elsevier Inc. All rights reserved.

### **ScienceDirect**

[Access this article on ScienceDirect](#)

### **Related Articles**

