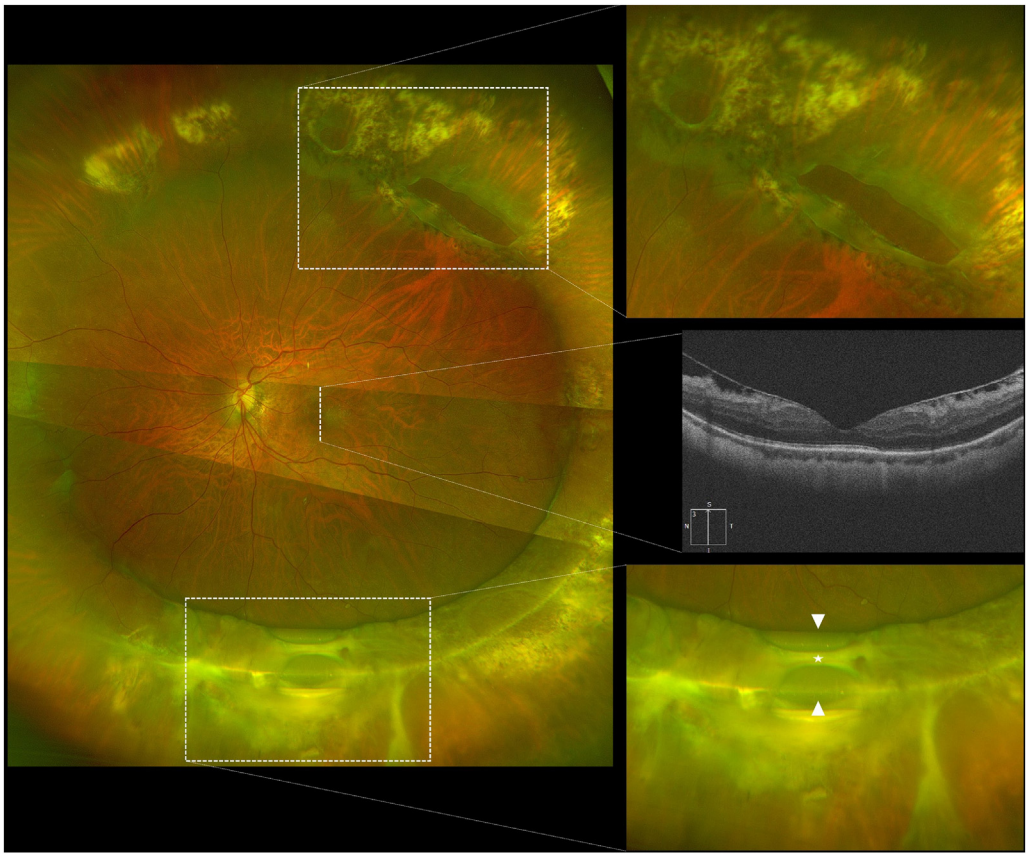

Early Scleral Buckle Intrusion in a Vitrectomized Myopic Eye

Wide-field fundus photograph of a 56-year-old patient who had undergone combined vitrectomy and episcleral buckling for a macula-off retinal detachment 6 months previously. Visual acuity was 20/30. In the upper zoomed frame, the original superotemporal retinal breaks surrounded by laser spots are visible. In the inferior area, a segment of buckle had eroded the sclera, uvea, and overlying retina (lower zoomed frame, white arrowheads), with a small bridge of residual retinal tissue (white star). OCT is visible in the central zoomed frame. Because there was no evidence of uveitis or endophthalmitis, surgical intervention was not considered at the time (Magnified version of the Figure is available online at www.ophthalmologyretina.org).

Matteo Mario Carlà, MD[1]
Carlos Mateo, MD[2]

[1]*Ophthalmology Department, Catholic University "Sacro Cuore," Fondazione Policlinico Universitario A. Gemelli, IRCCS, Rome, Italy;* [2]*Vitreoretinal Surgery Department, Instituto de Microcirugía Ocular (IMO), Barcelona, Spain*

© 2024 by the American Academy of Ophthalmology
Published by Elsevier Inc.
https://doi.org/10.1016/j.oret.2024.02.009
ISSN 2468-6530/24