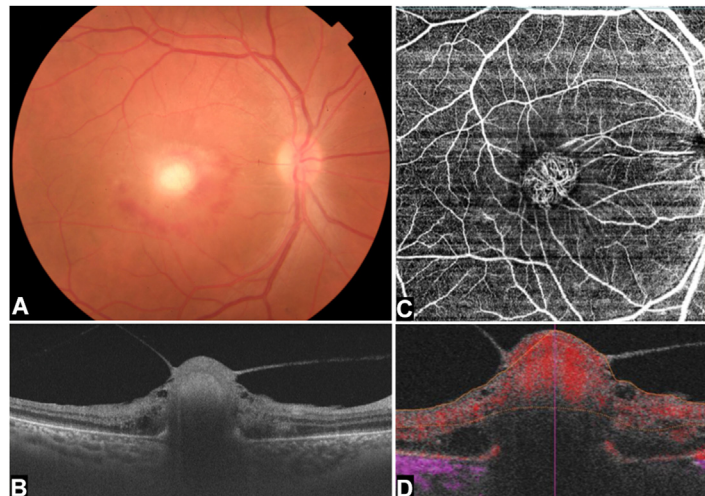


12. Sundararajan M, Jansen ME, Gupta M. Unilateral persistence of the hyaloid artery causing vitreopapillary and vitreomacular traction. *JAMA Ophthalmol.* 2018;136:e180221.
13. Gamidov AA, Durzhinskaya MH, Makashova NV, et al. Persistent hyaloid artery in an adult (a case report) [in Russian]. *Vestn Oftalmol.* 2020;136:214–218.
14. Chen X, Viehland C, Carrasco-Zevallos OM, et al. Microscope-integrated optical coherence tomography angiography in the operating room in young children with retinal vascular disease. *JAMA Ophthalmol.* 2017;135:483–486.
15. Kunkler AL, Patel NA, Russell JF, et al. Intraoperative OCT angiography in children with incontinentia pigmenti. *Ophthalmol Retina.* 2022;6:330–332.
16. Zigler Jr JS, Valapala M, Shang P, et al.  $\beta$ A3/A1-crystallin and persistent fetal vasculature (PFV) disease of the eye. *Biochim Biophys Acta.* 2016;1860:287–298.
17. Hegde S, Srivastava O. Different gene knockout/transgenic mouse models manifesting persistent fetal vasculature: are integrins to blame for this pathological condition? *Life Sci.* 2017;171:30–38.
18. Saint-Geniez M, D'Amore PA. Development and pathology of the hyaloid, choroidal and retinal vasculature. *Int J Dev Biol.* 2004;48:1045–1058.
19. Jones HE. Hyaloid remnants in the eyes of premature babies. *Br J Ophthalmol.* 1963;47:39–44.
20. Smirniotopoulos JG, Bargallo N, Mafee MF. Differential diagnosis of leukokoria: radiologic-pathologic correlation. *Radiographics.* 1994;14:1059–1079; quiz 1081.
21. Chen C, Xiao H, Ding X. Persistent fetal vasculature. *Asia Pac J Ophthalmol (Phila).* 2019;8:86–95.
22. Önder F, Coşsar CB, Gültan E, Kural G. Vitreous hemorrhage from the persistent hyaloid artery. *J AAPOS.* 2000;4:190–191.
23. Sheth JU, Sharma A, Chakraborty S. Persistent hyaloid artery with an aberrant peripheral retinal attachment: a unique presentation. *Oman J Ophthalmol.* 2013;6:58–60.
24. Falavarjani KG, Al-Sheikh M, Akil H, Sadda SR. Image artefacts in swept-source optical coherence tomography angiography. *Br J Ophthalmol.* 2017;101:564–568.

## Pictures & Perspectives



### Multimodal Imaging of Vascularized Toxoplasma Granuloma

A 30-year-old woman presented with blurring of vision in the right eye for 1 month. Fundus showed a whitish lesion at the fovea with surrounding hemorrhages (A). OCT showed thumb-shaped hyperreflectivity at the fovea, loss of retinal architecture, and shadowing beneath (B). En face OCT angiography revealed a vascular network in the central macula (C). Cross-sectional OCT angiography showed flow signal within the lesion (D). Toxoplasma immunoglobulin M and immunoglobulin G were both positive. Multimodal imaging characteristics of a vascularized retinal granuloma, which is an uncommon presentation of ocular toxoplasmosis, is depicted. (Magnified version of Figure A–D is available online at [www.ophtalmologyretina.org](http://www.ophtalmologyretina.org)).

VARSHA A, MS  
 PRADEEP SAGAR, MD  
 SUCHITRA BISWAL, MS

Department of Vitreo-retina, Sankara Eye Hospital, Shimoga, Karnataka, India